Kazan Federal (Volga Region) University
Institute of Fundamental Medicine and Biology
Department of Morphology and General Pathology

MUSCLE TISSUE AND SKELETAL MUSCLE

Zaikina Elvira Ildarovna,
MD, PhD, Senior lecturer

FUNCTIONS OF THE MUSCLES

- 1. Movement (the whole body and within the body)
- 2. Maintaining body position
- 3. Respiration
- 4. Support of soft tissues
- 5. Constriction of organs and vessels
- 6. Regulating entrance/exits
- 7. Maintaining body temperature – production of body heat

PROPERTIES OF THE MUSCLES

- Excitable or irritable (respond to the stimulus)
- Contractile
- Extensible (stretch without damage)
- Elasticity
- Adaptability

THREE KINDS OF MUSCLE TISSUE

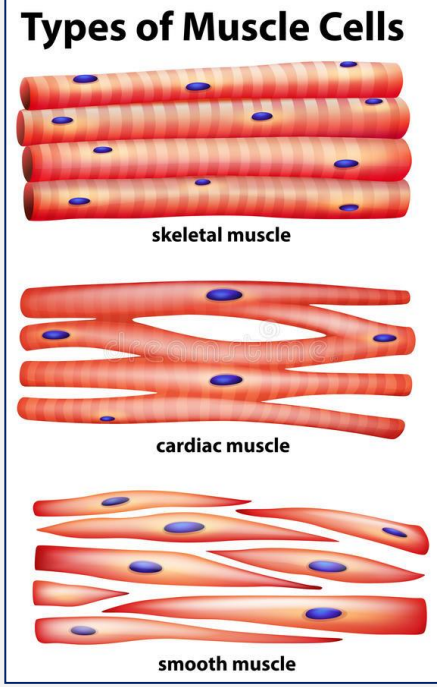

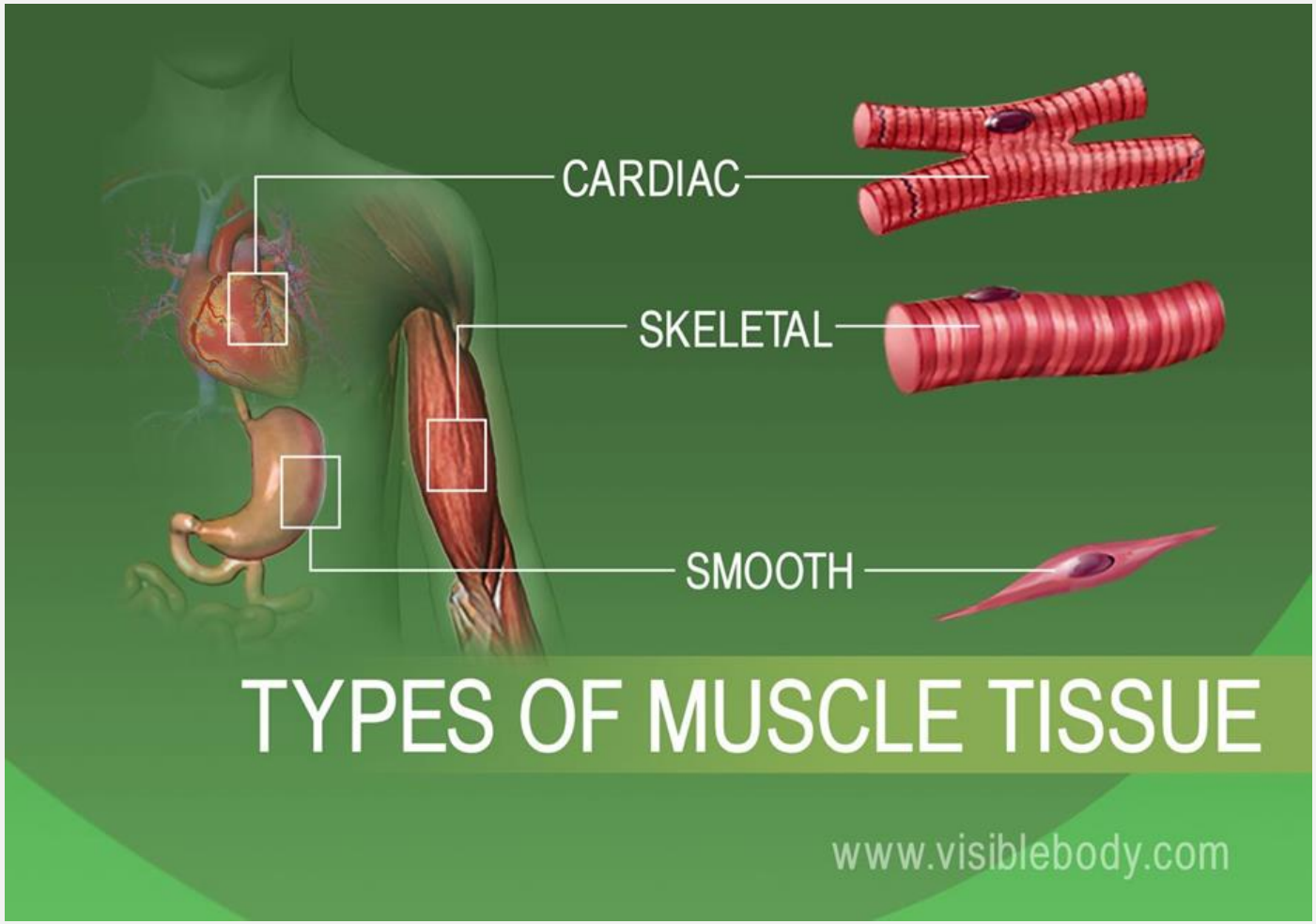

MUSCLE IS CONTRACTILE - STIMULATION >> SHORTENS

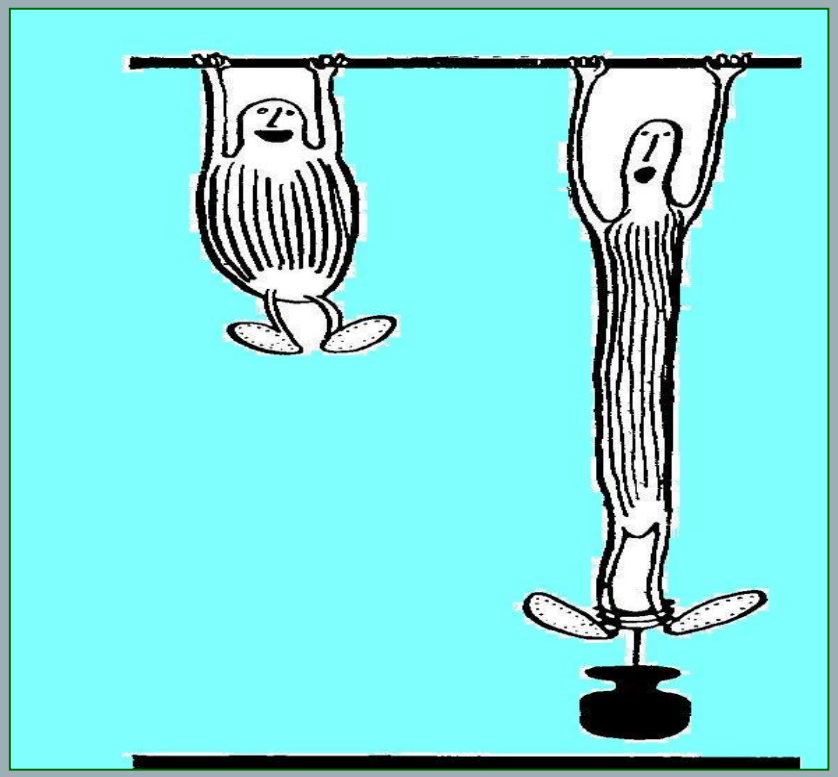

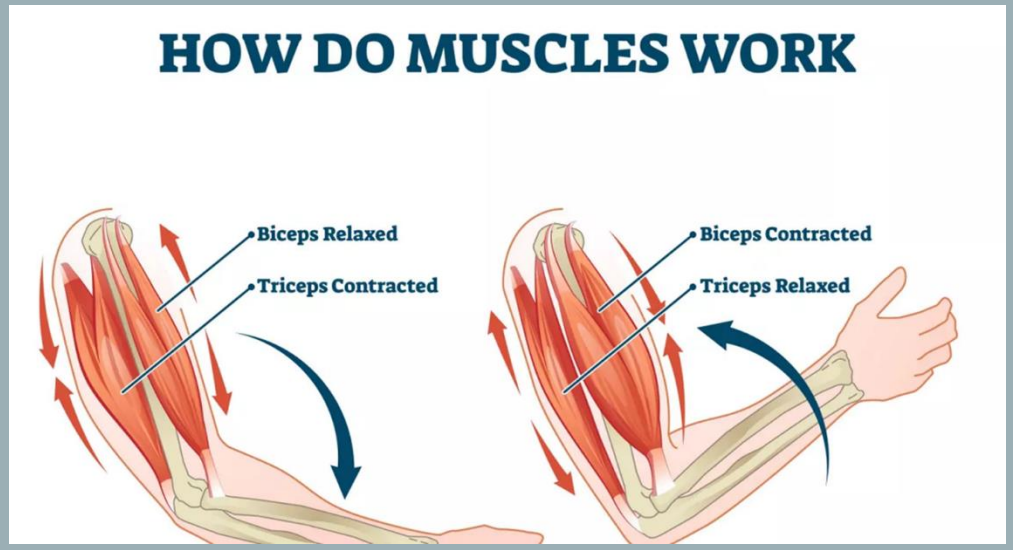

SKELETAL MUSCLE

- Attached to the skeletal system
- Striated
- Stimulated by Somatic Nervous System
- Voluntary

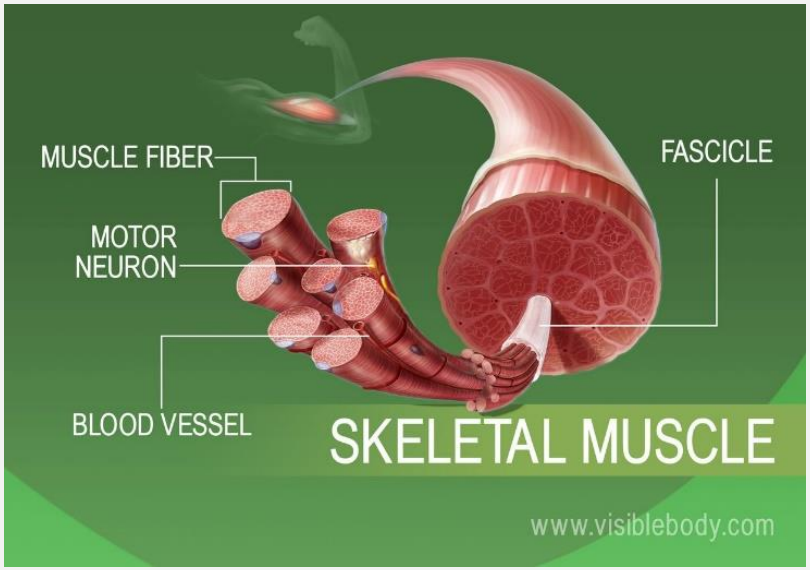

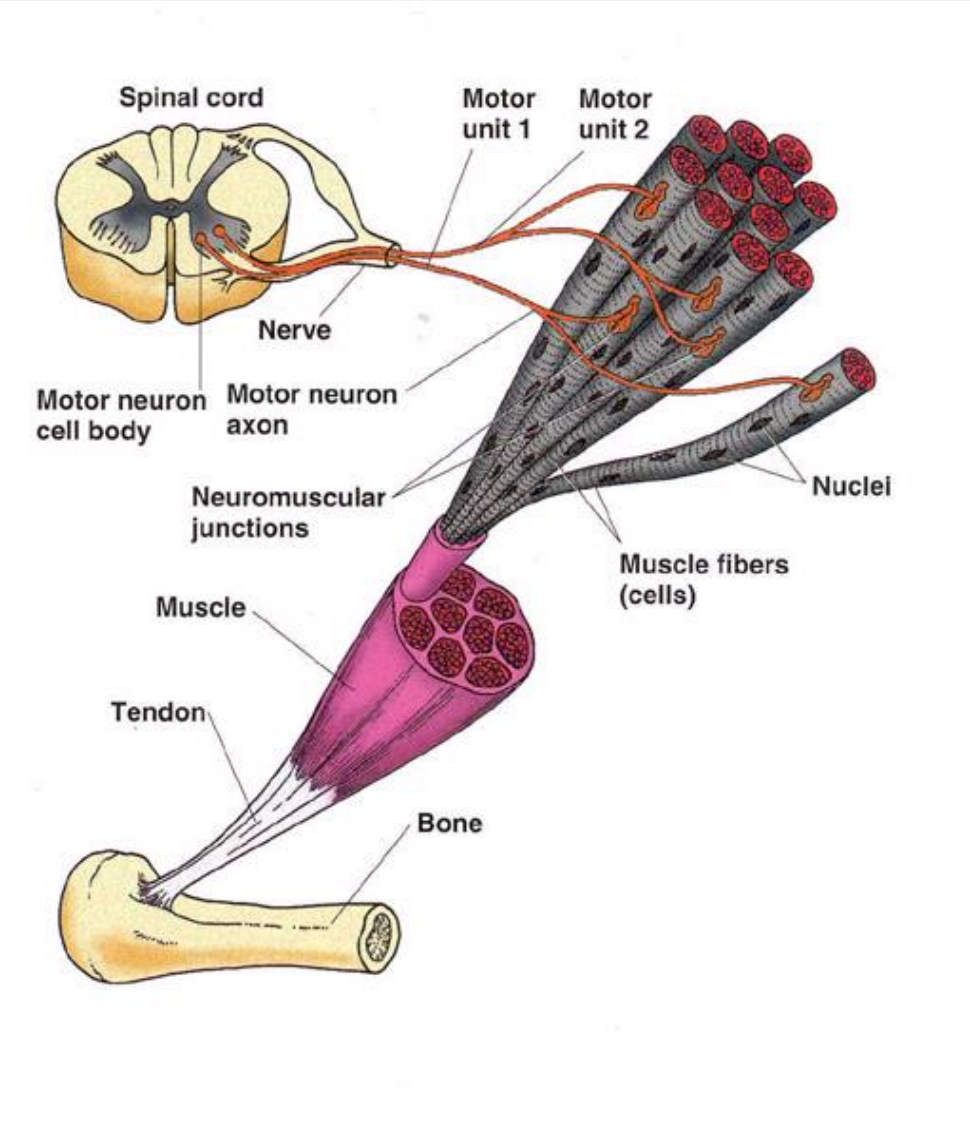

SKELETAL MUSCLE

Approximately

35% of the body is muscle mass in females,

45% in males,

20% in newborns,

60% in bodybuilders,

30-35% in geriatric patients.

CARDIAC (HEART) MUSCLE

- Striated
- spontaneous - autonomous (self stimulating): pace maker cells
- modulated by autonomous nervous system
- modulated by hormones

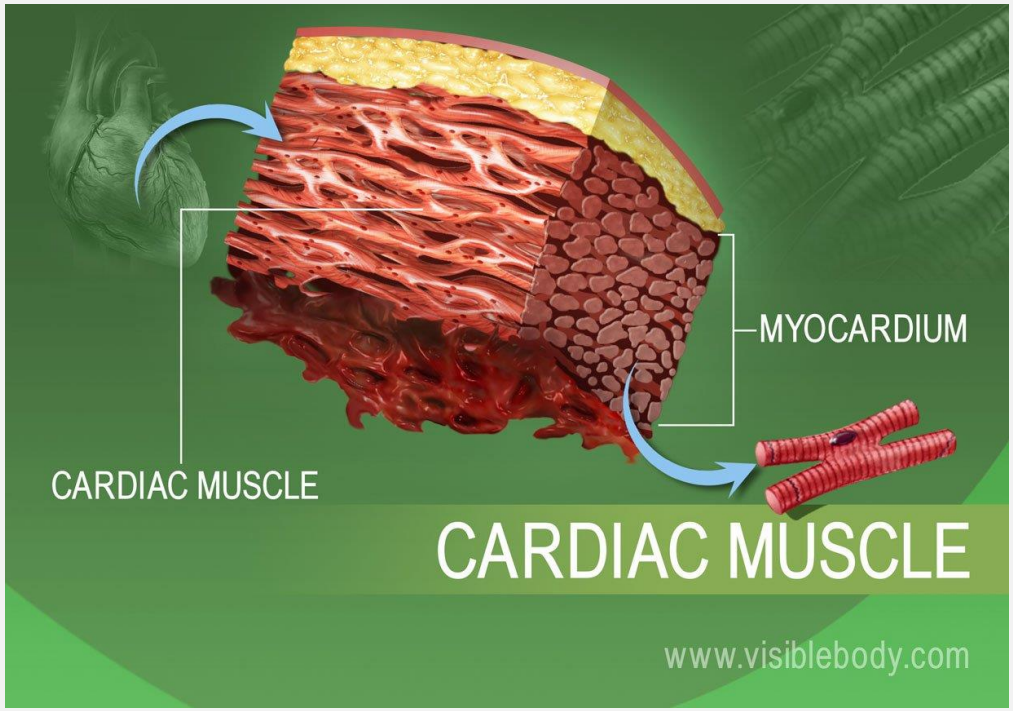

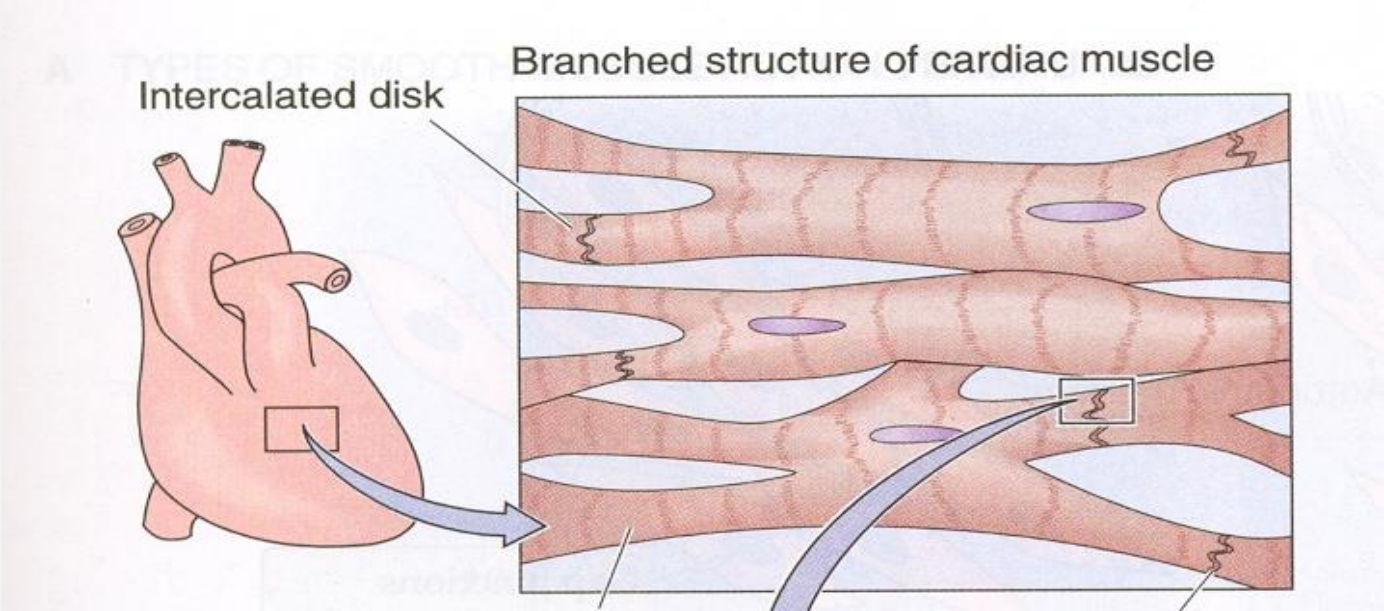

SMOOTH MUSCLE

- not visibly striated
- intestine, blood vessels
- no pace maker, but cells are electrically coupled
- modulated by autonomous nervous system
- modulated by hormones

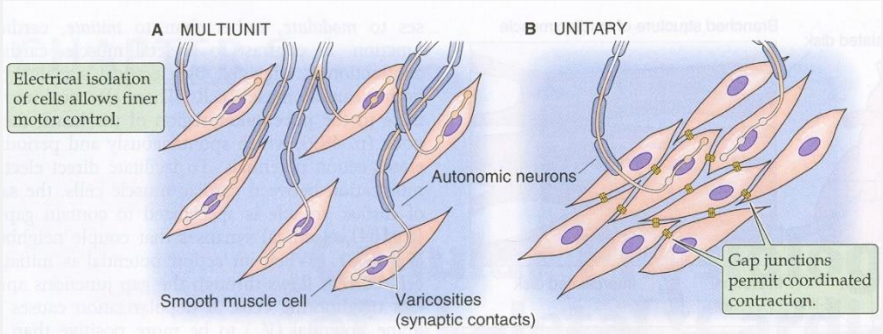

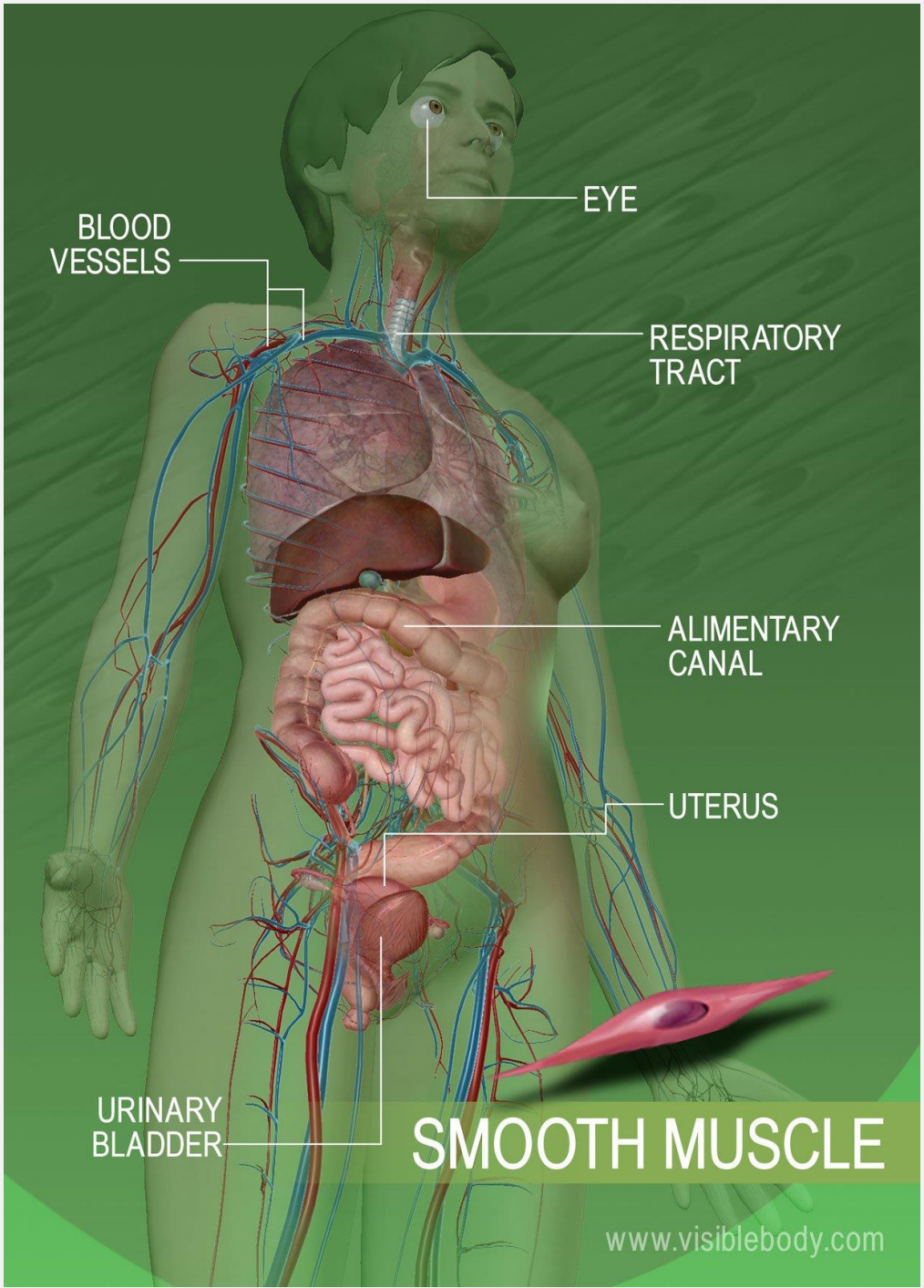

ANATOMY OF SKELETAL MUSCLE

Muscles are composed of bundles of muscle cells (muscle fibers, **myofibrils**), which are contractile

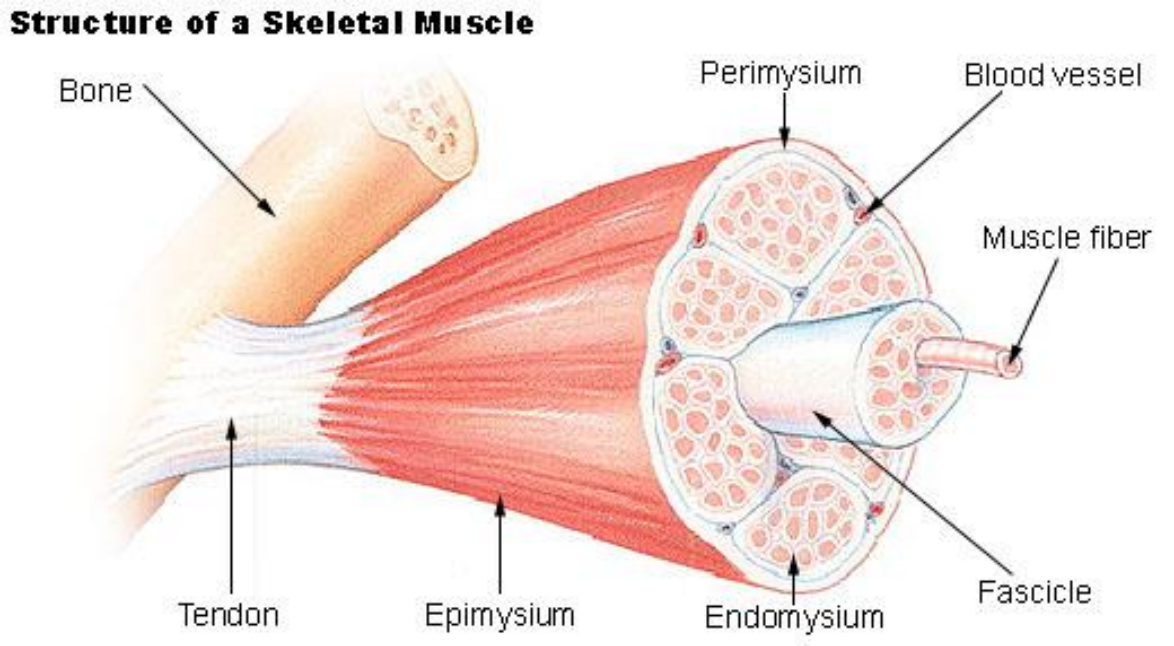

- Skeletal muscle is a composite tissue.
- It contains not just muscle cells, but also connective tissue, vascular tissue, and neural tissue, all of which participate in the function of muscle. Thus any description of "muscle" must include these tissues as well.

MUSCLE FIBERS

- The cells, called muscle "fibers", are cylindrical, and quite long, frequently spanning the length of the muscle (cm), and ranging from 10-100 μ in diameter.
- The elongated cells are embedded in a connective tissue (CT) framework, which ultimately invests each cell.

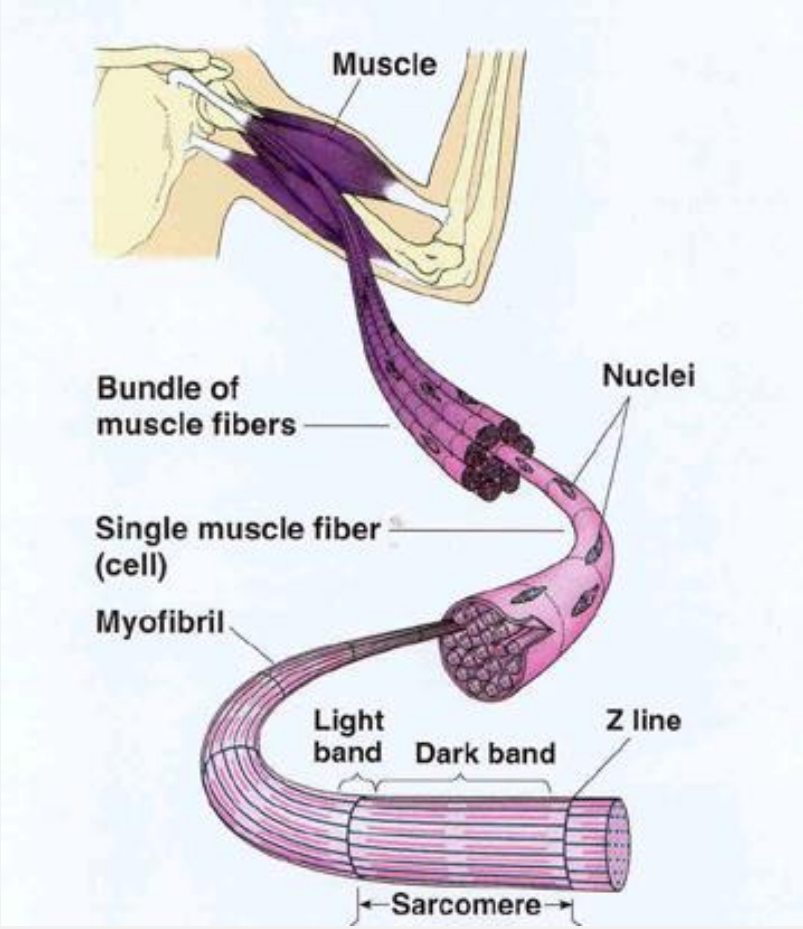

ANATOMY OF MYOFIBRIL

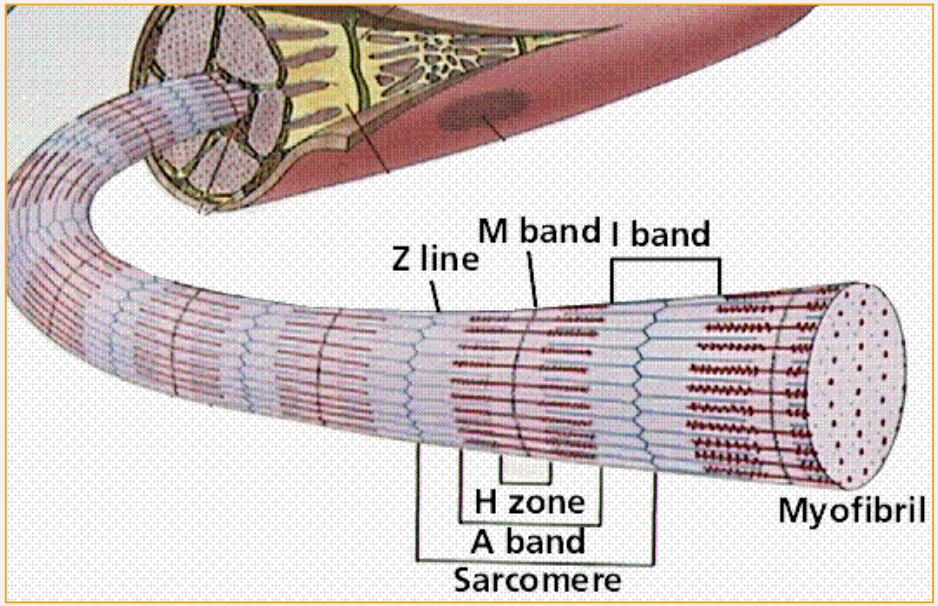

The striations are caused by alignment of bands: the most prominent are the ***A*** (dark) and ***I*** (light) bands and the ***Z*** line

AEROBIC VS. ANAEROBIC ACTIVITY

- **Aerobic respiration:**
- requires O2 (constant blood supply)
- breaks down glucose to produce ATP (38 molecules), CO2 , and H2O.
- can also process lipids or amino acids to make ATP (reduce body fat)
- increase capillary density, respiratory muscles endurance

Examples: running, biking, swimming, walking

- **Anaerobic respiration:**
- does not require O2
- breaks down glucose to produce ATP (2 molecules), ethanol and lactate.
- muscle growth and strength
- connective tissue strength

Examples: sprinting, lifting weights

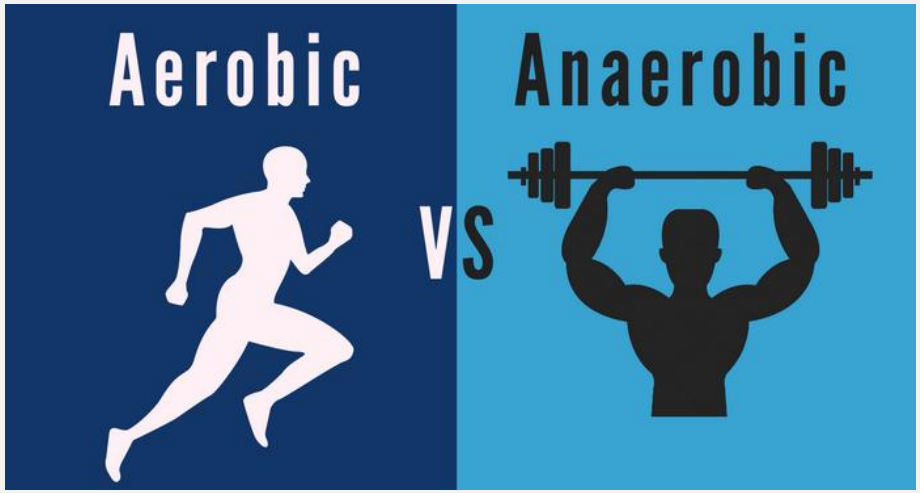

Types of muscle fibers

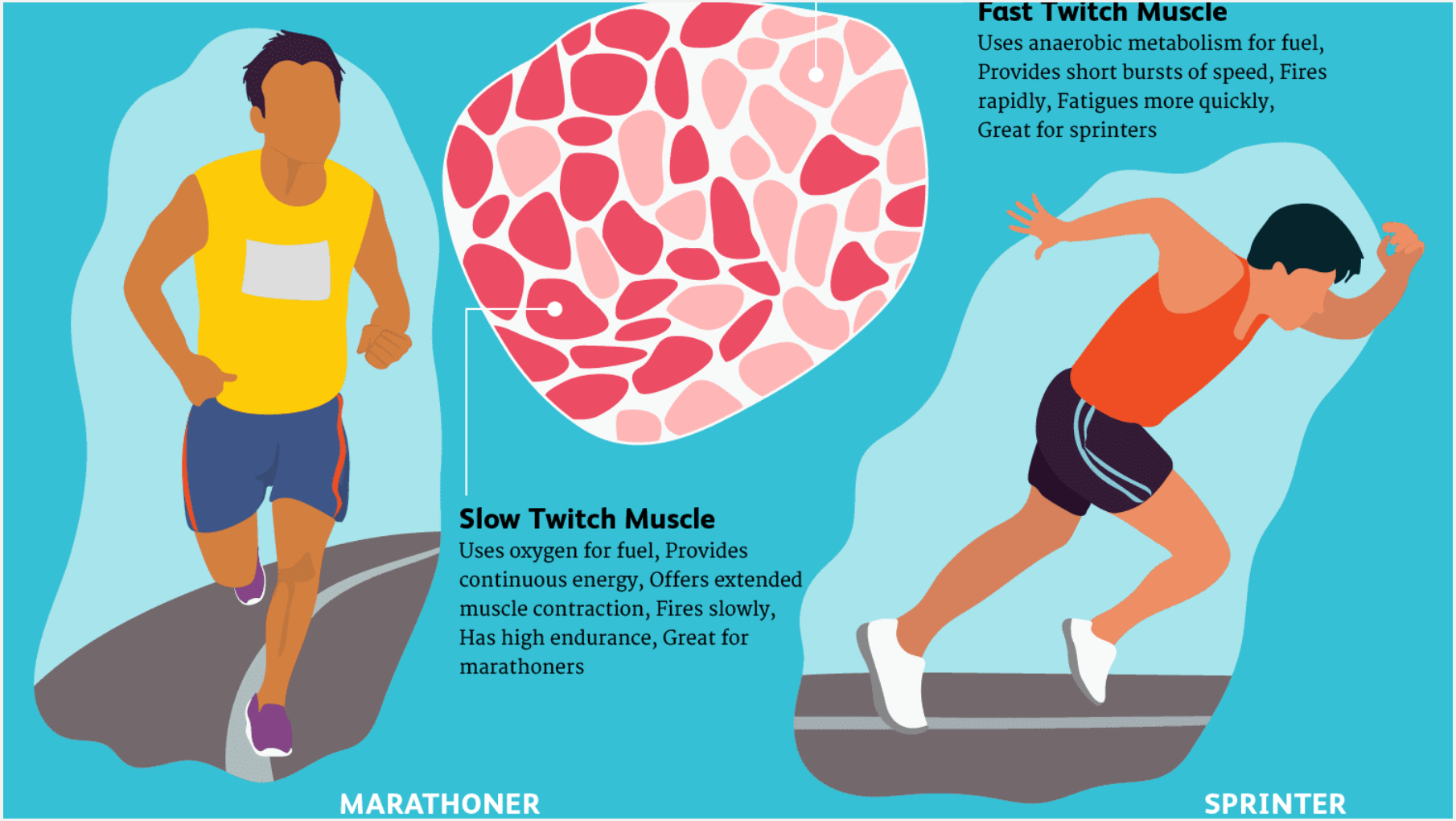

Anatomy of skeletal muscle

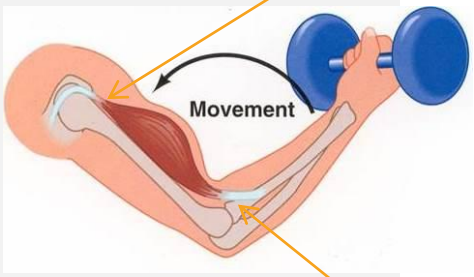

Parts of a Skeletal Muscle

- Origin *punctum fixum*
  - attachment to stationary end of muscle

Belly
  - thicker, middle region of muscle

- Insertion *punctum mobile*
  - attachment to mobile end of muscle

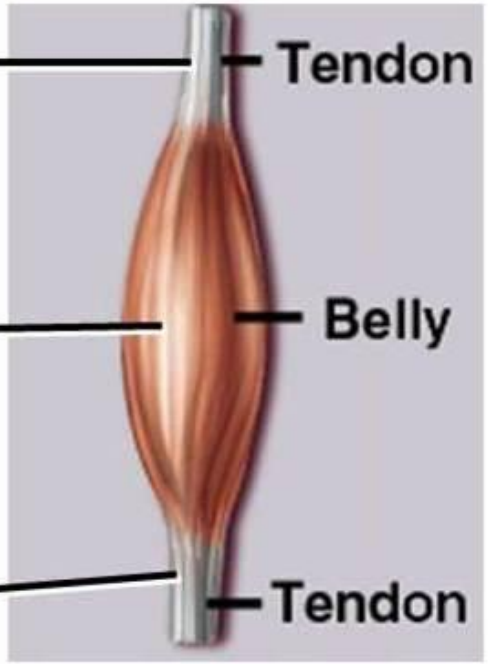

SKELETAL MUSCLE RUNS BETWEEN TWO **POINTS OF ATTACHMENT**

- The more proximal attachment site of a muscle is often referred to as the ***origin*****;** the more distal attachment site of a muscle, the ***insertion*****.**

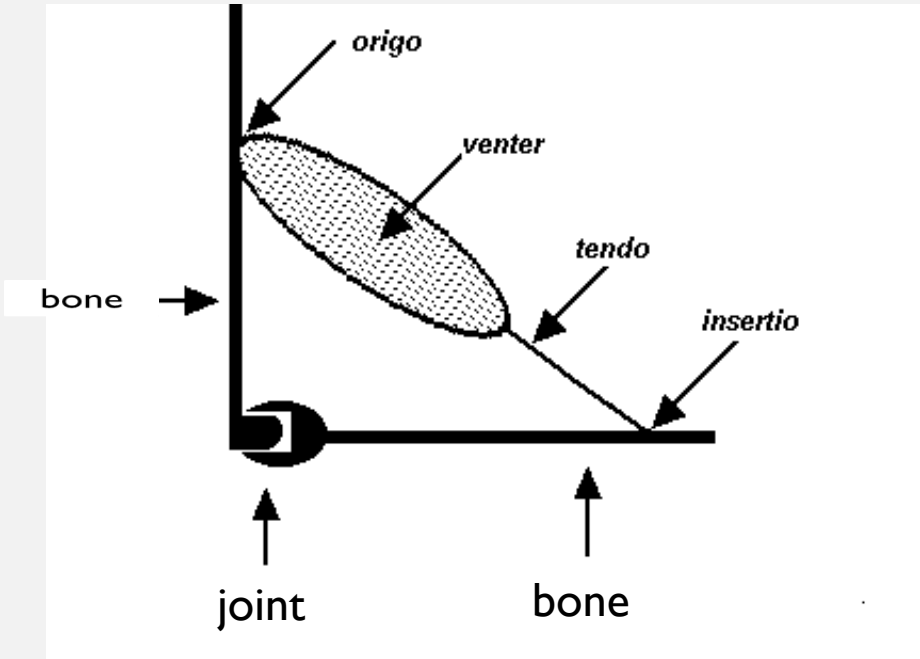

- A single skeletal muscle, such as the **triceps** muscle, is attached at its **origin** to a large area of bone; in this case, the **humerus**

- At its other end, the **insertion**, it tapers into a glistening white **tendon** which, in this case, is attached to the **ulna**, one of the bones of the lower arm.

- As the triceps contracts, the insertion is pulled toward the origin and the arm is straightened or extended at the elbow.

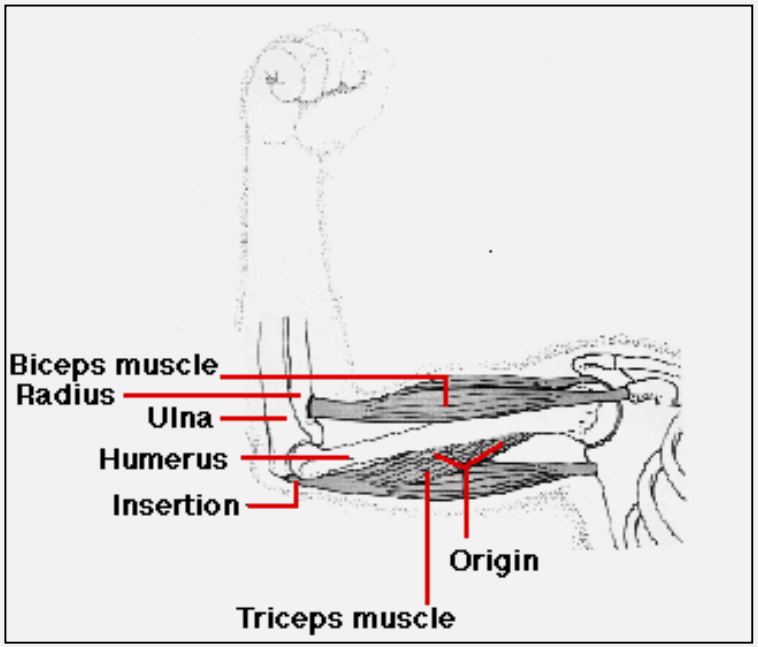

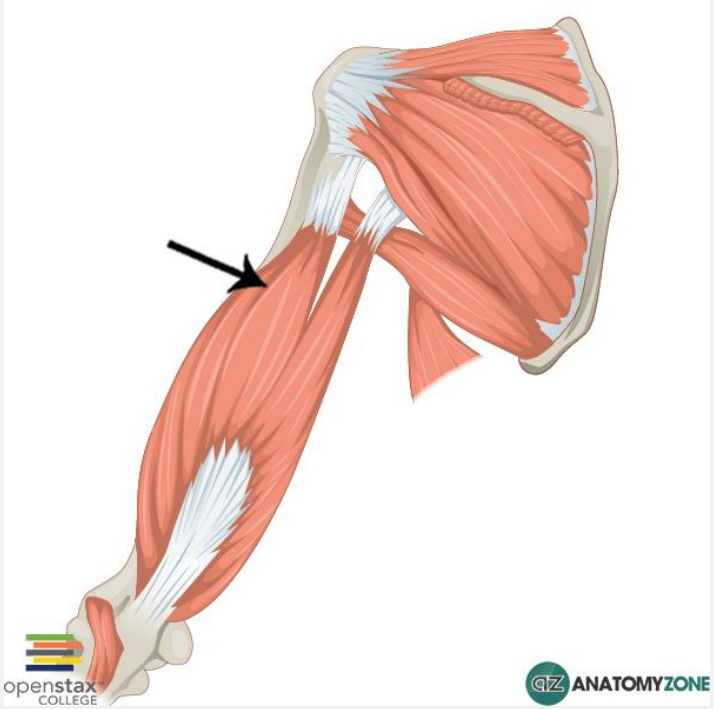

THE LINE OF ACTION

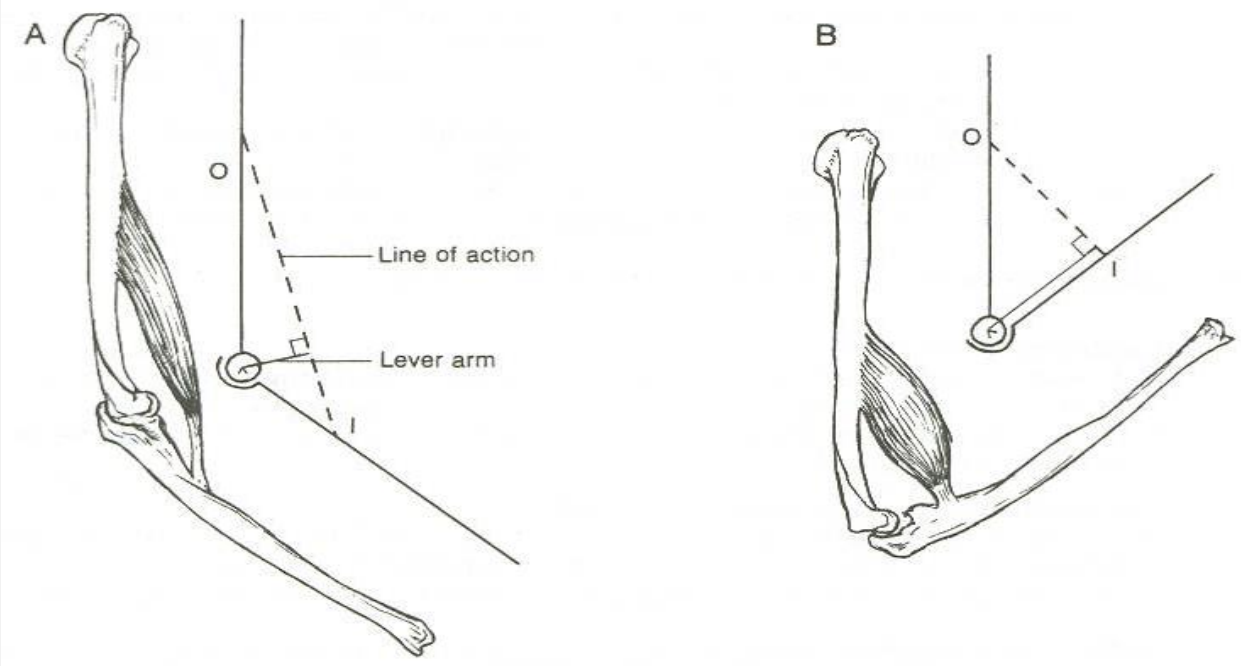

- ***The line of action*** of the muscle is the line that best describes the mean direction of the muscle between the centers of any two such attachments.

MUSCLE ACTION

Movement.

- By shortening, muscles act on the bony levers to produce motion in one or both of the bones to which they attach.

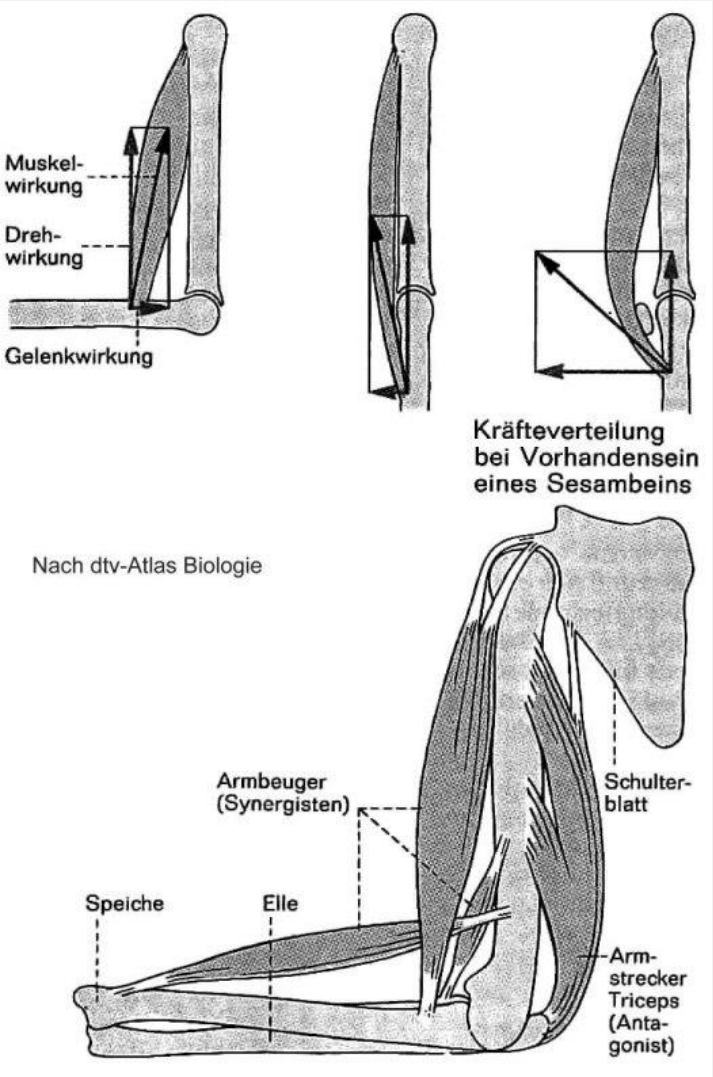

Types of muscle contraction:

1) **Isometric** (static, postural musculature)

2) **Concentric** (converging of origin and insertion points)

3) **Eccentric** (origin and insertions points move away from each other, *used in muscle reabilitation*)

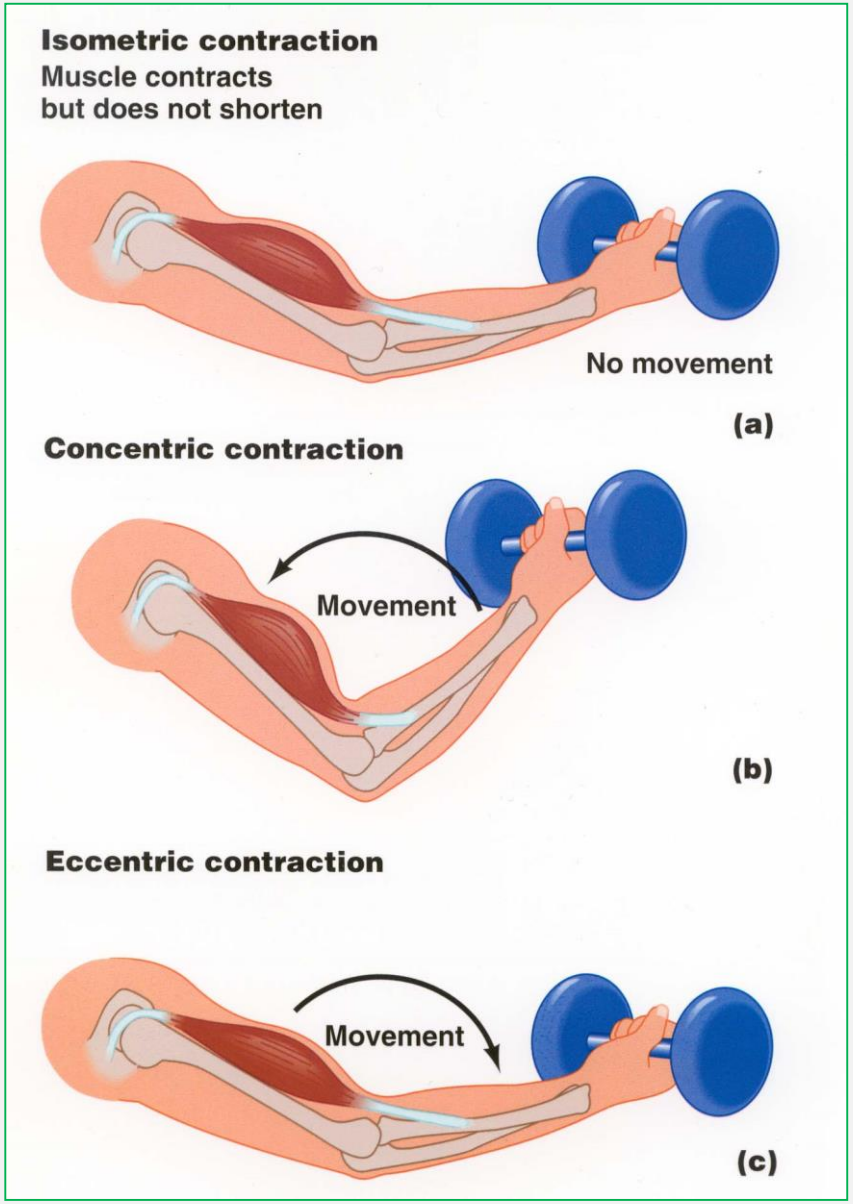

M.masseter

- *Punctum fixum (origin)*
- *Punctum mobile (inserion)*

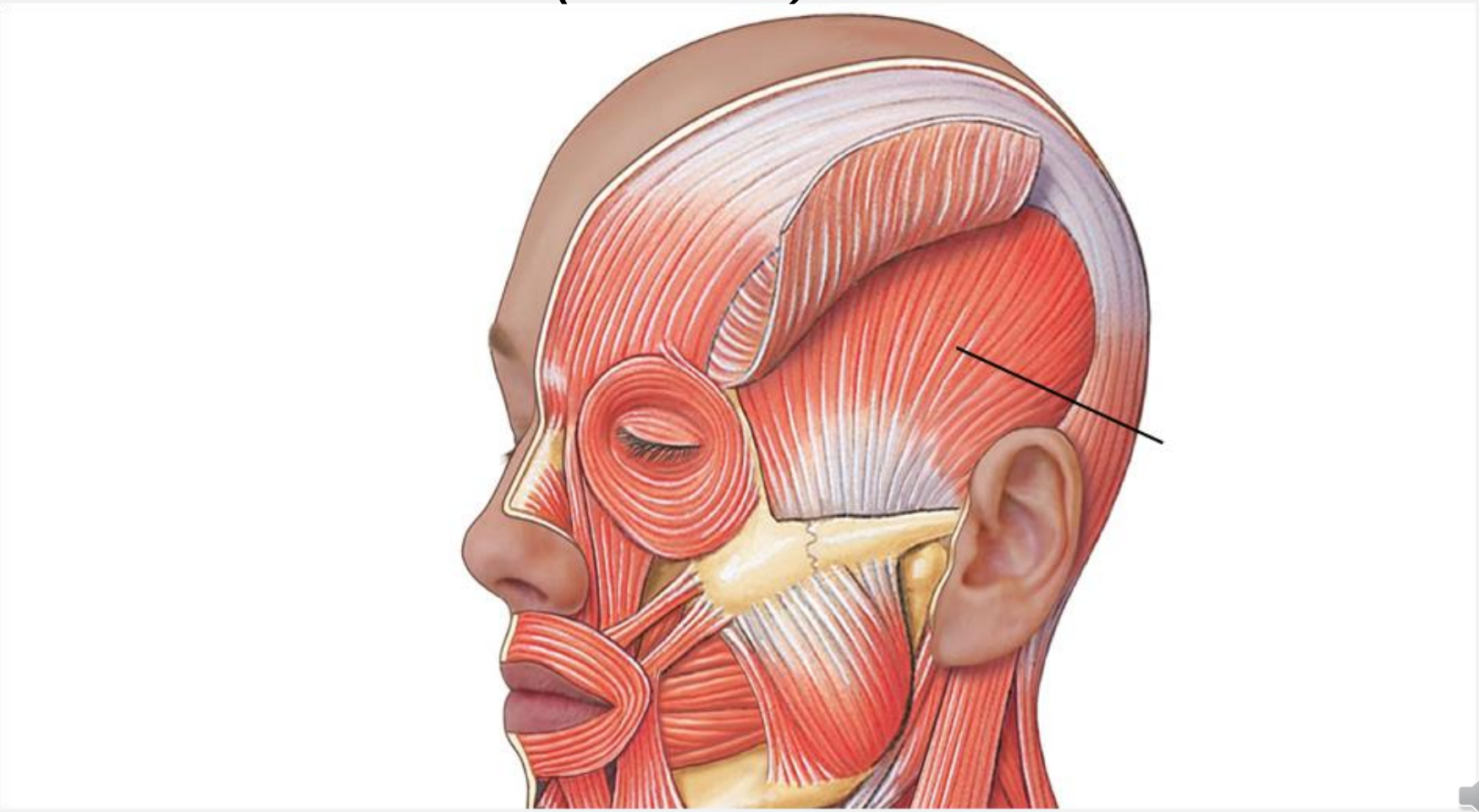

M.latissimus dorsi

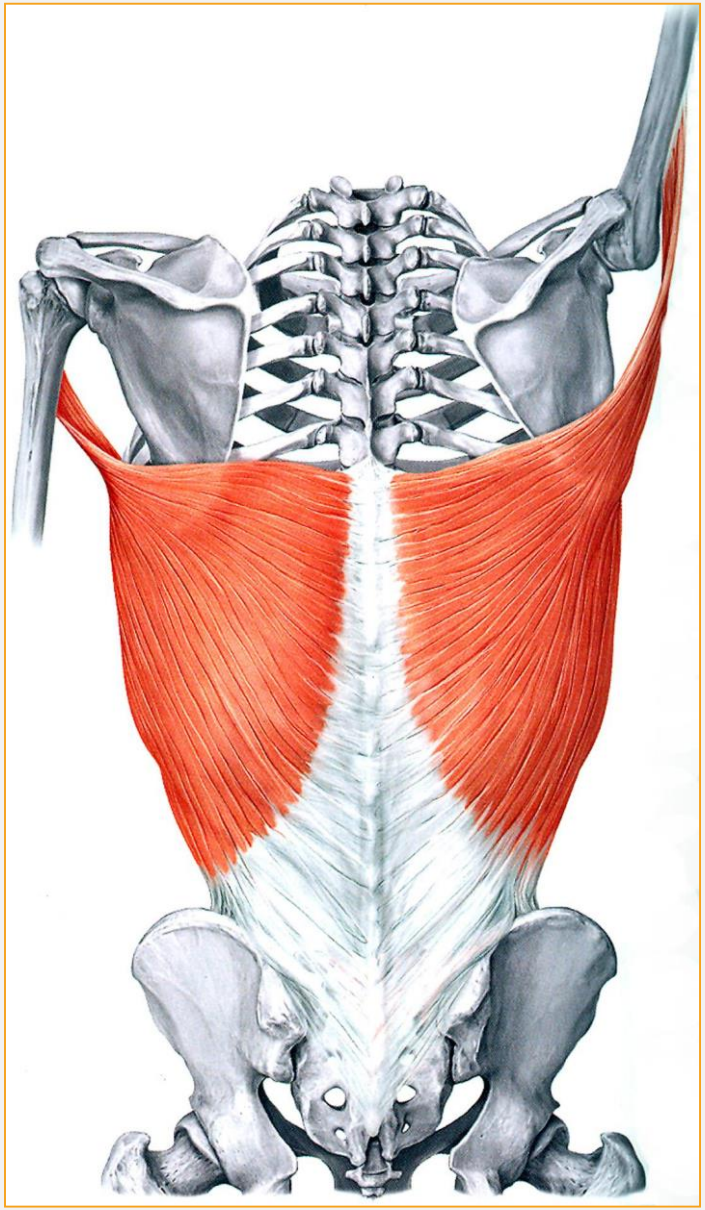

M. pectoralis major

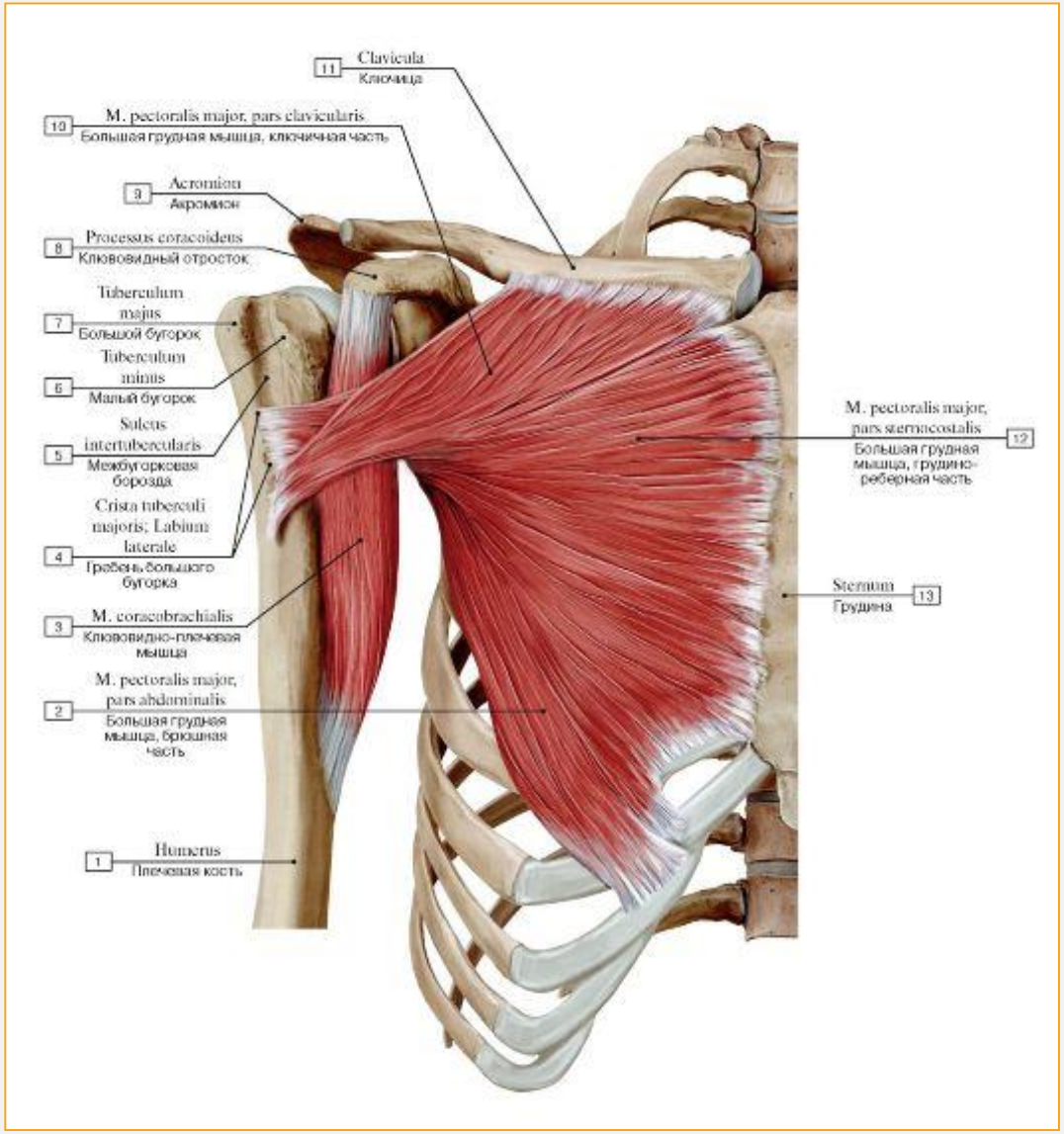

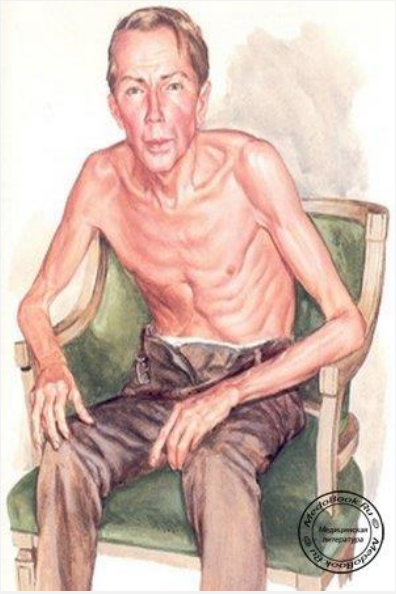



Rotator cuff of the shoulder joint

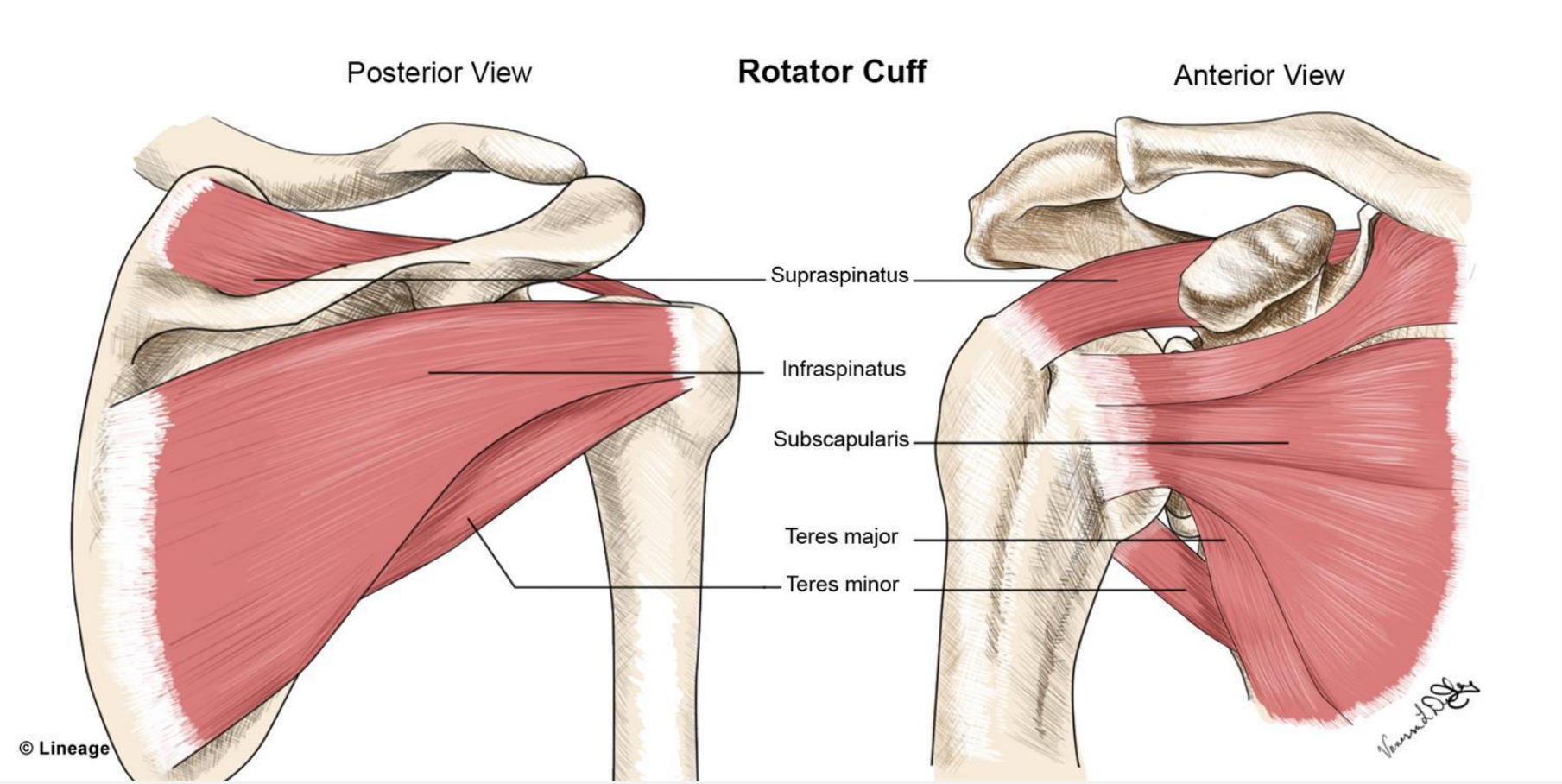

Rotator cuff of the hip joint

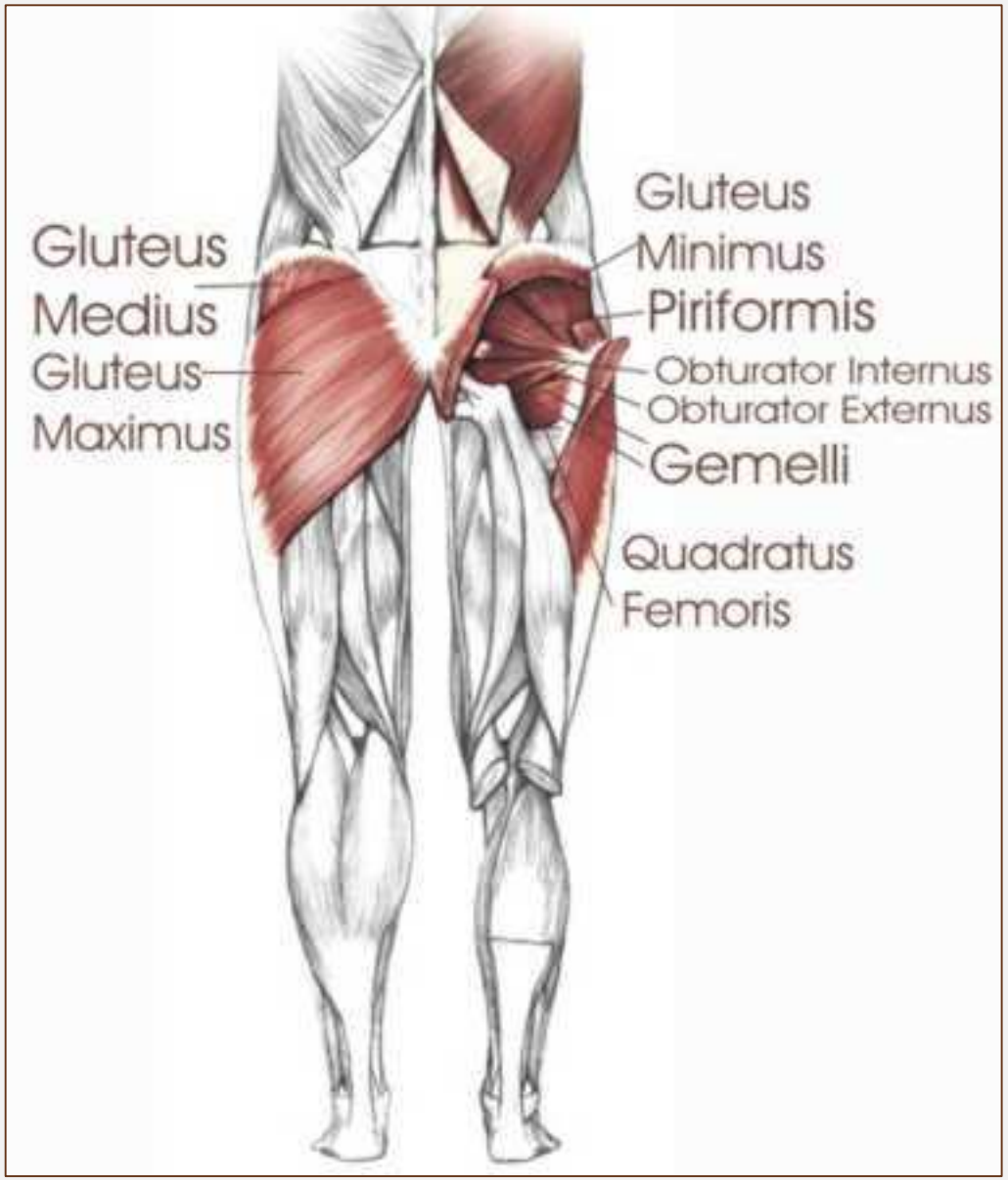

CLASSIFICATION OF MUSCLES

- There is NO unified classification of muscles.
- Muscles can be grouped, classified on the basis of several criteria.

Skeletal muscles classification – <u>regions</u>

- ✓ Head
- ✓ Neck
- ✓ Trunk (thorax, abdomen, back)
- ✓ Upper limbs
- ✓ Lower limbs

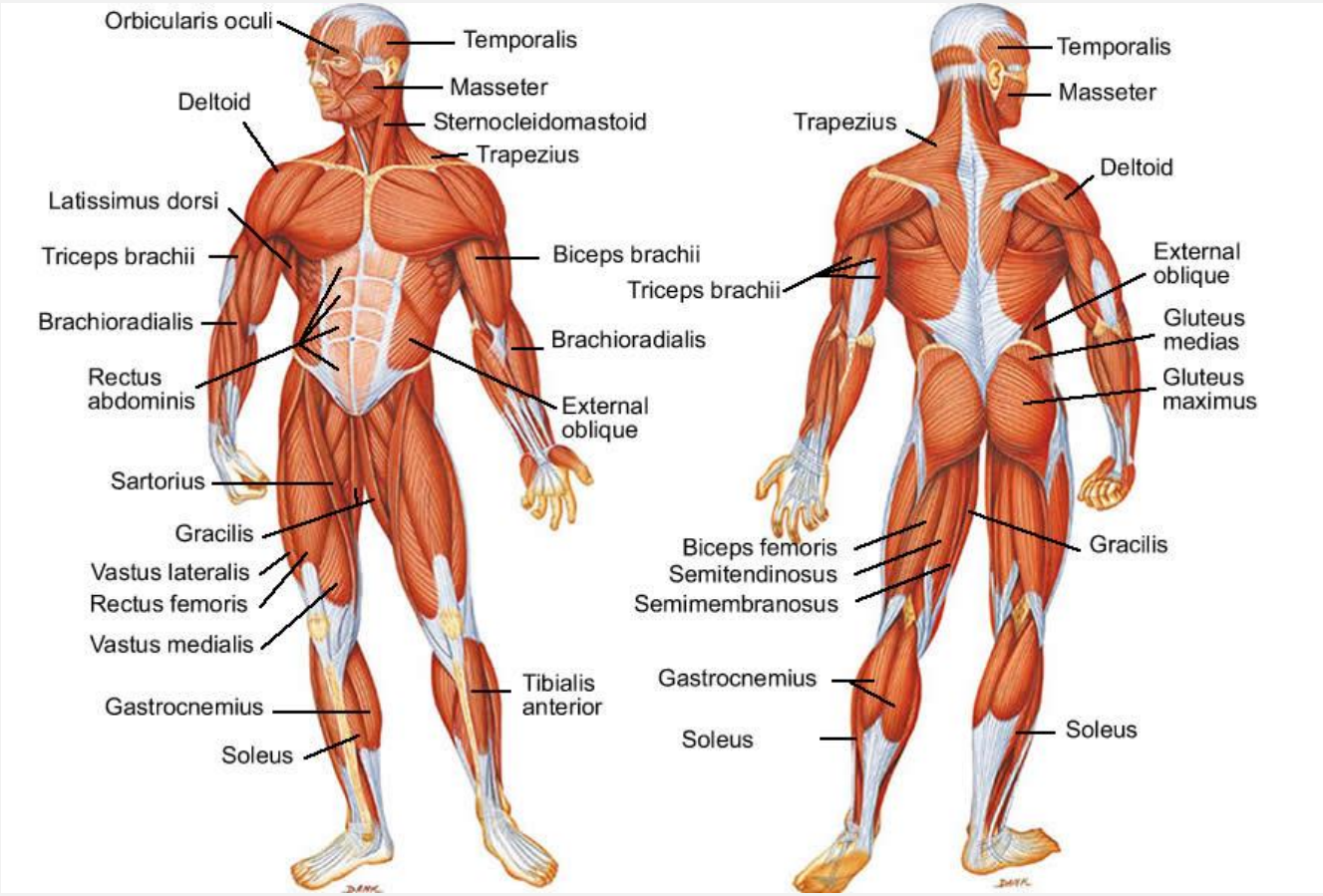

Skeletal muscles classification – localization

- Superficial / Deep
- External / Internal
- Medial / Lateral
- Superior / Inferior

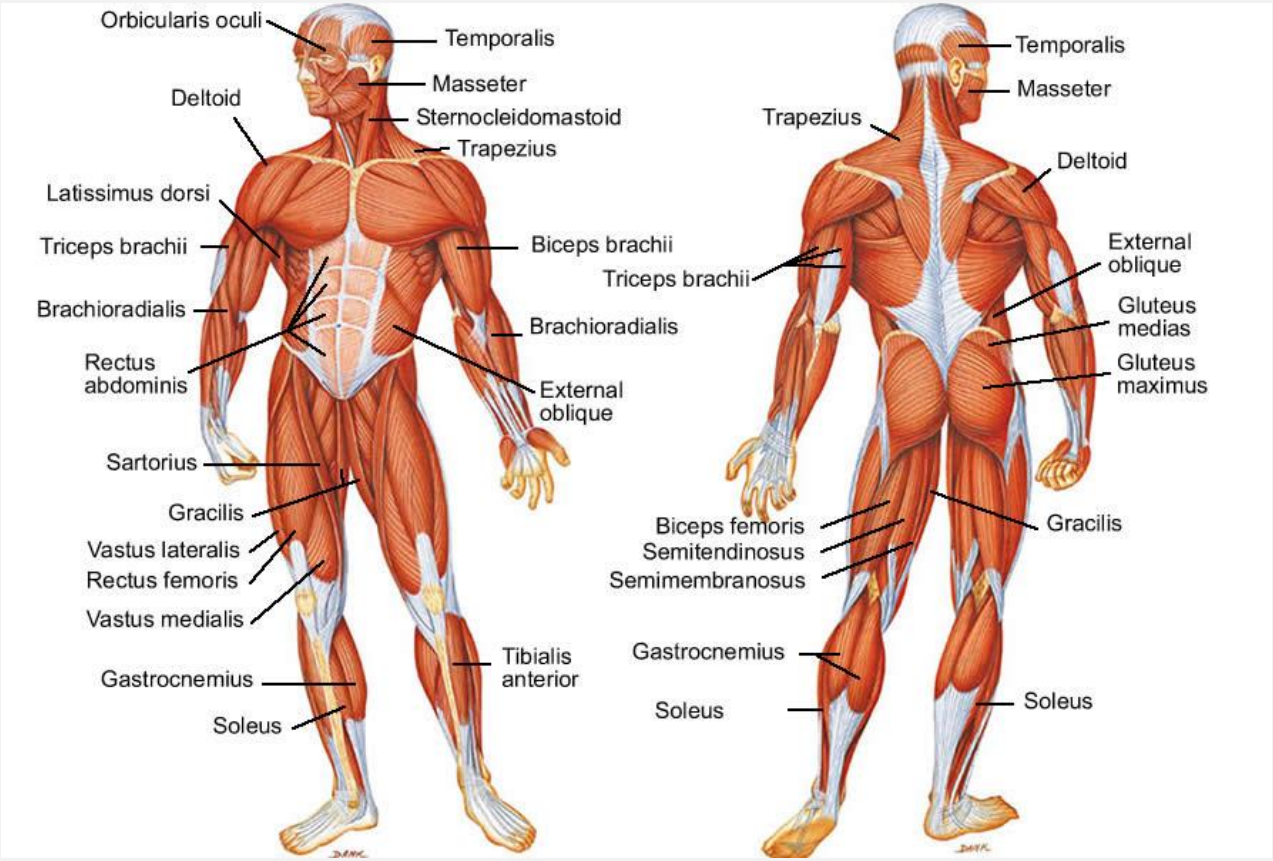

Skeletal muscles classification – <u>function</u>

- *Flexors / Extensors*
- *Abductor / Adductor*
- *Rotators – Supinator / Pronator*
- *Sphincters – Constrictor / Dilatator*

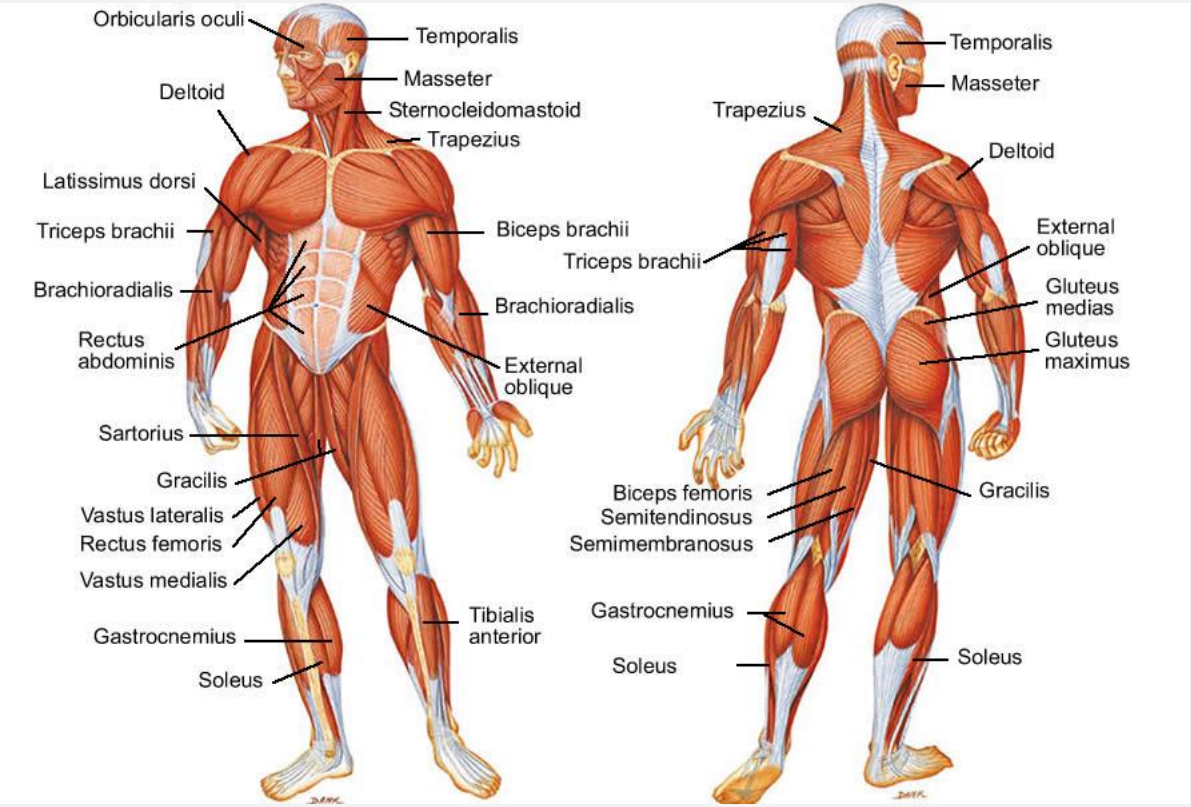

Skeletal muscles classification – <u>function</u>

- *Synergists*
- *Antagonists*
- *Agonists*

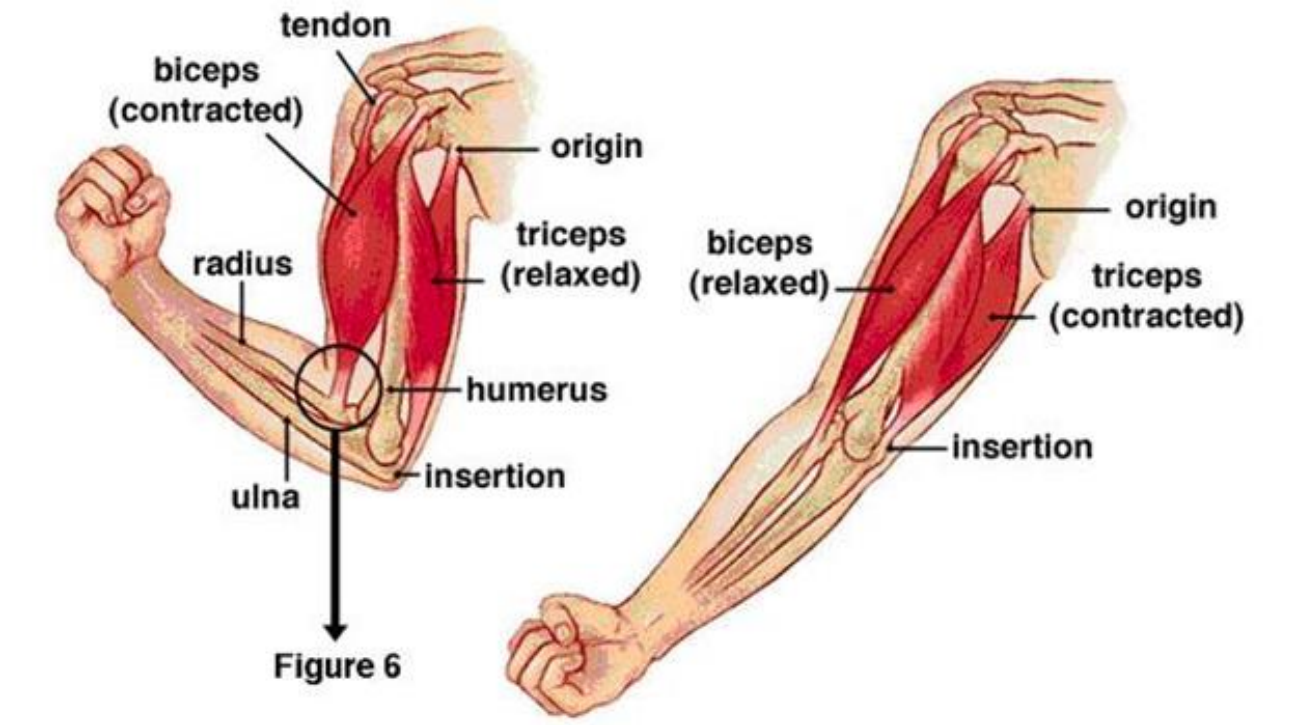

Simultaneous contraction of both synergists and antagonists produces maximal joint stability with little or no movement.

Skeletal muscles classification – development

- Myotomes of visceral arches (head)

- Myotomes of the trunk
  - dorsal
  - ventral

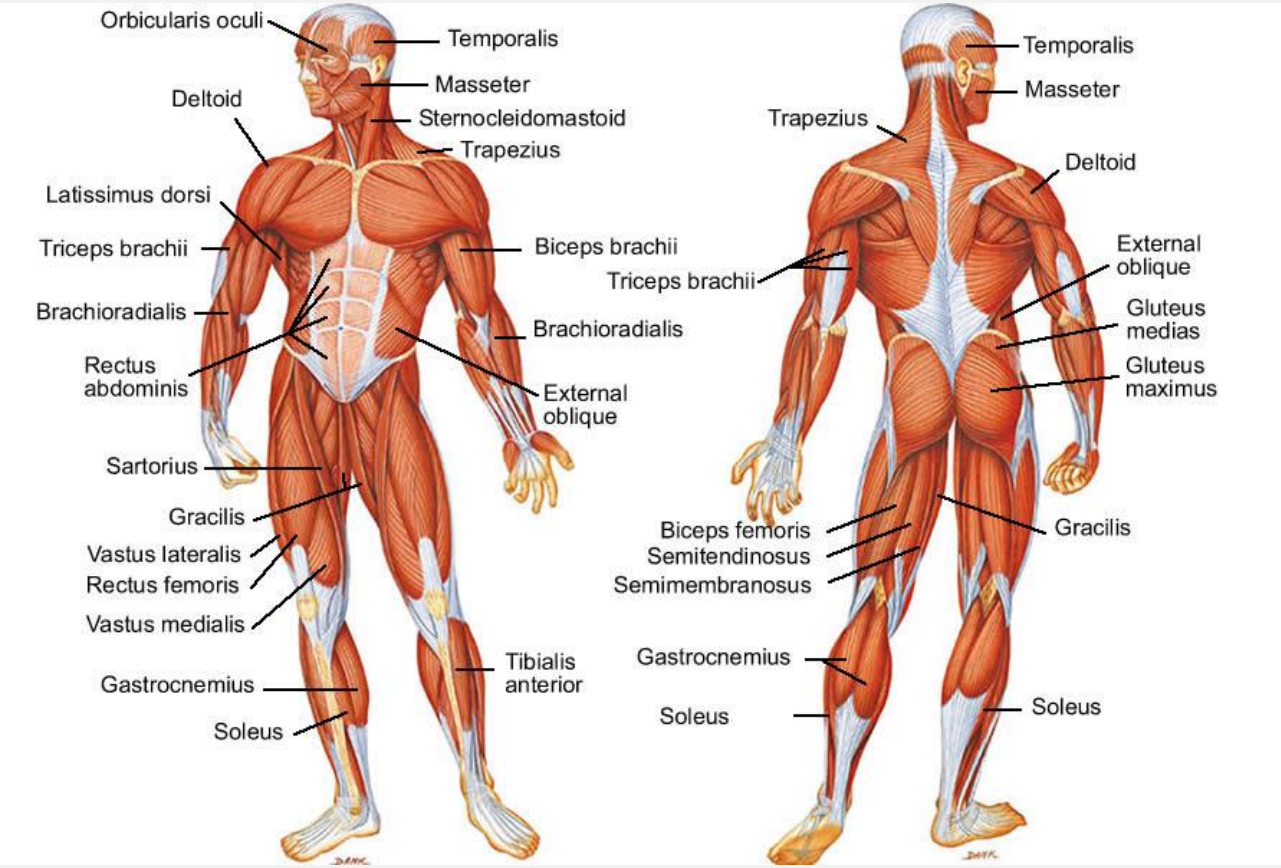

Skeletal muscles classification – <u>development</u>

- Autochtone (aborigines)

- Trunkofugal (body ⟶ extremities)

- Trunkopetal (extremities ⟶ body)

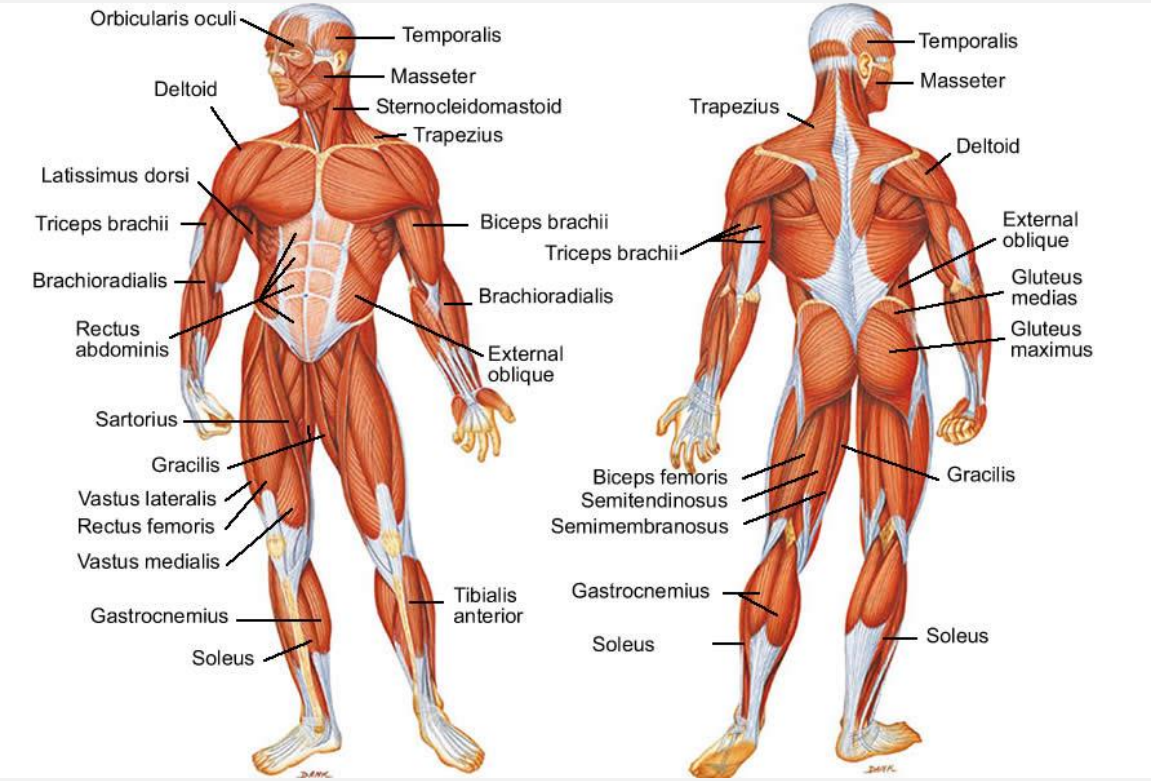

Skeletal muscles classification – <u>Arrangement of fascicles</u>

(groups of muscle fibers) within the muscle falls into several patterns

- **Fusiform.** Fascicles of muscle fibers lie parallel to the line of action along the long axis of the muscle (e.g., the sartorius muscle).
- **Pennate.** Fascicles lie at an angle to the long axis of the muscle.

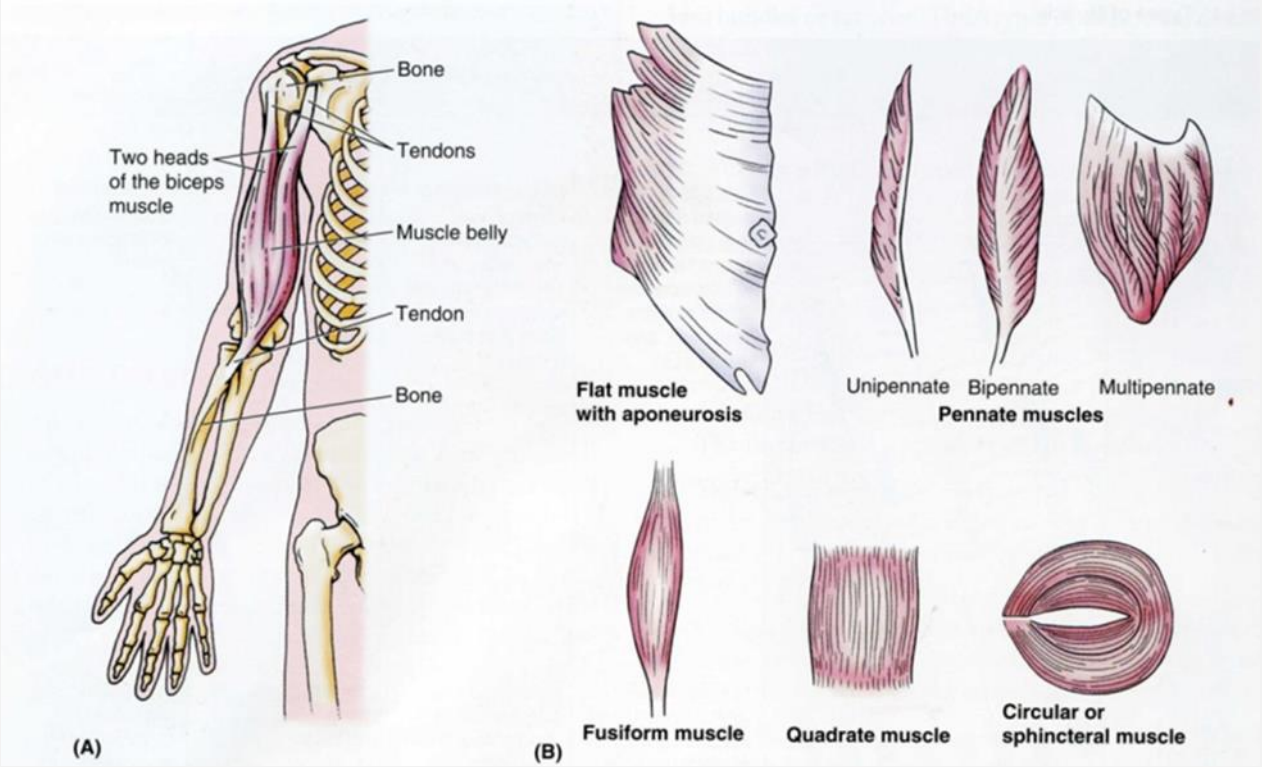

Skeletal muscles classification – shape - pennate

- **Pennate.** Fascicles lie at an angle to the long axis of the muscle. Vectorial analysis demonstrates that the same amount of contraction produces slower movement but more force in a pennate muscle than in a fusiform muscle.

(a) Unipennate. Fascicles lie at the same angle on one side of the tendon (e.g., the flexor pollicis longus muscle).
(b) Bipennate. Fascicles lie at on angle on either side of a tendinous septum (e.g., the soleus muscle).
(c) Multipennate. Fascicles reach the tendinous septa from many directions (e.g., the deltoid muscle).

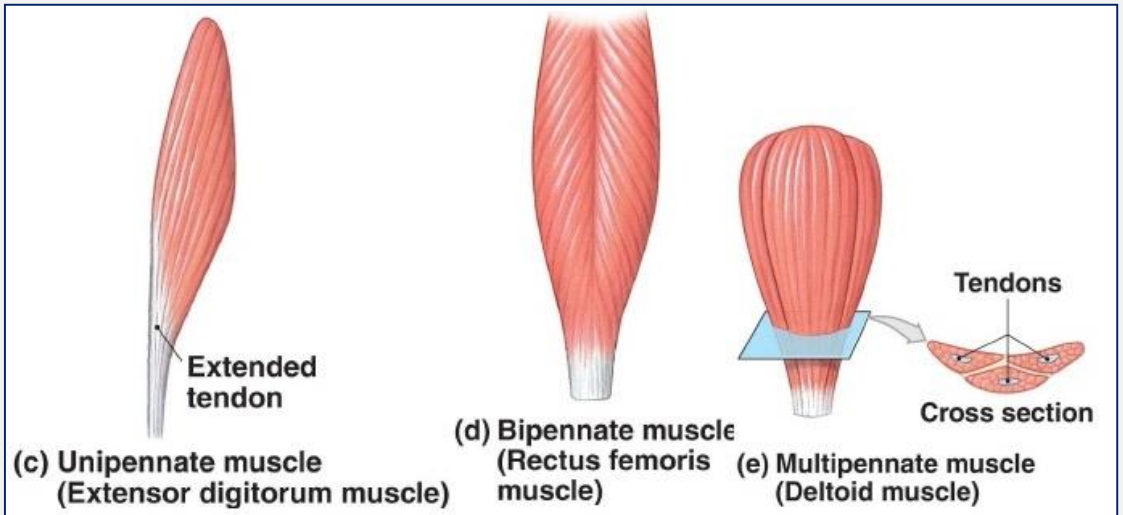

Figure 11–1c, d, e Muscle Types Based on Pattern of Fascicle Organization.

Skeletal muscles classification – <u>shape</u>

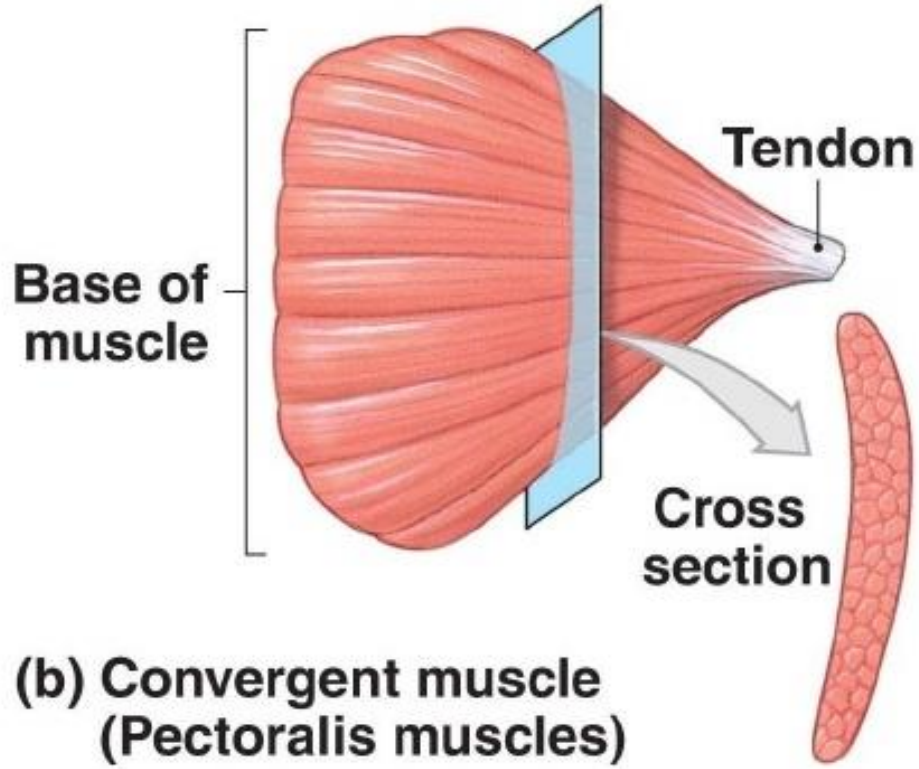

Figure 11–1b Muscle Types Based on Pattern of Fascicle Organization.

CONNECTIVE TISSUE:

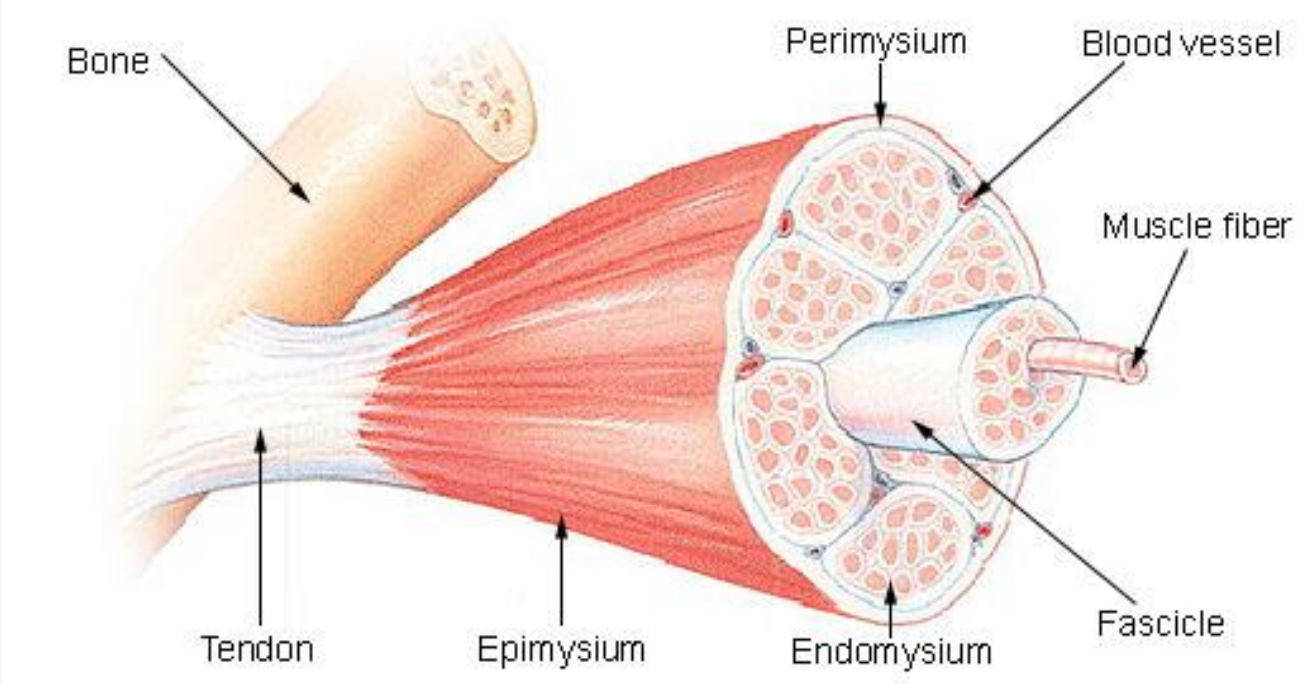

- This occurs at three levels of organization: but is essentially comprised of the same thing at each level: collagen fibers, fibroblasts, neurovascular bundles, etc

ALL THREE LEVELS MERGE AT THE MUSCLE ENDS AND ARE CONTINUOUS WITH THE MUSCLE TENDON OR APONEUROSIS.

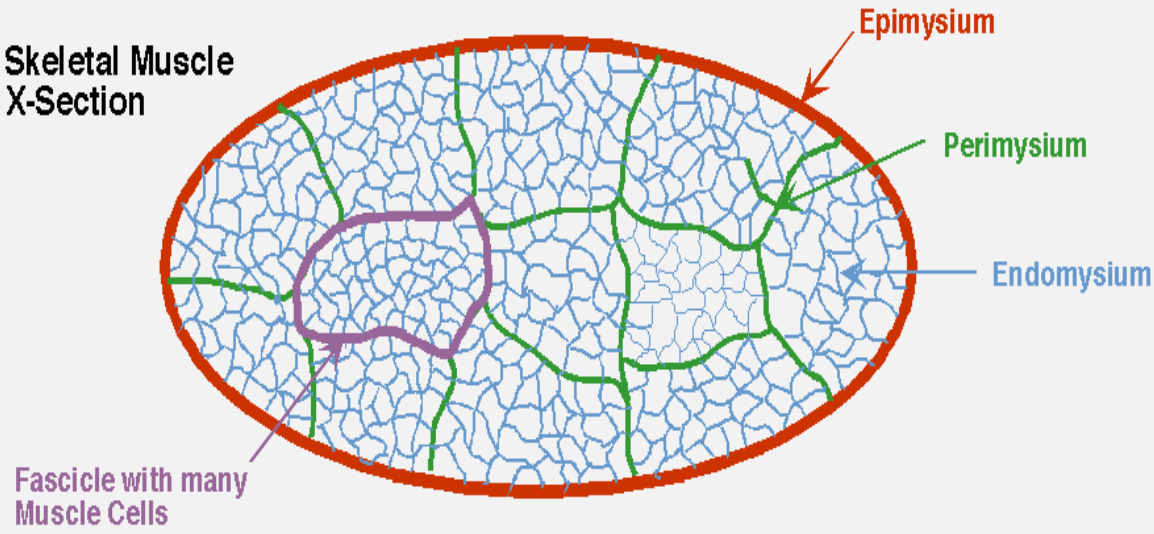

Epimysium: a connective tissue sheath which encapsulates the entire muscle.

Perimysium: connective tissue partitions which arise from the epimysium, and divide the muscle longitudinally into groups of macroscopically visible bundles called fascicles.

Endomysium: thin, delicate connective tissue partitions which arise from the perimysium, and surround each muscle fiber, inserting into the muscle fiber's external lamina.

ACCESSORY APPARATUS OF MUSCLES

- 1. Fasciae (Latin –fascia- bandage)
- 2. Fibrous and osseo-fibrous sheats
- 3. Fibrous and osseo-fibrous canals
- 4. Synovial bursae
- 5. Osseous trochlea for muscle tendons
- 6. Sesamoid bones

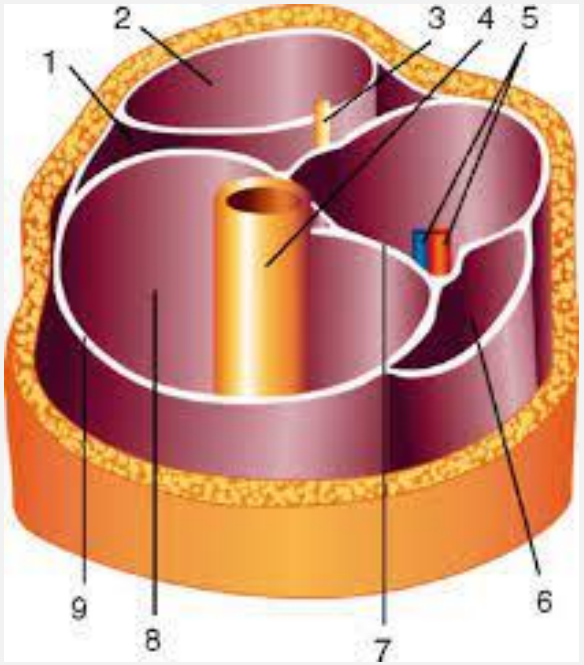

Osseus trochlea for muscle tendons

- Is a bony projection located in that place where the muscle changes its direction
- The trochlea doesn't permit the tendon to displace to the sides

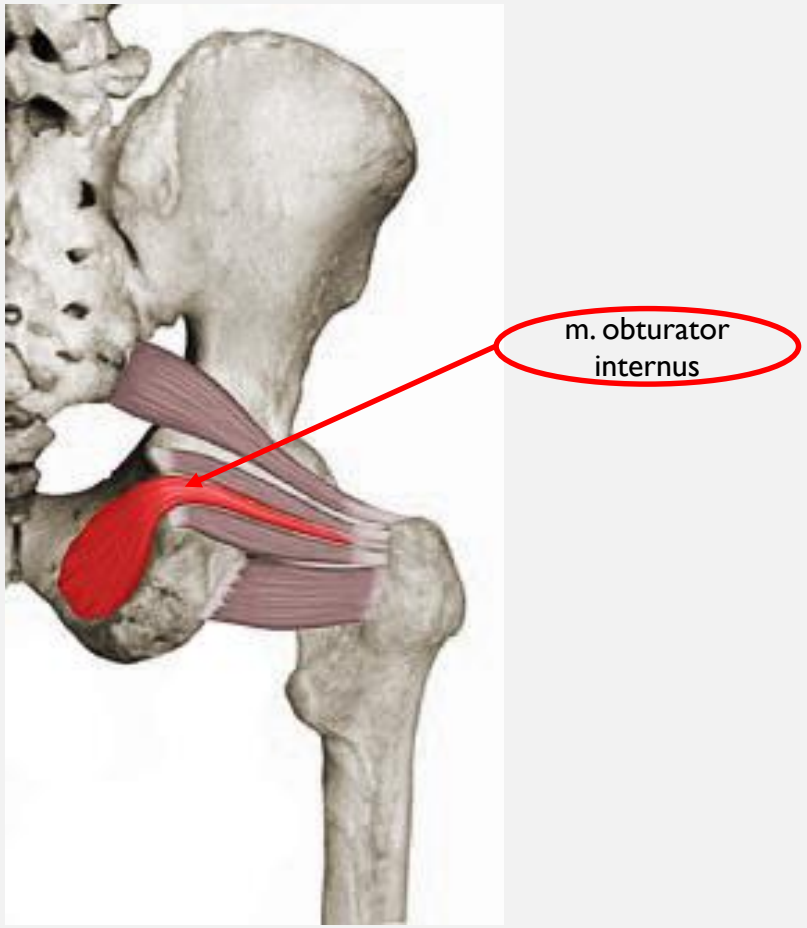

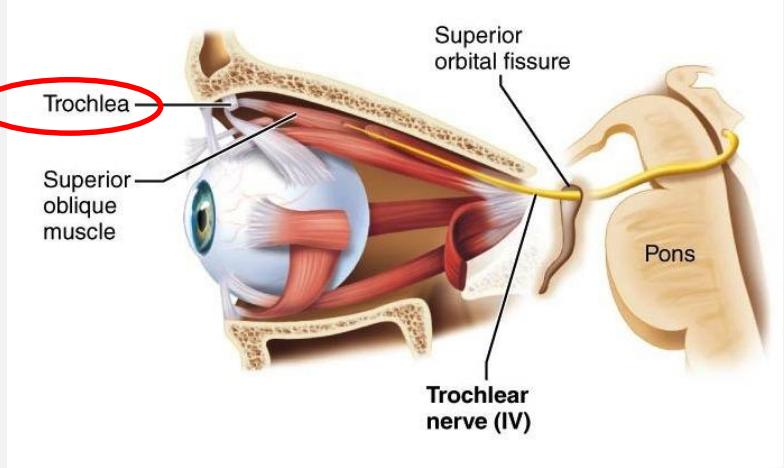

Sesamoid bones

- Developed in the thickness of the tendons, at the places of the tendon attachment
- The largest sesamoid bone is the patella. It plays the role of a trochlea for the tendon of quadriceps femoris extending the knee joint.

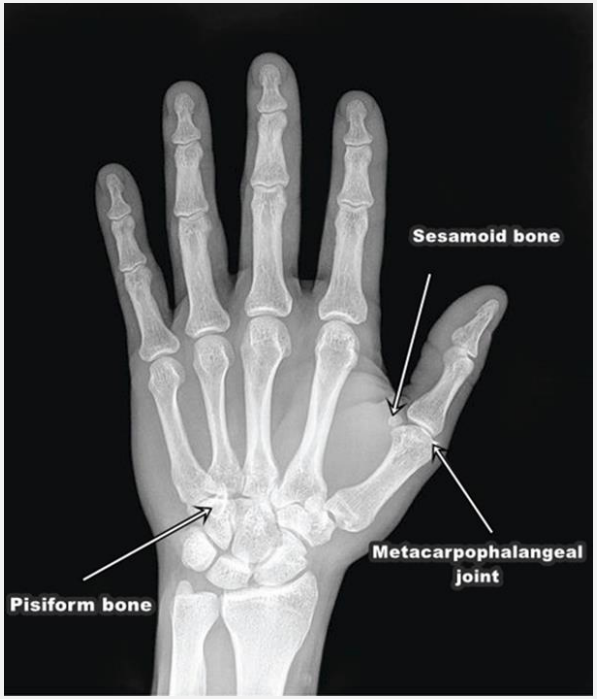

TENDONS

- ***Tendons (bundles) and aponeuroses (sheets)*** are formed by dense, regularly arranged connective tissue into which each end of a muscle inserts, and which, in turn, attach to the outer layer of the periosteum; a few tendons attach directly to bone through Sharpey's fibers.

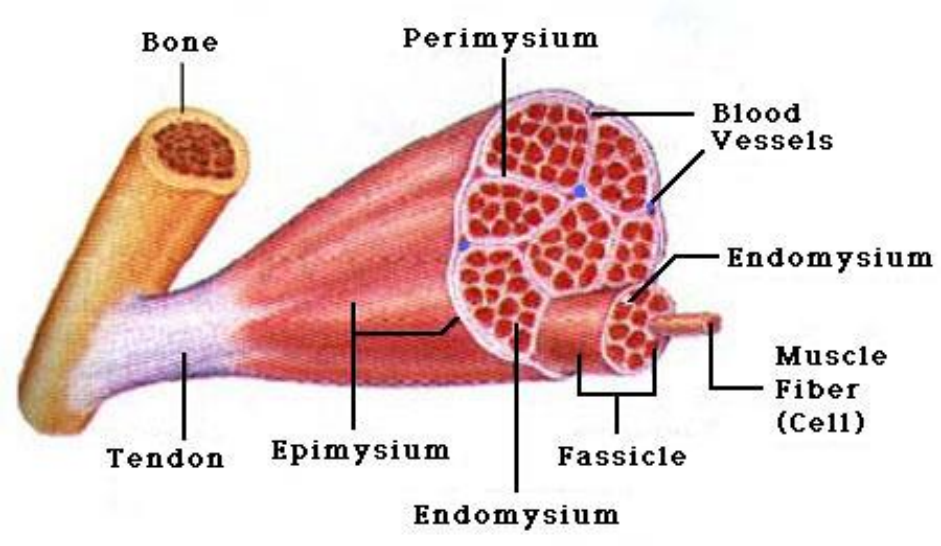

The Difference Between a Tendon and an Aponeurosis

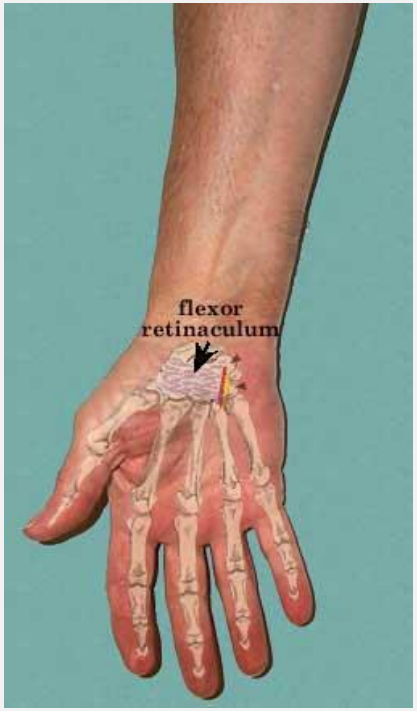

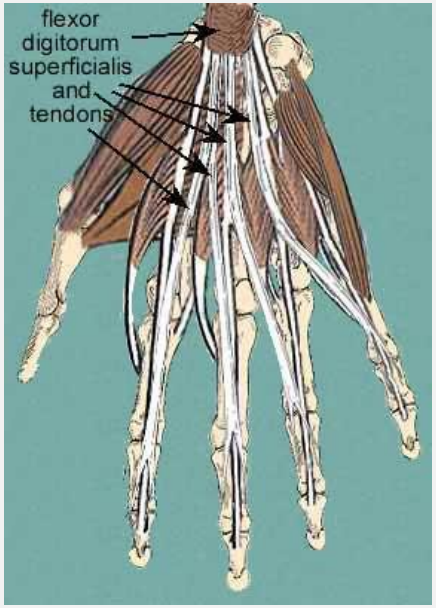

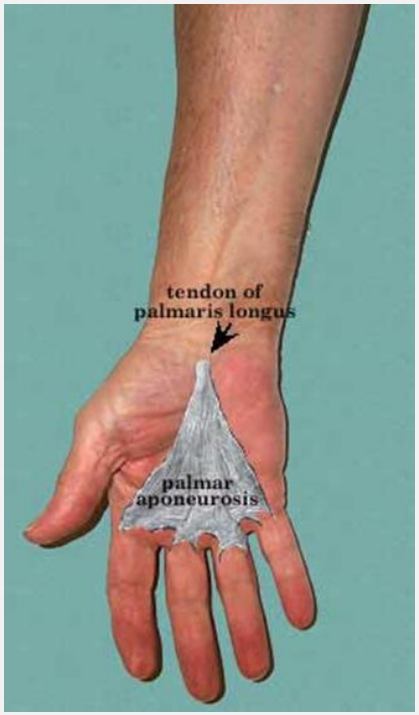

tendon:

a strap or cord of dense irregular fibrous connective tissue connecting a muscle to a bone

aponeurosis:

a thin, flat sheet of dense irregular fibrous connective tissue connecting a muscle to a bone

A flat, wide tendon is called **an aponeurosis**

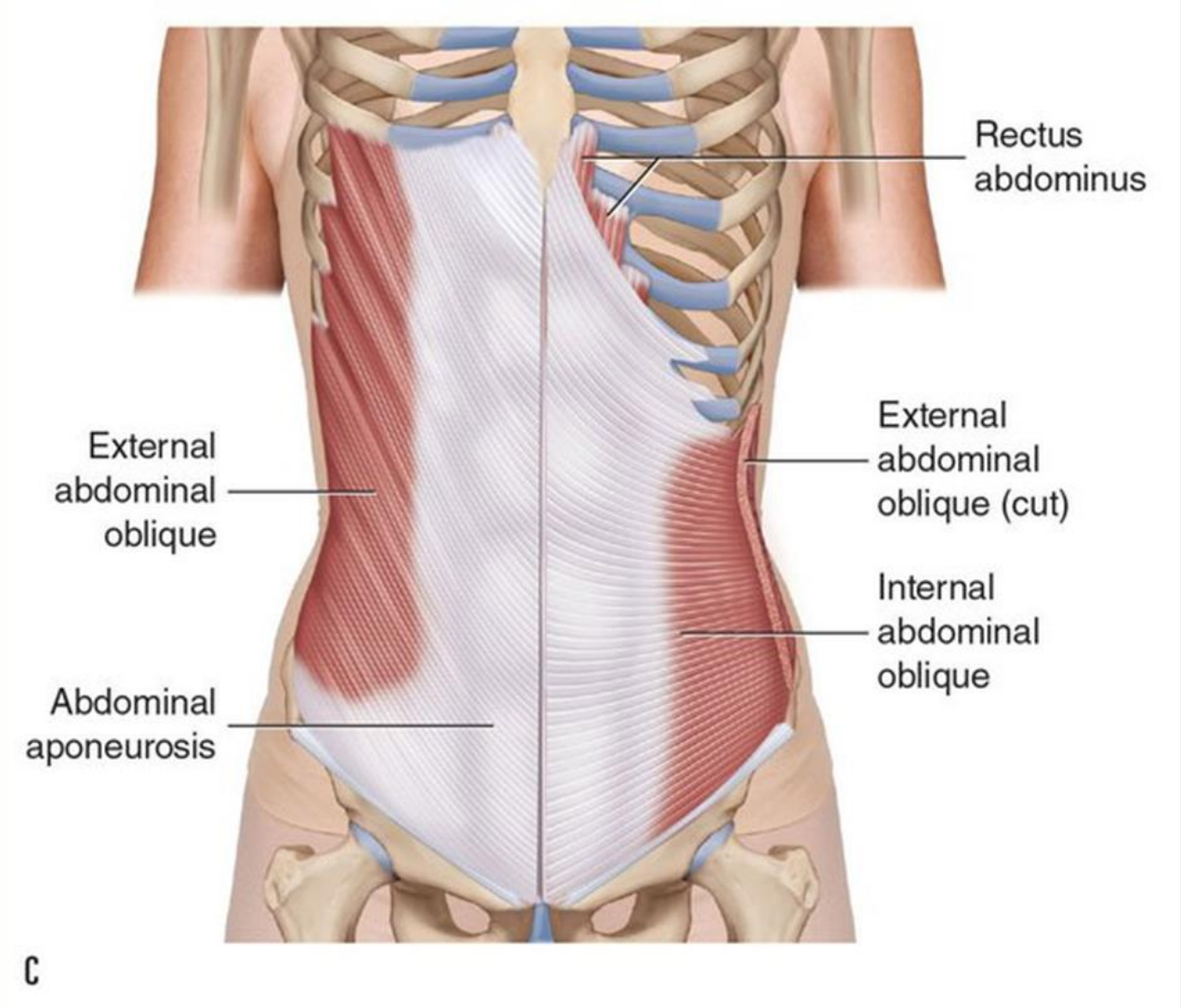

Tendons may continue into the muscle as ***septa*.**

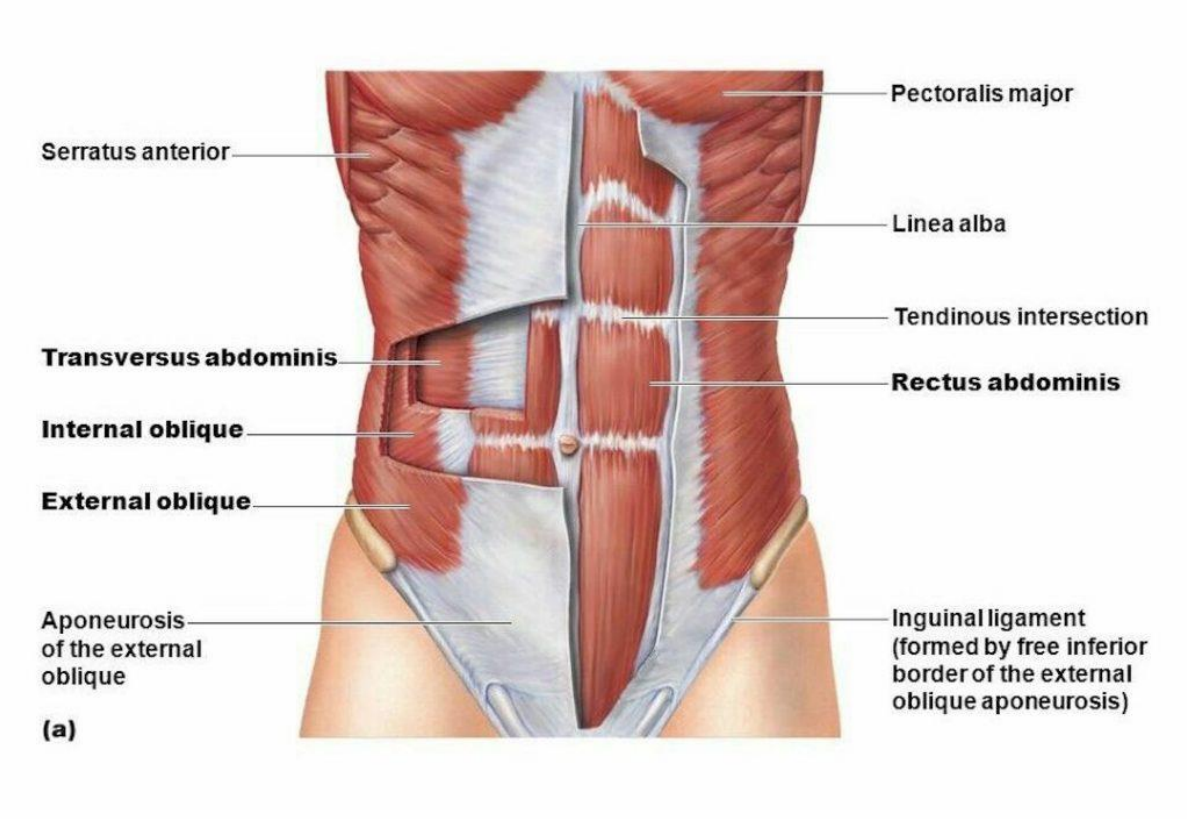

- Muscle **pulling** at the sites of tendinous attachment to bones produces a remodeling reaction within the bones; thus, attachment sites are indicated by ridges, crests, tubercles, and trochanters.

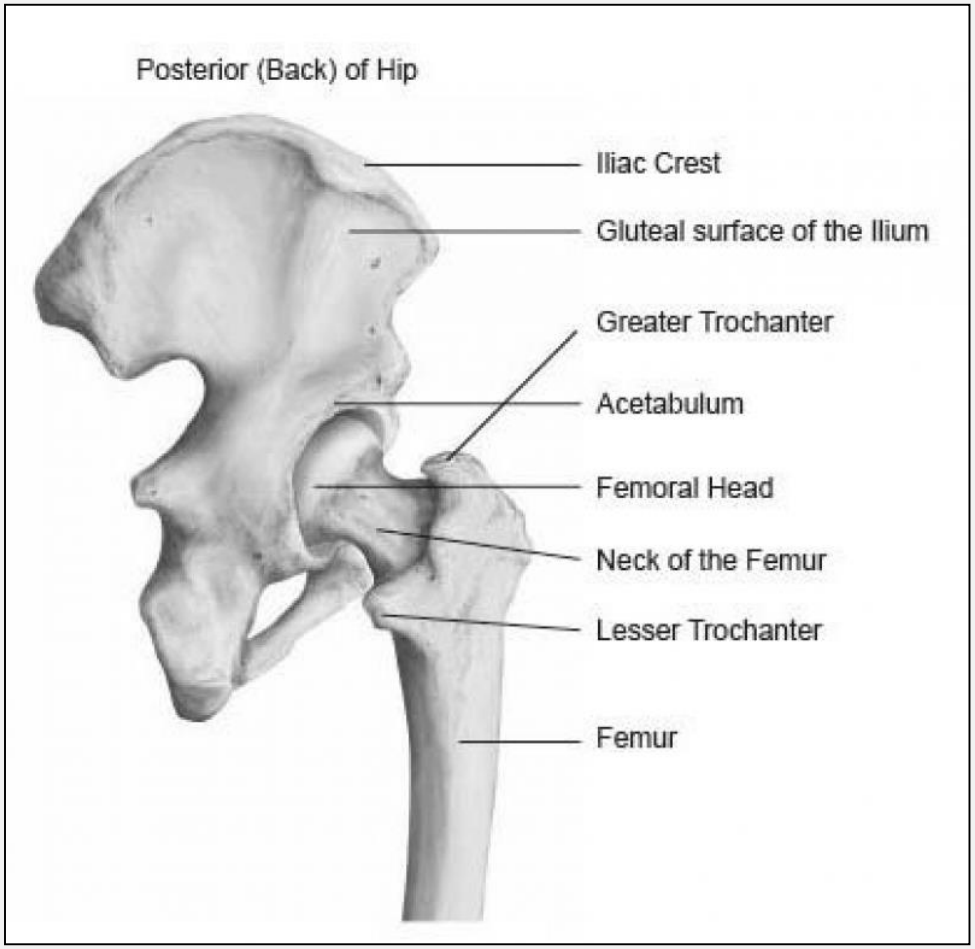

Retinacula are strong fascial bands in the regions of joints that prevent tendons from "bowstringing" away from the joint.

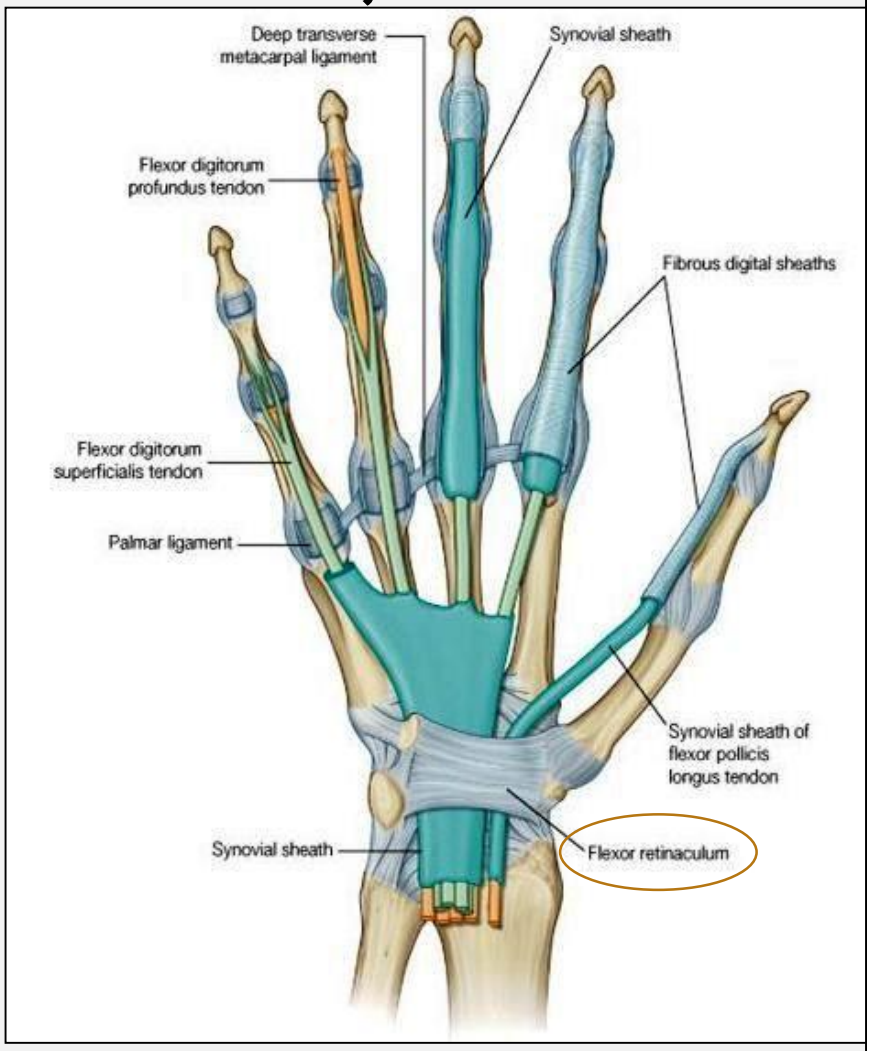

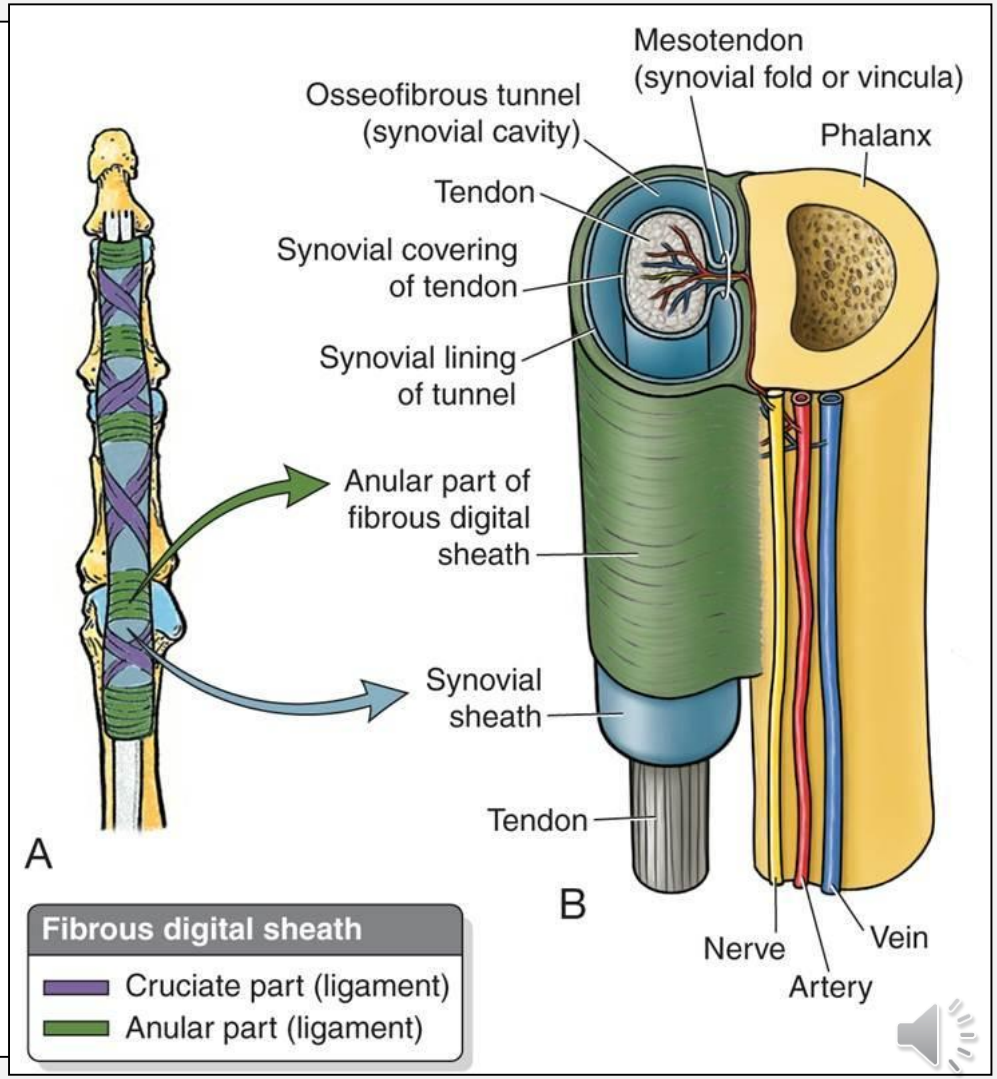

Retinaculum of muscle tendons

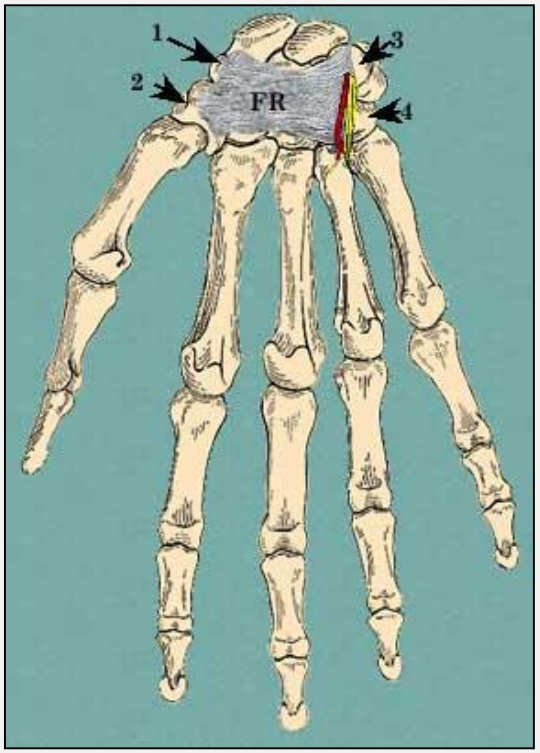

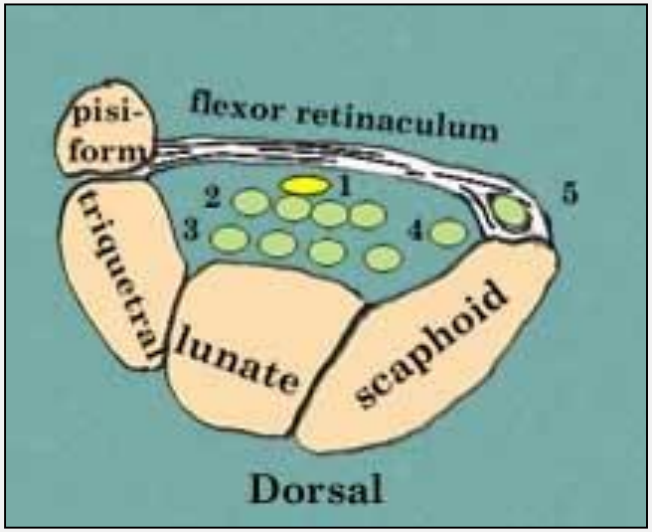

- **Sulcus carpi + retinaculum flexorum = canalis carpi**

Synovial sheaths (covering) of tendons

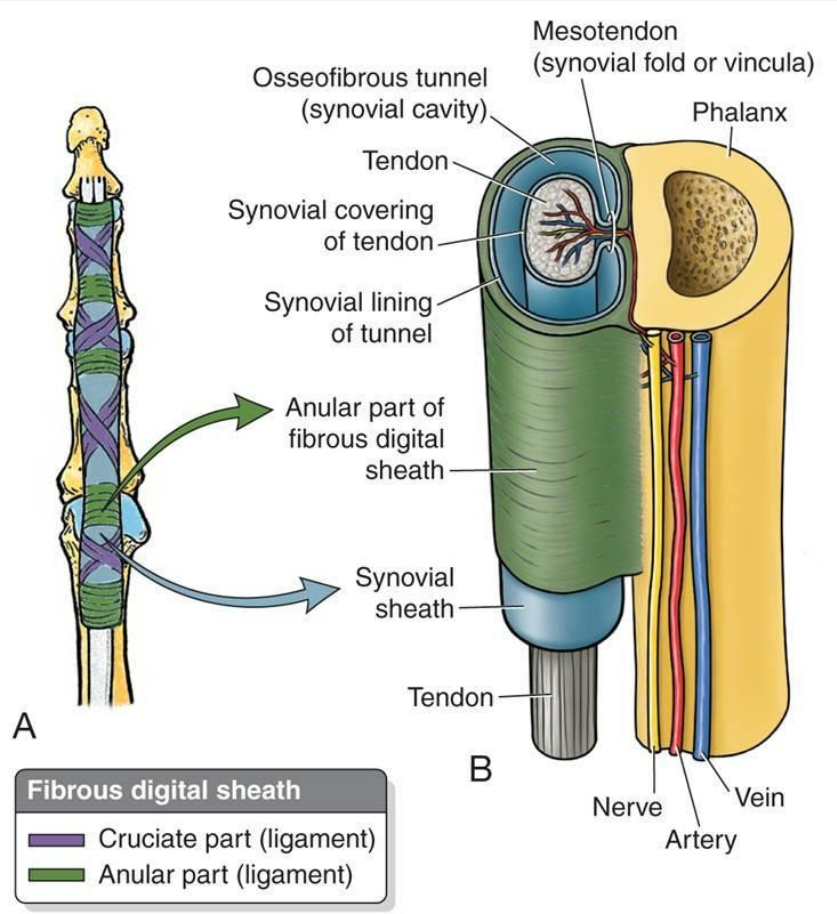

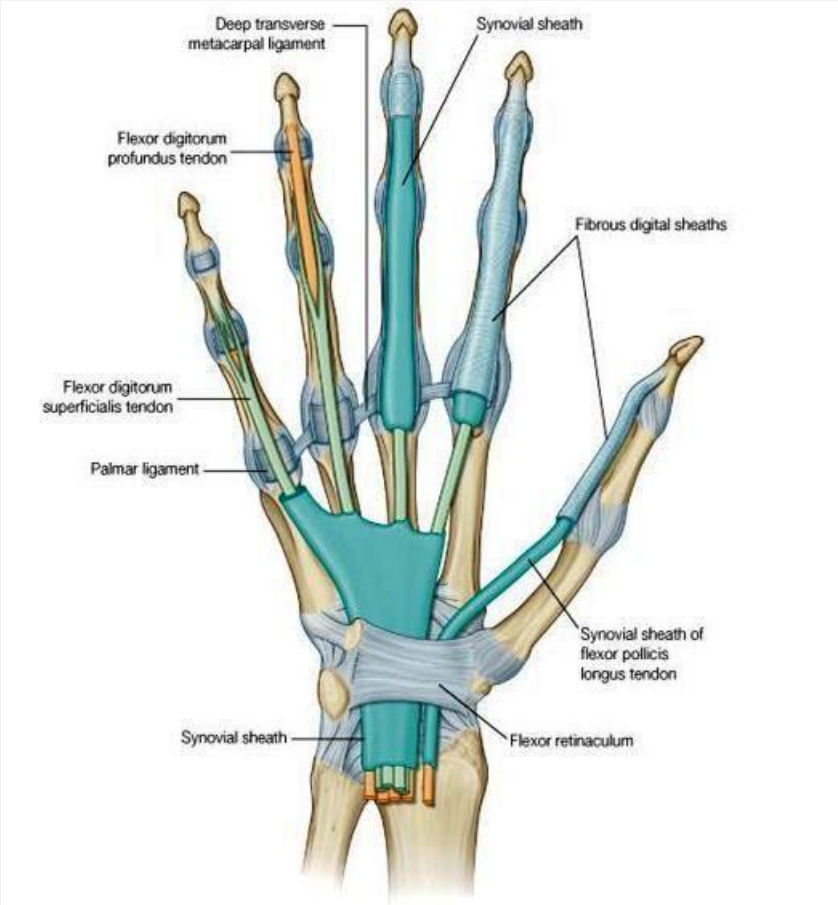

Synovial tendon sheaths are fluid-filled tunnels about muscle tendons that permit a considerable degree of movement and reduce the friction.

Synovial bursa

- are cavities between or within fascial planes , lined by synovial tissue and filled with synovial fluid to reduce friction between tendons, muscles, ligaments, and bones.

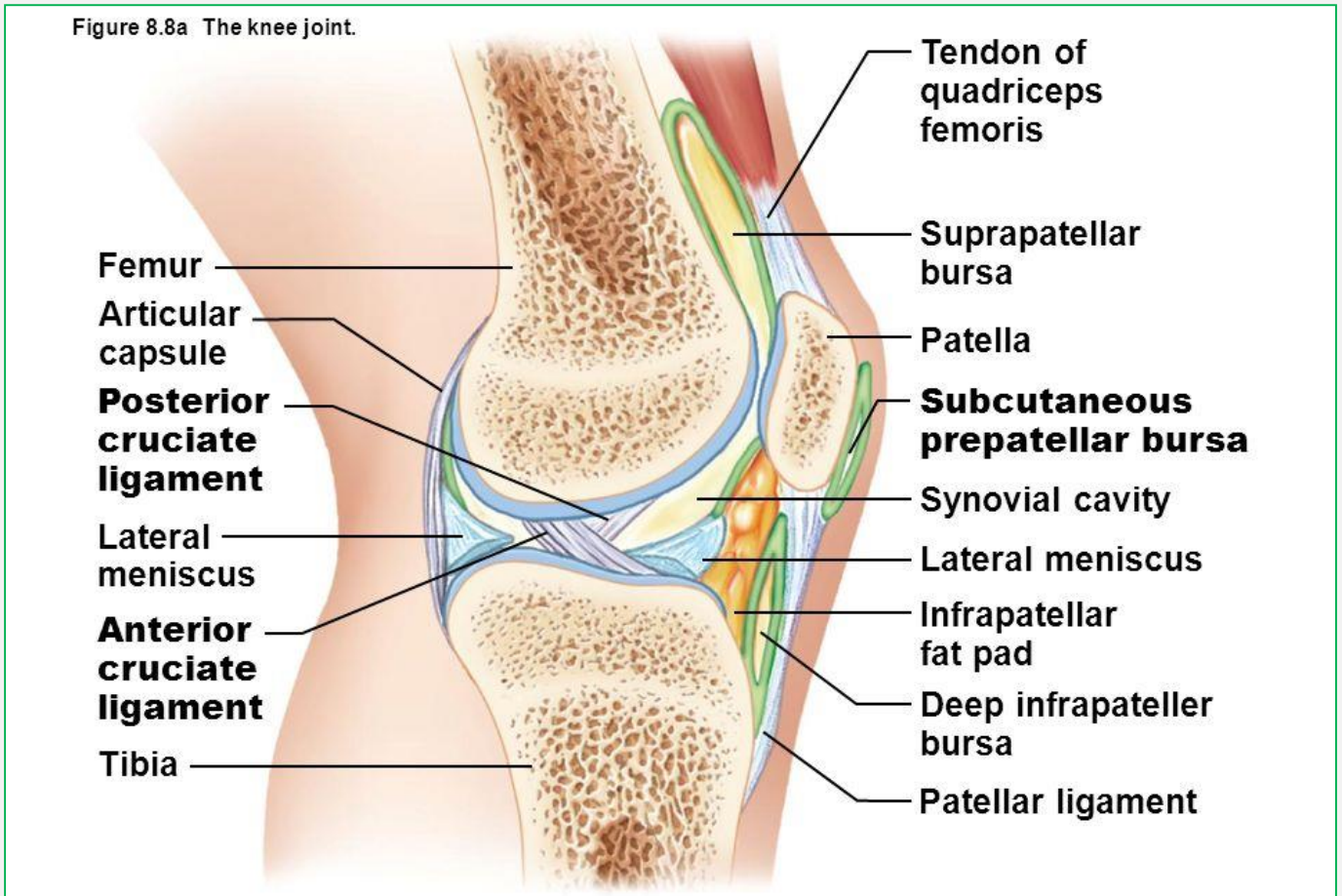

SOMATIC FASCIA

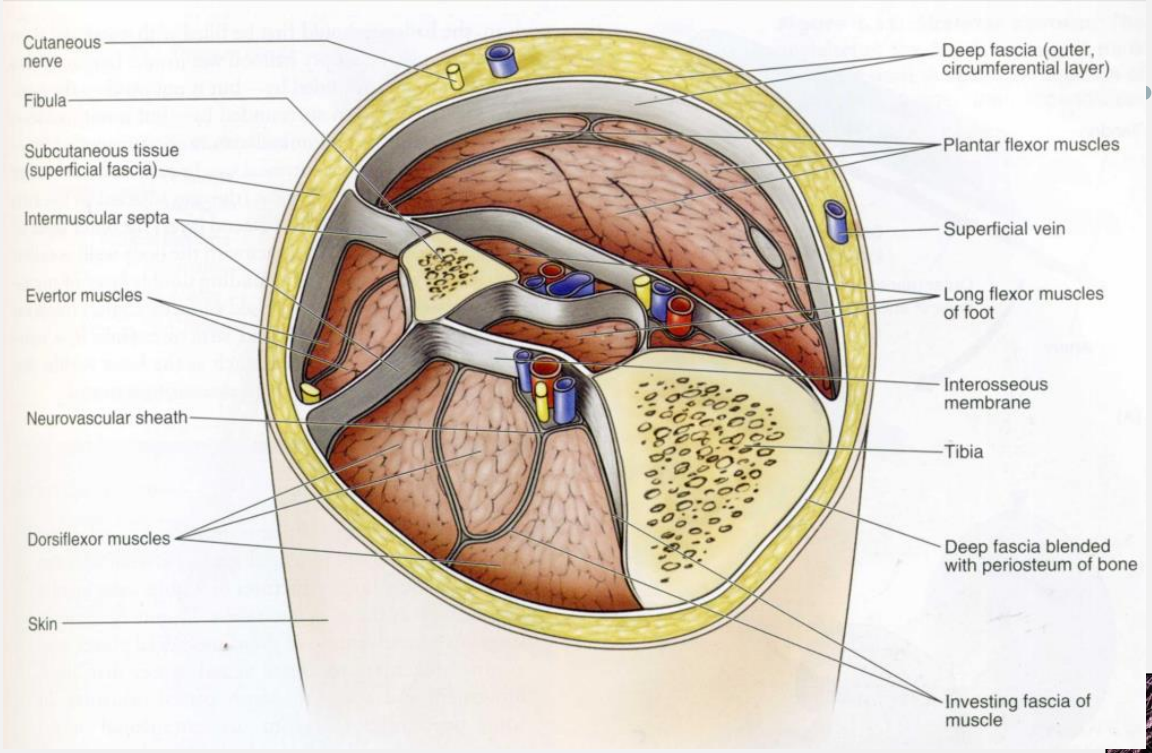

Fascia is loose, irregularly arranged connective tissue composed of fibroblasts, collagen bundles, and some elastic fibers, which forms planes.

- ✓ Superficial
- ✓ Deep
- ✓ Proper
- ✓ Internal



SOMATIC FASCIA

- Superficial – subcutaneous (superficial and deep layers)
- Deep – surrounds group of muscles, form intermuscular septa
- Propria – surrounds separate muscles and separate muscle bundles
- Internal – lines cavities of the body:

1) Endocervical fascia
2) Endothoracic fascia
3) Endoabdominal fascia (+endopelvic)

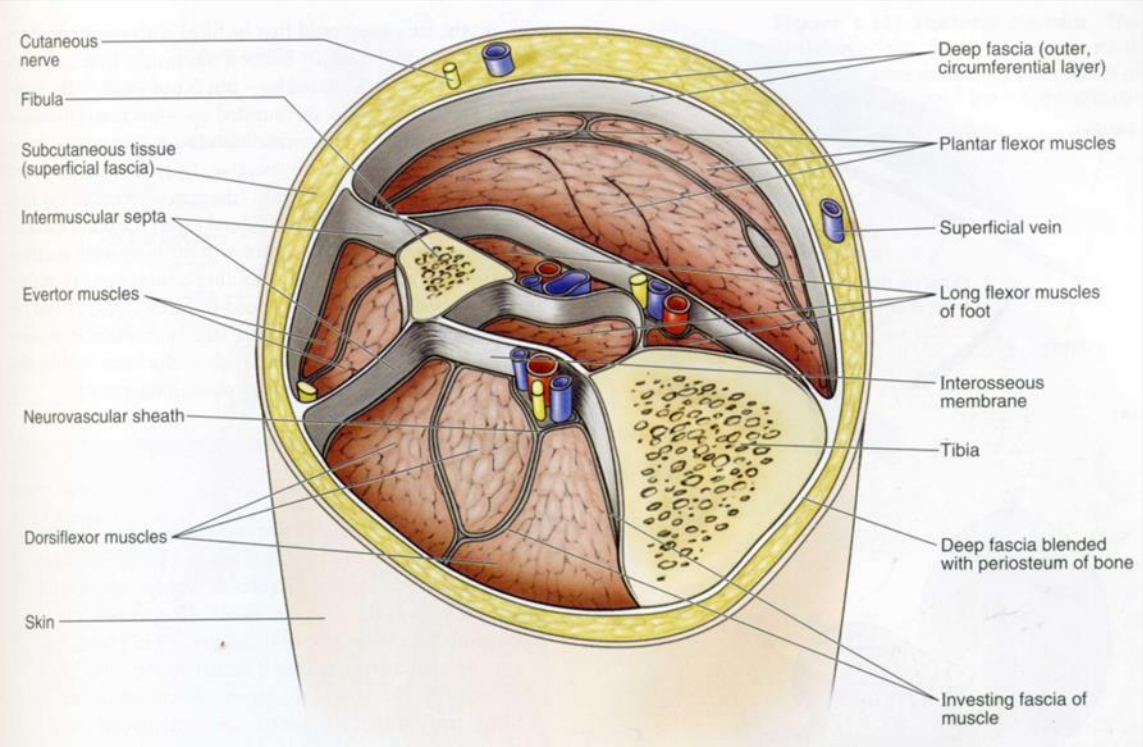

SUPERFICIAL LAYER OF SUPERFICIAL FASCIA (OF CAMPER):

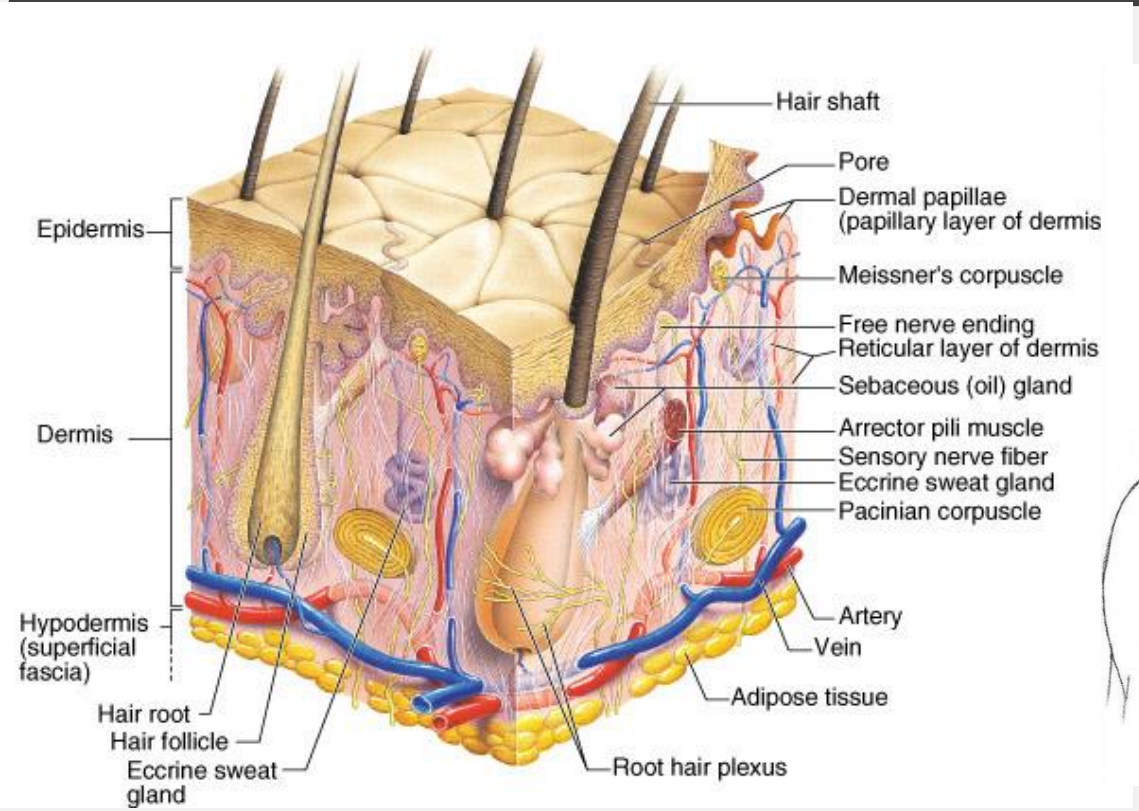

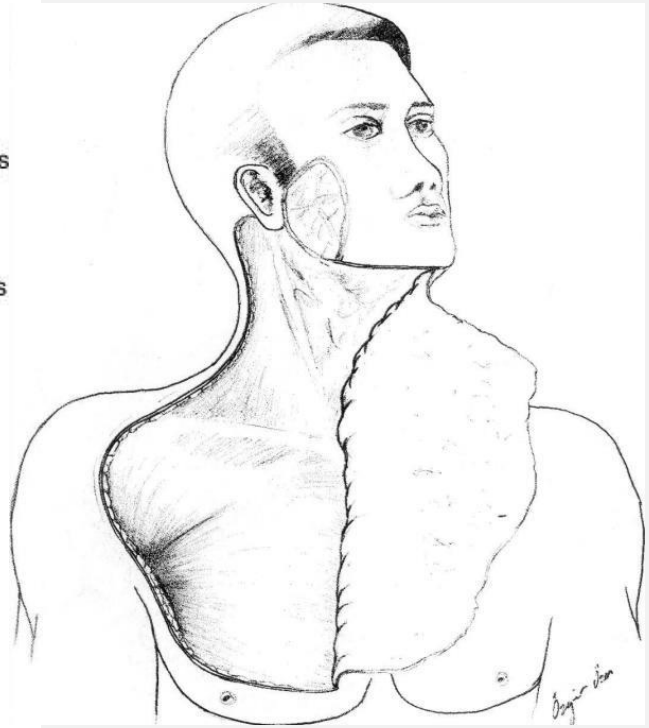

- Outer fatty layer of superficial fascia

SUPERFICIAL LAYER OF SUPERFICIAL FASCIA (OF CAMPER):

- Is predominantly fatty- panniculus adiposus
- Is of variable thickness and serves as insulation and padding
- Contains the superficial arteries, veins, lymphatics, and nerves
- Is particularly sensitive to estrogenic hormones

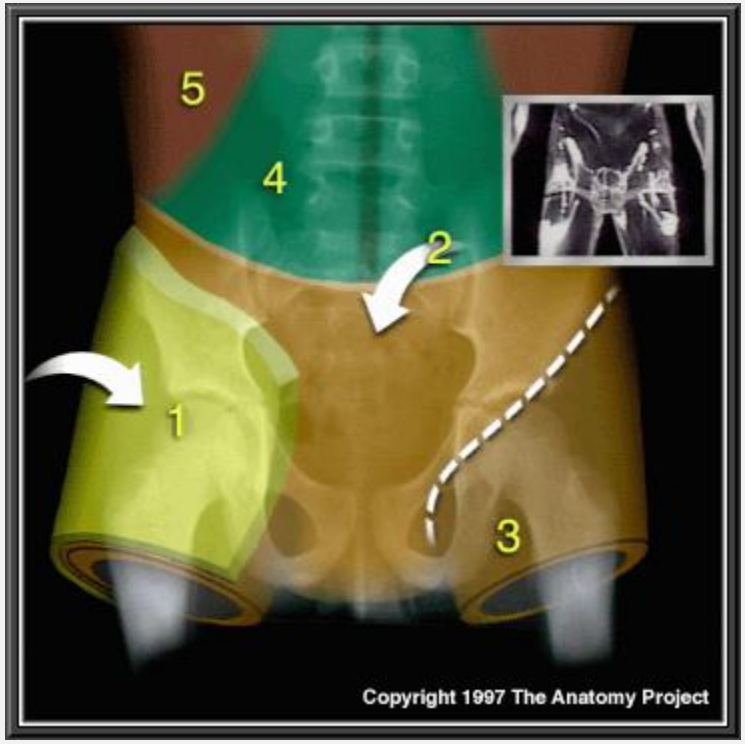

DEEP LAYER OF SUPERFICIAL FASCIA (OF SCARPA):

- (1) Is membranous and relatively thin
- (2) Holds structures
- (3) Fuses with the deep fascia

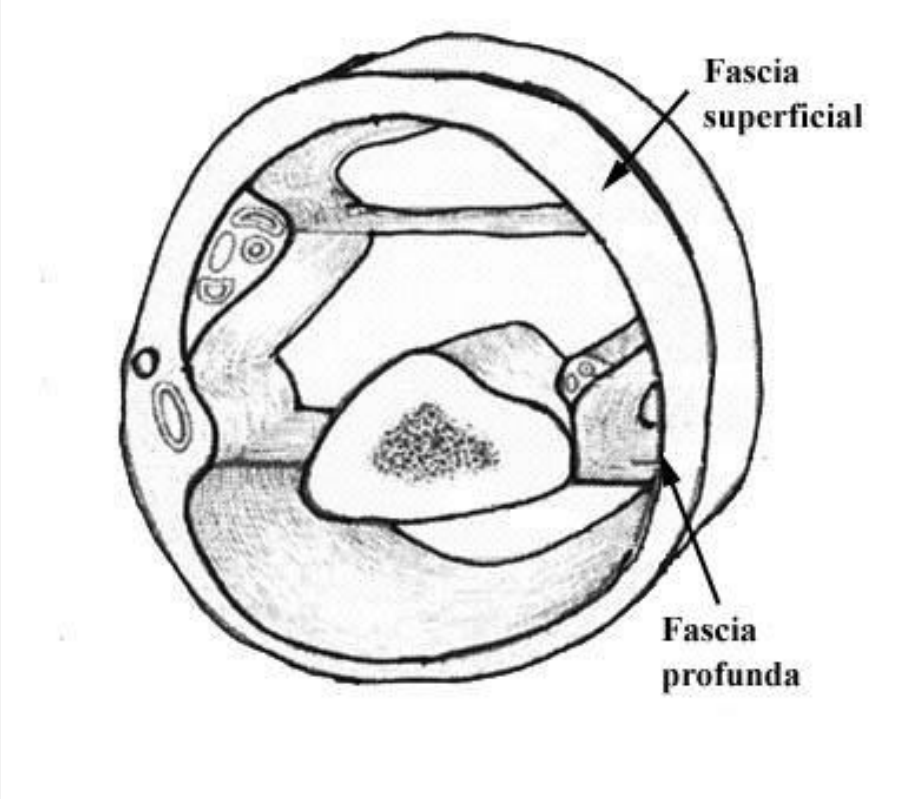

DEEP (INVESTING) FASCIA

- **Deep (investing) fascia** cannot be stripped completely from the structures that it invests (i.e., it becomes continuous with periosteum, perimysium, perineurium, and other adventitial layers.

DEEP FASCIA CONSISTS OF THREE LAYERS:

- **Outer investing fascia** overlies the musculature beneath the superficial fascia.
- **Inner investing fascia** underlies the musculature of the body wall
- **Intermediate investing fasciae** are septa arising from the outer investing fasciae that run between and around individual muscles as well as neurovascular structures.

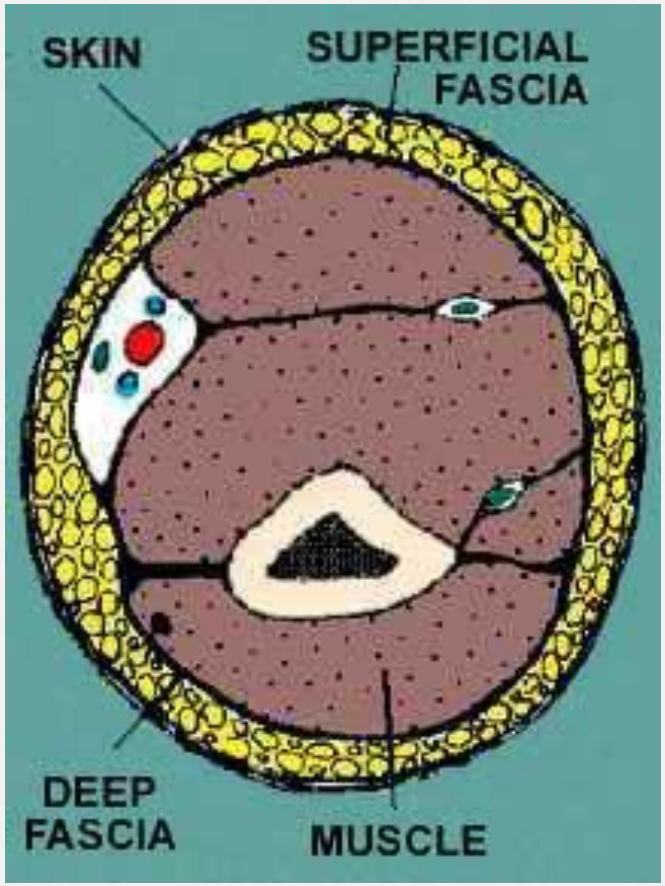

The difference between superficial versus deep fascia.

- **superficial fascia** covers the superficial surfaces of muscle groups and usually lies directly deep to the hypodermis and the skin

- **deep fascia** separates various muscle groups from each other or from bone or other deeper structures such as the parietal linings of body cavities, separates individual muscles, tendons, or ligaments within a muscle group, separates branching nerves, vessels, or ducts in a group, or connects organs to one another in deep tissues other than body cavities

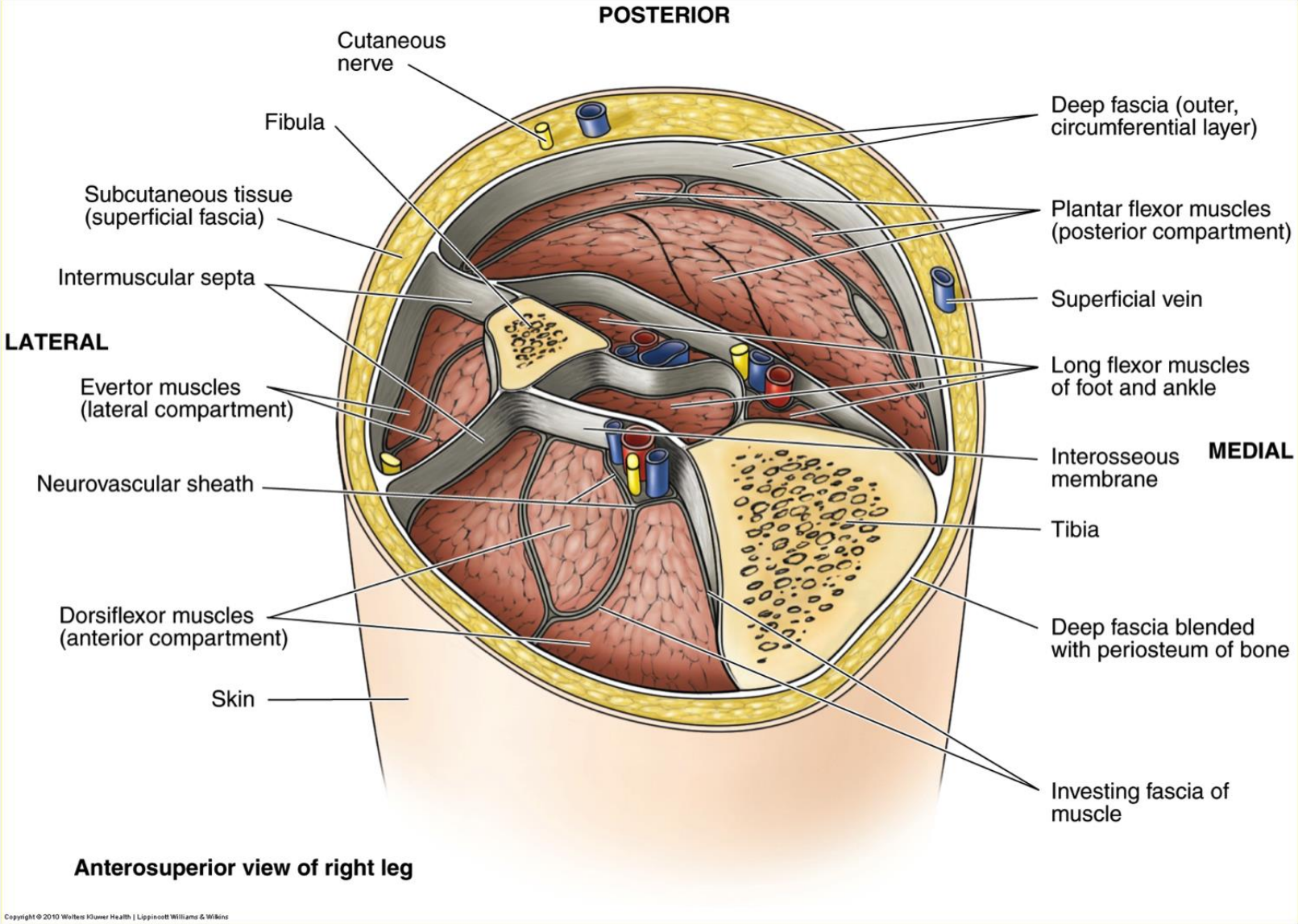

Anterosuperior view of right leg

CLINICAL CONSIDERATIONS

- Fascial planes are easily opened by surgical blunt dissection and by extravasation of fluid, such as blood, urine, and pus.
- Spread of infection across fascial planes is limited.
- Infection may track along fascial planes; a classic example is the spread of tuberculosis of the lumbar vertebrae beneath the psoas fascia to present as an infection in the femoral triangle

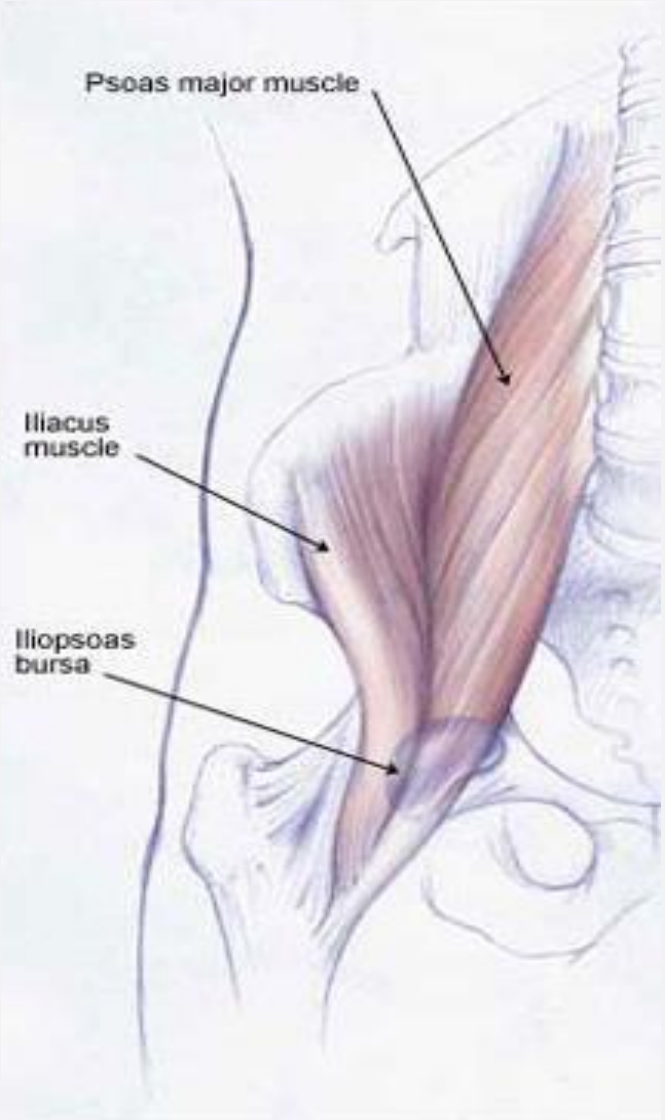

MYOFASCIAL RELEASE

Fascial Distortion Model (FDM)

FDM is a model of thinking that provides a framework to view the function of the body. Fascia is the "wrapper" of our bones, muscles and organs, and is an integral part of the body's nerve network. Treatments in the model focus on the fascia and restoring its function by focusing on correcting distortions in the fascial system and thereby eliminating pain. The model can be used to diagnose and treat various musculoskeletal injuries.

Triggerbands (TB):
Twisted or wrinkled fascial fibers that cause a burning or pulling pain along the course of the fascial band.

Herniated Triggerpoints (HTP):
HTP's are pathological herniations of tissue through a fascial plane. Pain from HTP is often described as a deep ache.

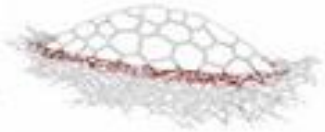

Folding Distortions (FD):
These injuries are similar to what happens to a road map that unfolds and then refolds in a contorted condition. Folding disortortions hurt deep in the joint.

Continuum Distortions (CD):
Injuries of the bone/fascia transition zone. Pain is identified in one spot. These are commonly seen in plantar fasciitis and sprained ankles.

Cylinder Distortions (Cyl):
Anatomically reminiscent of a tangled Slinky™ toy, cylinder distortions cause deep pain in predominatly non-jointed areas. They are also responsible for a wide range of seemingly bizarre symptoms, such as tingling (paresthesia), numbness (diminished sensation), and pain that spontaneously seems to jump from one location to another.

Tectonic Fixations (TF):
When patients complain of joint stiffness, they are describing a tectonic fixation. TF's are fascial surfaces which have lost their ability to glide.

For more information please go to www.afdma.com