Kazan Federal (Volga Region) University
Institute of Fundamental Medicine and Biology
Department of Morphology and General Pathology

Human Anatomy. Introduction

Zaikina Elvira Ildarovna,
MD, PhD, Senior lecturer

'Anatomy is the basis of medical discourse'

Hippocrates, De locis in homini





Human anatomy

- Greek ἀνατομία – "dissection“ (from *ἀνά*=up; *τέμνειν*=cut)

ANATOMY is primarily the scientific study of the morphology of the human body.

Correct diagnosis is important for right treatment !

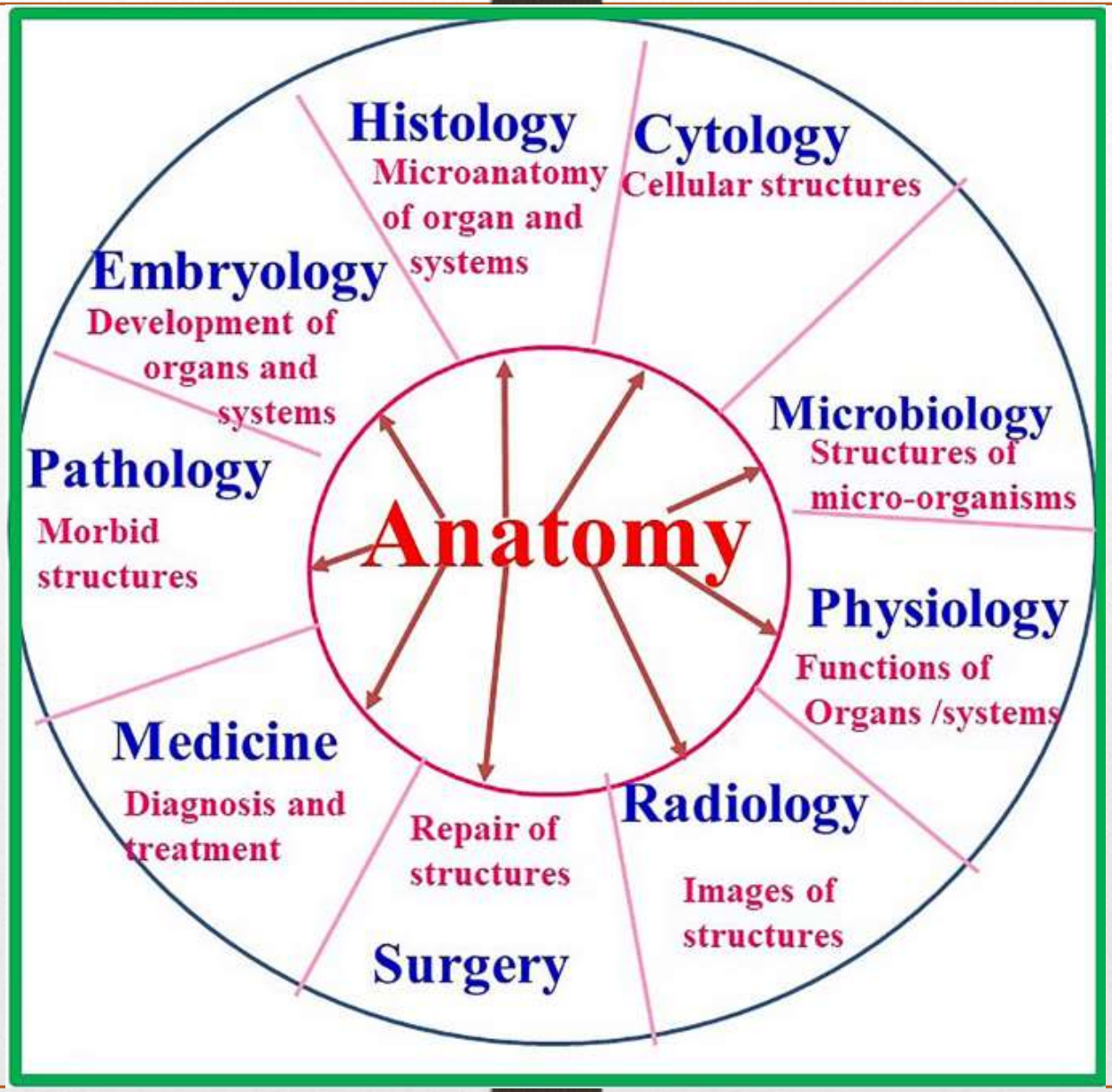
Histology
Microanatomy of organ and systems
Cytology
Cellular structures
Embryology
Development of organs and systems
Microbiology
Structures of micro-organisms
Pathology
Morbid structures
Anatomy
Physiology
Functions of Organs /systems
Medicine
Diagnosis and treatment
Radiology
Images of structures
Repair of structures
Surgery

Ancient Egypt

- The first mention of the structure of the human body are found in ancient Egypt.
- In the XXVII century B.C. Egyptian physician Imhotep described some of the organs and their functions, such as the brain, heart activity, the blood vessels.

Ancient Egypt

Organs were recognized:

- Heart
- Vessels (they emanate from the heart)
- Liver
- Spleen
- Kidneys
- Hypothalamus
- Uterus
- Bladder

The heart is the center of blood supply.

Mesopotamia

Some cuneiform writings from ancient depicted and described body organs that were thought to serve the soul.
The liver, which was extensively studied in sacrificial animals, was thought to be the "guardianship of the soul and of the sentiments that make us men." This was a logical assumption because of the size of the liver and its close association with blood, which was observed to be vital for life.

Ancient China

- Referred to the heart, liver, lungs and other organs of the human body.
- Holistic phylosophies on health and disease

The iconized figures in their illustrations suggest alternative ways of understanding anatomy.

Ancient China

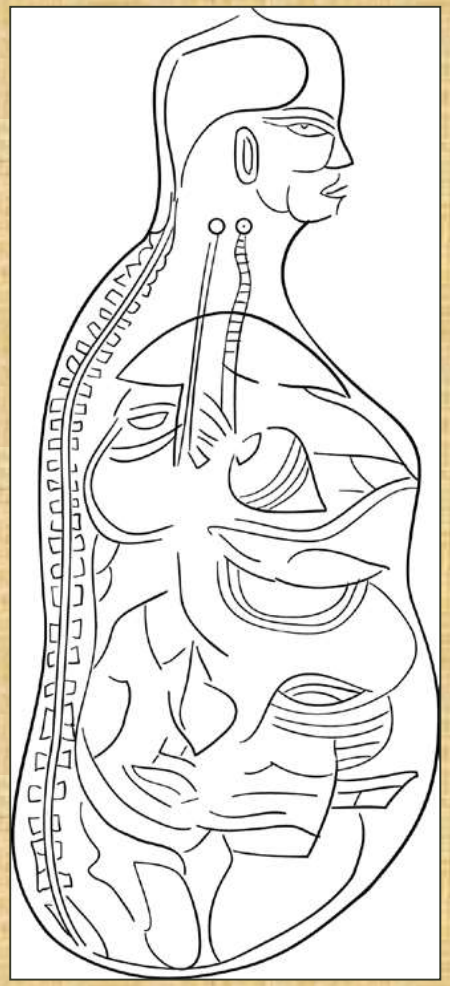

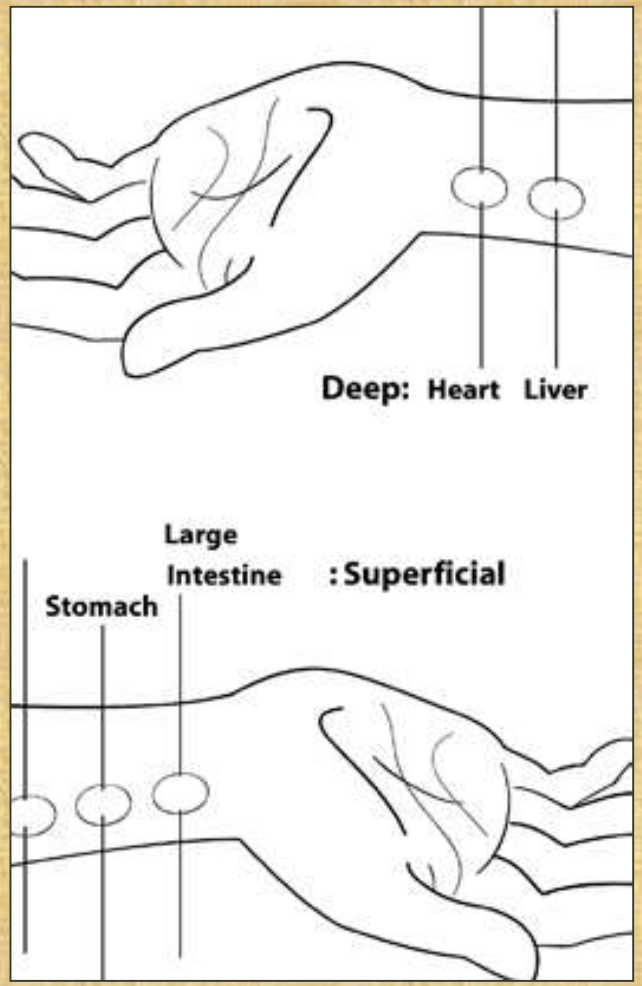

Ancient India

Texts form the foundation of Ayurvedic medicine:

- *the Susruta Samhita*
- *the Charaka Samhita*

- important surgical and anatomical information (about muscles, nerves, brain and spinal cord), taken from:

- animal sacrifice
- chance observations of improperly buried human bodies
- examinations of patients made by doctors during treatment

Ancient Greece

Nomenclature, methods and applications for the study of anatomy all date back to the Greeks.

Alcmaeon of Croton

- constructed a background for medical and anatomical science with the dissection of animals.
- identified the optic nerves and the tubes later termed the Eustachius.

Ancient Greece



Hippocrates

(460–377 B.C.)

- the most famous of the Greek physicians of his time

- <u>THE FATHER OF MEDICINE</u>

- Described:
  - musculoskeletal structure
  - functions of organs (kidney, heart)
  - tricuspid valve (heart)

Ancient Greece

Herophilus

(335–280 or 255 BC)

- the first dissections of human cadavers
- differentiated arteries and veins
- measured pulse
- described cranial nerves, brain, liver, duodenum, etc.
- brain is the central organ
- together with Erasistratus they founded Anatomy as science



Ancient Greece

Galen (130-200 A.D.)

- served as chief physician to the gladiators in Pergamum
- studied anatomy on pigs and apes
- two great anatomical works are

"On anatomical procedure" and
"On the uses of the parts of the body of man"

The information in these tracts became the foundation of authority for all medical writers and physicians for the next 1500 years until they were challenged by Vesalius and Harvey in the 16th century.

1235 – first medical school in Salerno (Italy)

XIII century - discovery of Ethanol – the main fixative till **1893**, when Formalin was discovered



Leonardo da Vinci (1452-1519)

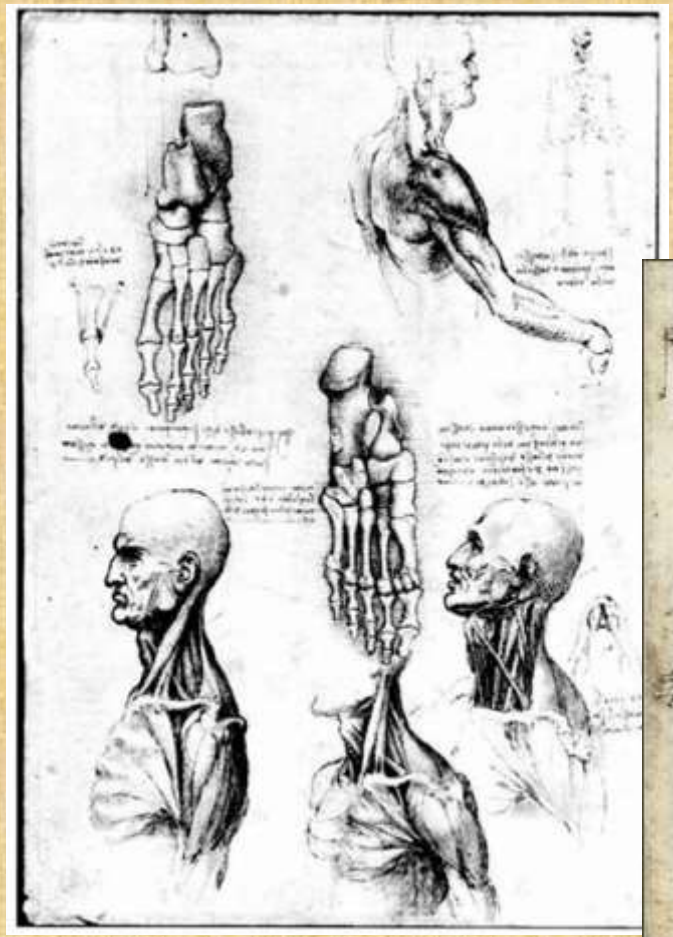

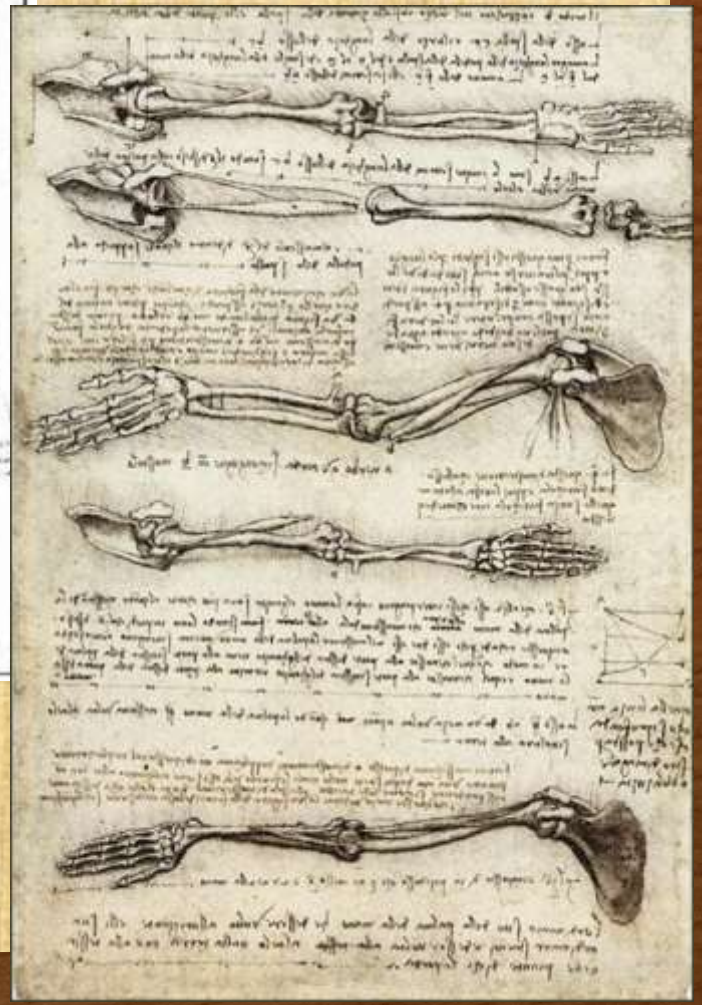

Leonardo da Vinci

(1452-1519)

"If you find from your own experience that something is a fact and
it contradicts what some authority has written down, then you
must abandon the authority and base your reasoning on your own
findings"

De Humani Corporis Fabrica

Andreas Vesalius
(1514-1564)

- challenged (оспаривать, бросать вызов) Galen's anatomical teachings

Andreas Vesalius
(1514-1564)

De Humani Corporis Fabrica

- Vesalius' most impressive contribution to the study of the muscular system may be the **illustrations** that accompany the text in *De fabrica*, which would become known as the "muscle men".
- He describes the source and position of each muscle of the body and provides information on their respective operation.


DE HVMANI CORPORIS FABRICA LIBRI VI.
MVSCV
ORVM TABVLA

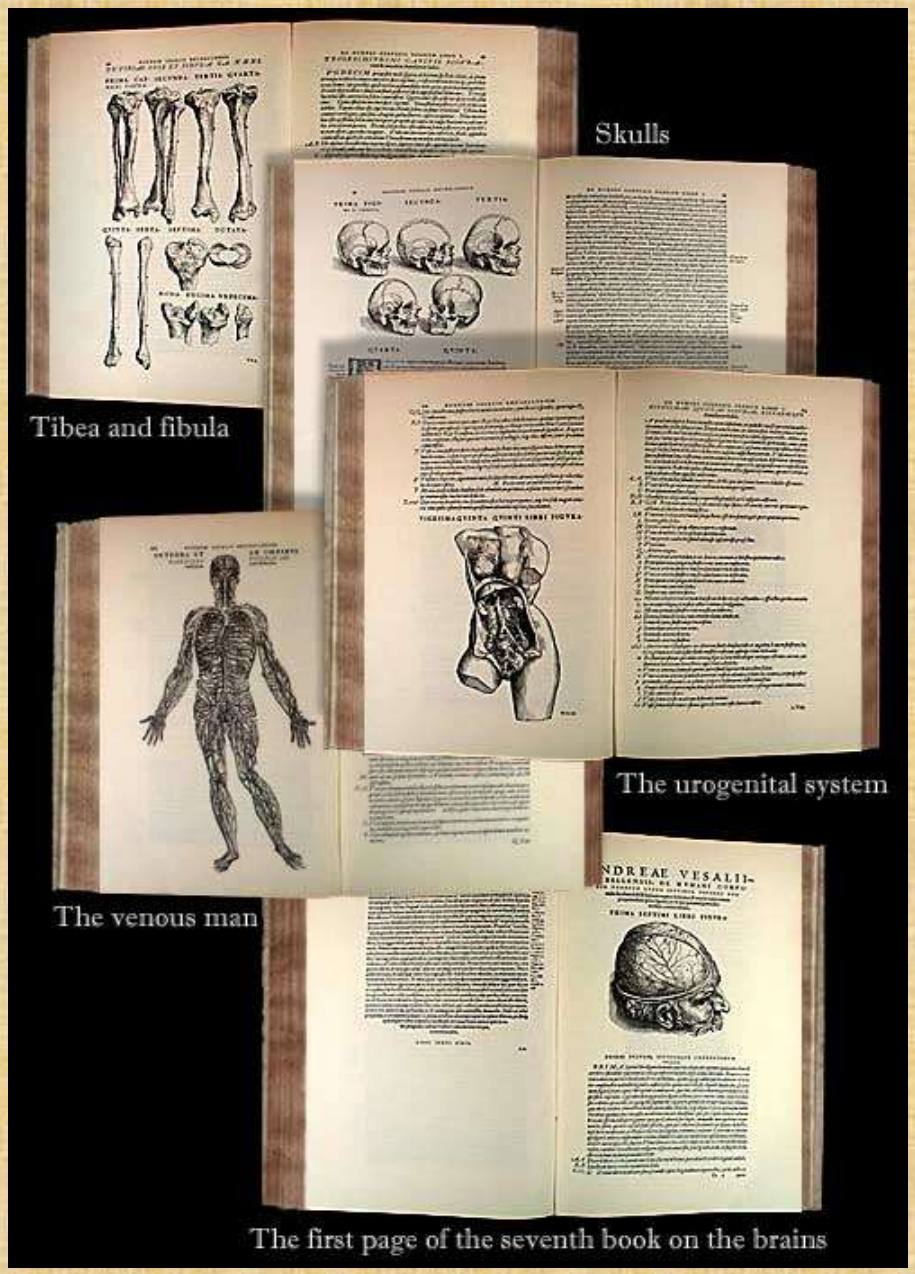
Skulls
Tibea and fibula
The urogenital system
The venous man
The first page of the seventh book on the brains

Anatomic theaters:

Montpellier 1556
London 1557
Pisa 1569
Basel 1589
Padua 1594
Bologna 1595
Leiden 1597
Amsterdam 1619



HIC LOCUS EST, UBI MORS GAUDET SUCCERERE VITAE

Bologna, Italy

Kazan, Russia

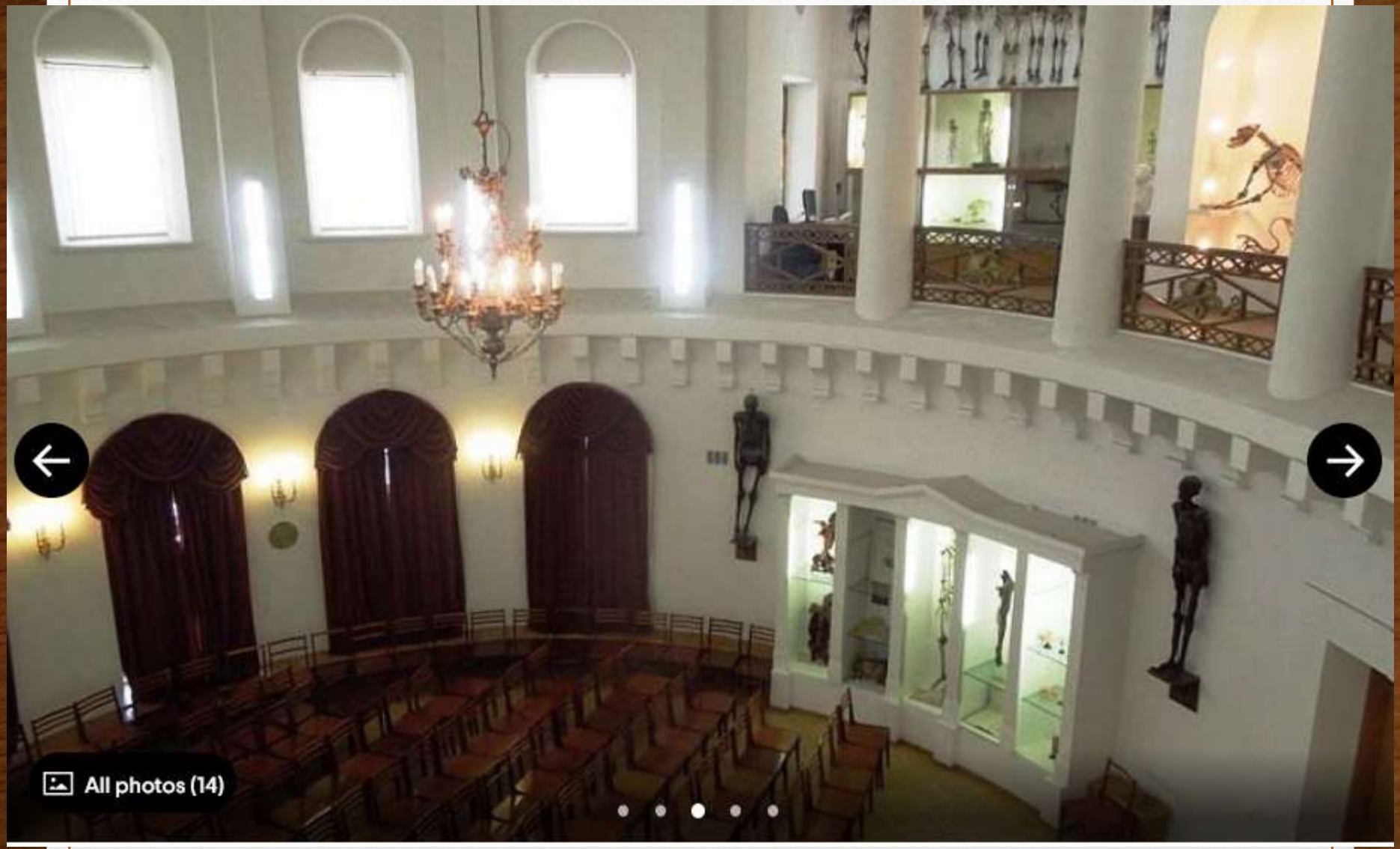
All photos (14)

End of XVII Century – Anatomy is base of medical education

The Anatomy Lesson of Dr. Nicolaes Tulp (1632), Rembrandt

- He is known for developing techniques for preserving anatomical specimens
- His anatomical preparations included over 2,000 anatomical, pathological, zoological, and botanical specimens, which were preserved by either drying or embalming.

Frederik Ruysch
(1638 – 1731)

The Anatomy Lesson of Dr. Frederick Ruysch by Jan van Neck (1683). Amsterdam Museum.

Marcello Malpighi
(1628 – 1694)

- the "Father of microscopical anatomy, histology, physiology and embryology“

- the Malpighian corpuscles and Malpighian pyramids of the kidneys

- 1661 – the first person to see capillaries in animals – the link between arteries and veins

- “il capello” (ital.) – “hair”

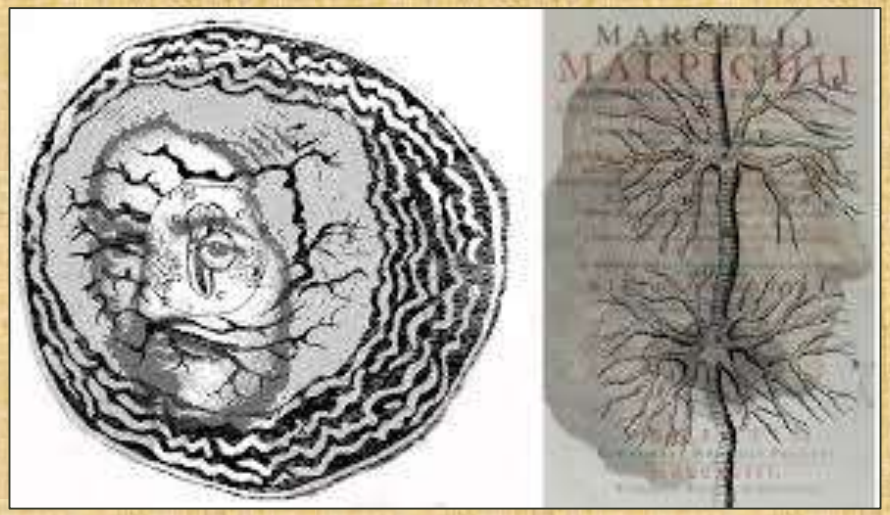

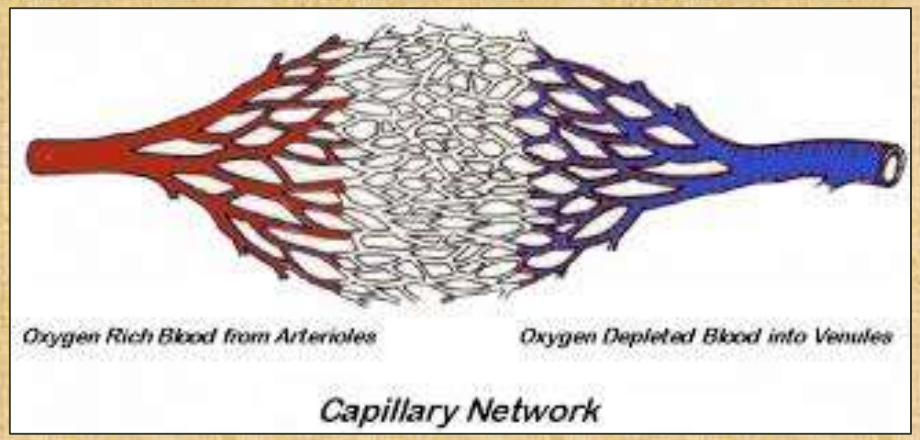

XIX Century – formulation of Cell theory

Matthias Jakob Schleiden
(1804—1881)

Theodor Schwann
(1810 — 1882)

Rudolf Ludwig Karl Virchow
(1821 — 1902)

Three main postulates of the cell theory are:

1. All living organisms are composed of one or more cells
2. The cell is the most basic unit of life
3. All cells arise only from pre-existing cells (*Omnis cellula e cellula)*

Pirogov slices

Nikolay Ivanovich Pirogov
(1810-1881)

- the scientific foundations of the surgery,
- conducted experiments on vascular ligation,
- to study topographic relations, he developed a method of serial cuts of frozen human bodies

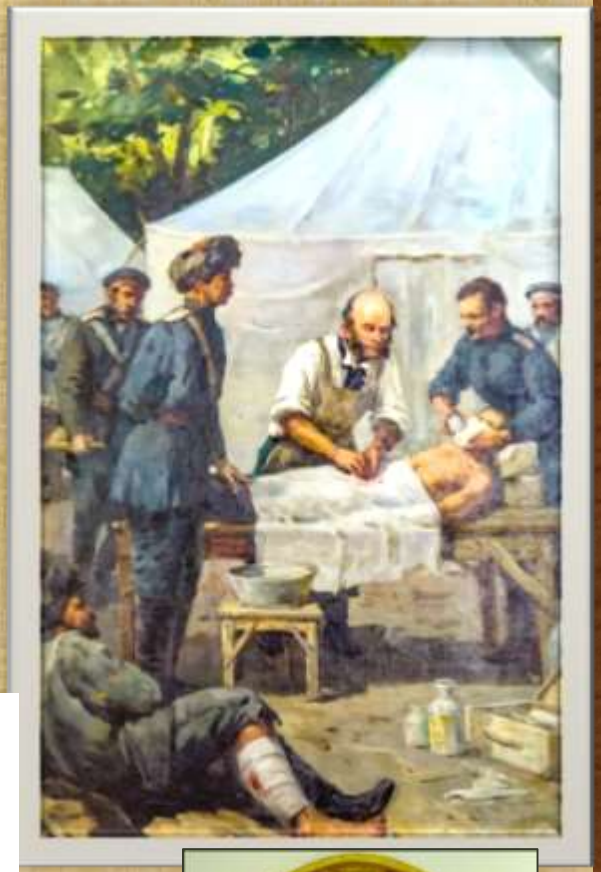

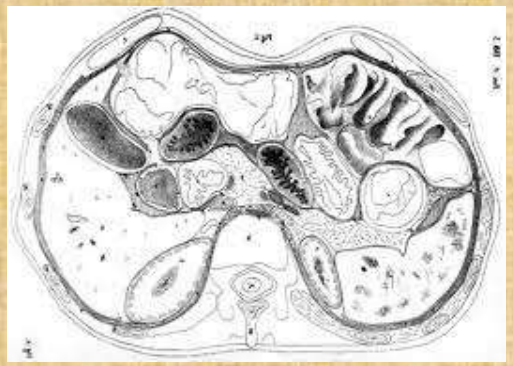

Functional Anatomy



Peter Franzevich Lesgaft
(1837-1909)

- founder of functional anatomy
- established the relationship between the structure and function of bones, joints, muscles,
-established patterns of course and branching of blood vessels

Wilhelm Conrad Röntgen
(1845-1923)

1895 - the discovery of X-rays
1901 - Nobel Prize (first in physics)

Human Anatomy in XXth Century

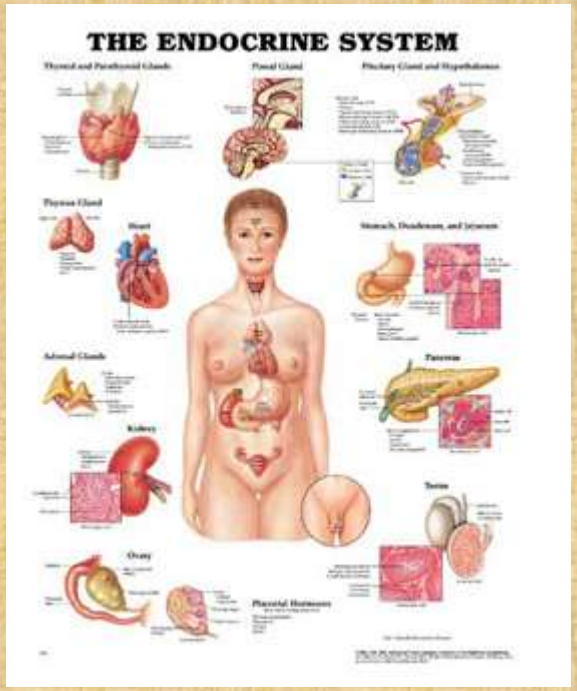



- simplification and standardization of nomenclature
- growing understanding of sciences such as evolutionary and molecular biology
- endocrinology have explained the purpose of glands that anatomists previously could not explain
- medical devices such as MRI machines and CAT scanners have enabled researchers to study the organs of living people or of dead ones

In November 1979, Gunther von Hagens applied for a German patent, proposing the idea of preserving animal and vegetable tissues permanently by synthetic resin impregnation (plastination).



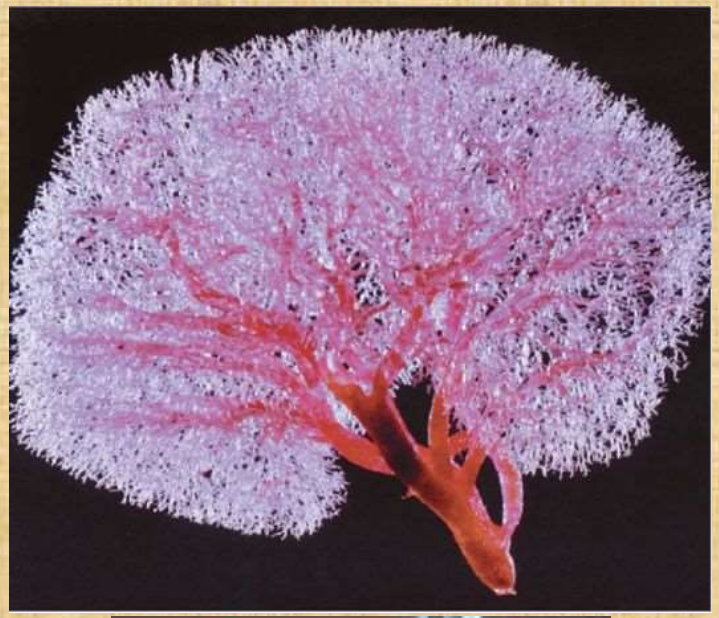

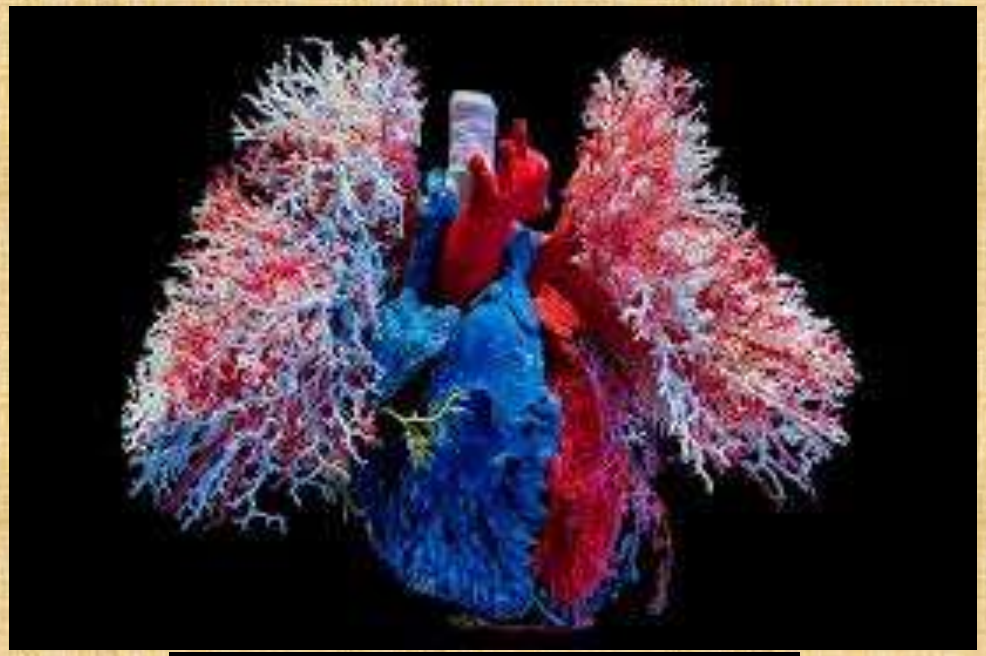

Welcome to the world of Human Anatomy!

Methods of Anatomical Study

Examination of Cadaver

Examination of a Living Human Being

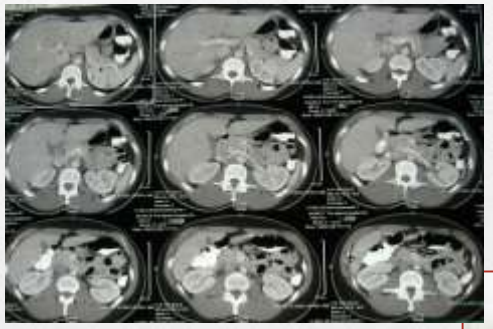

Anatomical language is the fundamental international language of medicine !



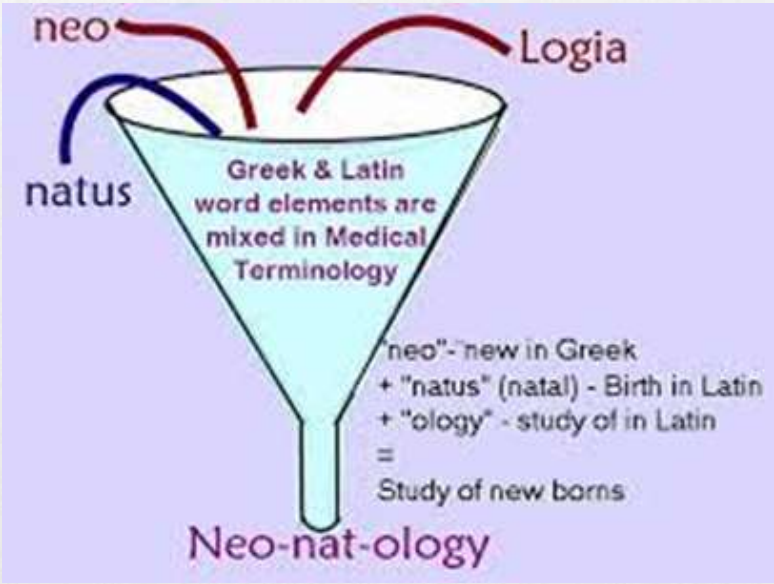

Medschool


Sing.
f
-a
plural
f
-ae
Remind me again why we learning Latin in medschool?
Because Latin is international language of medicine, you can talking to foreign doctors in Latin. Don't worry I teach you only important stuff

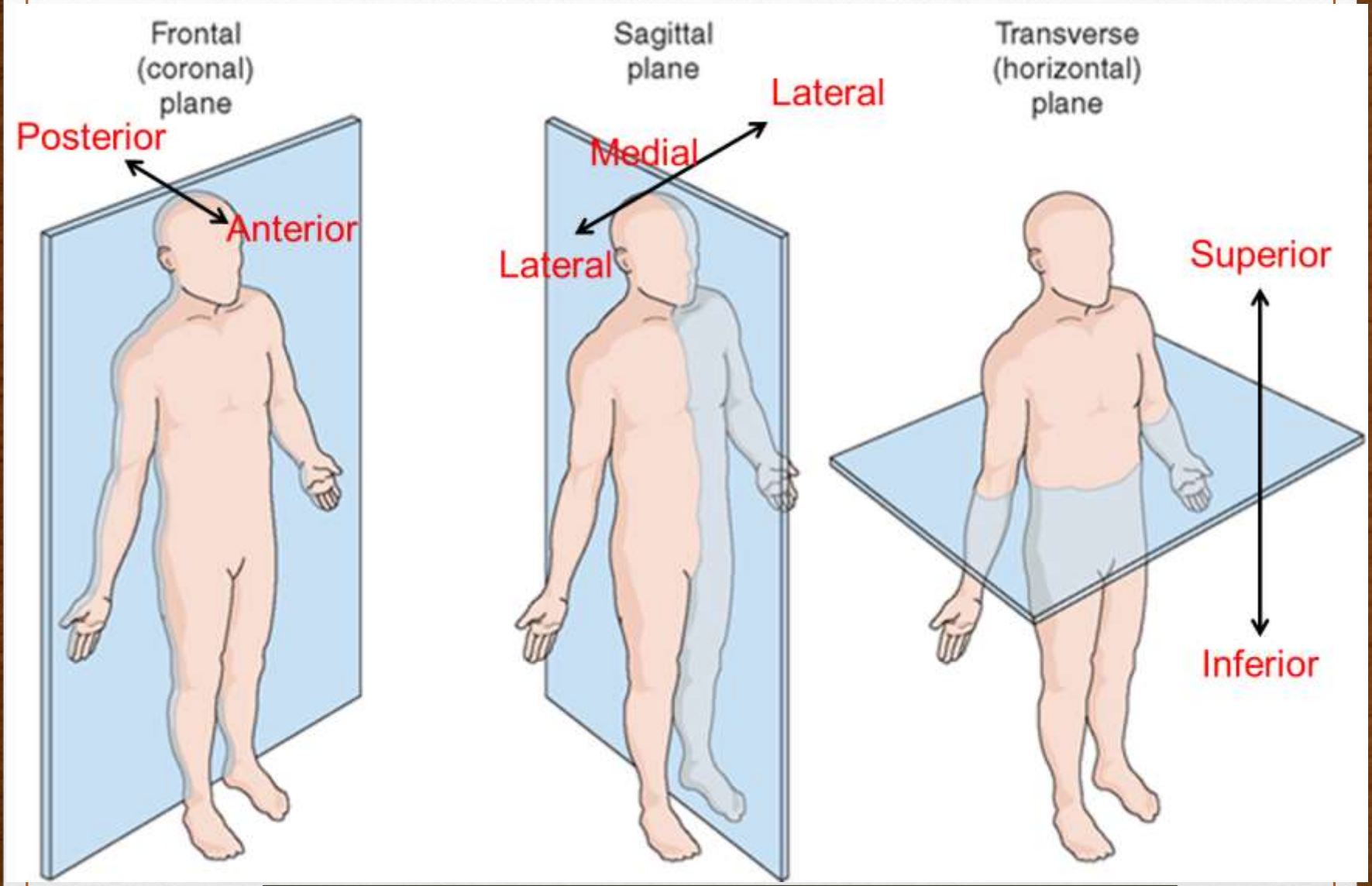

Proximal – close to the trunk
Distal – away from the trunk

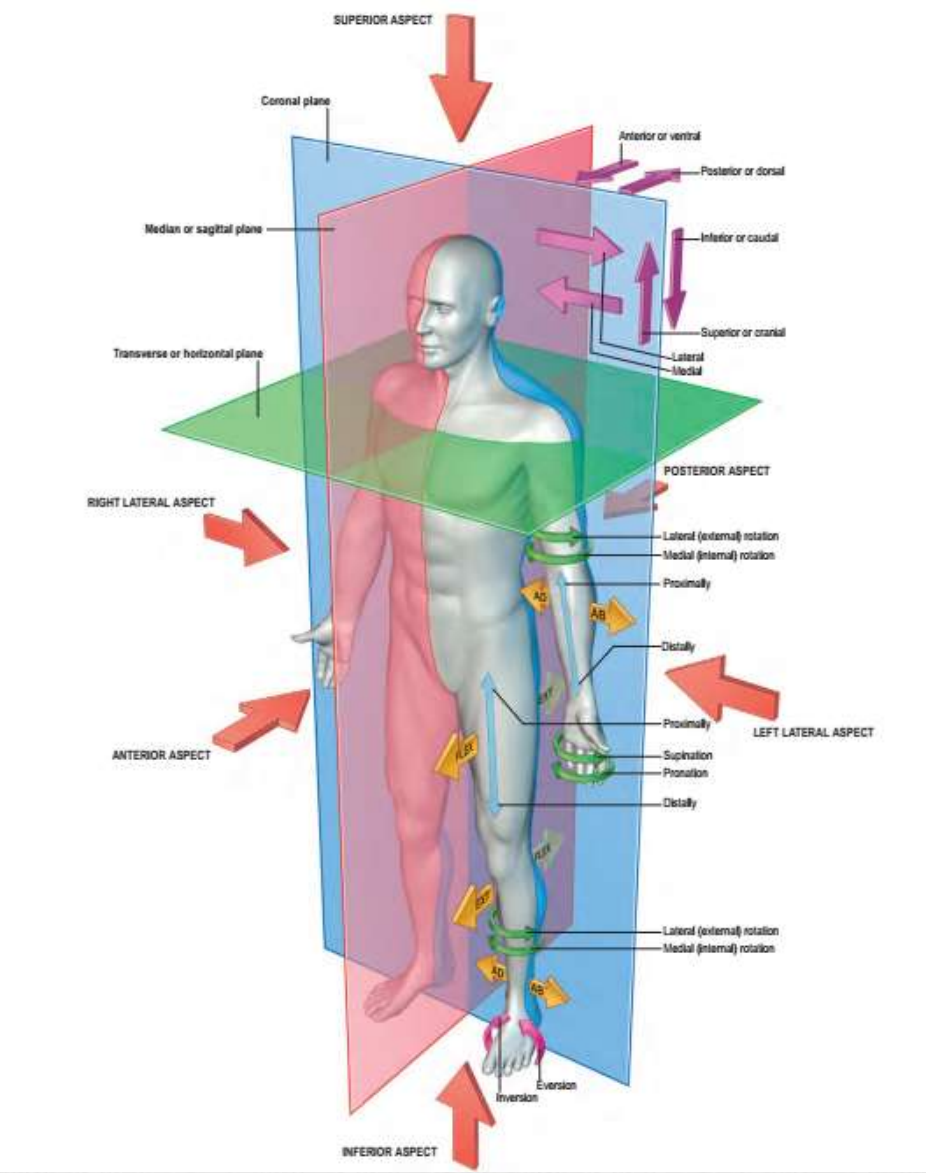
SUPERIOR ASPECT
Coronal plane
Anterior or ventral
Posterior or dorsal
Median or sagittal plane
Inferior or caudal
Superior or cranial
Lateral
Medial
Transverse or horizontal plane
POSTERIOR ASPECT
RIGHT LATERAL ASPECT
Lateral (external) rotation
Medial (internal) rotation
Proximally
AD
AB
Distally
EXT
Proximally
LEFT LATERAL ASPECT
ANTERIOR ASPECT
FLEX
Supination
Pronation
Distally
FLEX
EXT
Lateral (external) rotation
Medial (internal) rotation
AD
AB
Eversion
Inversion
INFERIOR ASPECT

Latin	English
Os	Bone
Caput	Head
Capitulum	Head (diminutive)
Corpus	Body
Collum	Neck
Incisura	Notch
Sulcus	Groove
Foramen	Foramen
Fossa/fovea	Fossa (depression)
Facies	Surface
Arcus	Arch
Processus	Processus
Tuber	Tuber
Tuberculum	Tuberculum (single small elevation)
Tuberositas	Tuberosity
Extremitas	Extremity (=end)

Where to find books, atlases and handbook?

https://yadi.sk/d/8NUtJVyibTPoG

Файлы › ДЛЯ СТУДЕНТОВ учебники, лекции ›

По названию

For foreign studens

ANATOMY	52	2	08.02.2016	16:32	
HISTOLOGY	0	33	08.02.2016	16:35	
Neuroanatomy	0	24	14.05.2016	10:32	
Path.anatomy	4	10	05.09.2017	14:05	
Pathophysiology	2	13	04.09.2017	11:46	
Research methods	3	6	01.12.2015	14:22	
Video manuals	0	10	20.10.2015	23:27	
CRITERIA OF STUDENTS' ANSWER EVALUATION.docx	0	46	26.02.2016	15:57	15,7 КБ

Textbook of Human Anatomy: for medical students.

1. I.V. Gaivoronskiy
2. M.R. Sapin et al., vol.1

Order of words

Noun + Adjective

Examples:

- Foramen vertebrale
- Facies articularis superior
- Tuberositas deltoidea

Adjective + Noun

Examples:

- Vertebral foramen
- Superior articular facet
- Deltoid tuberosity

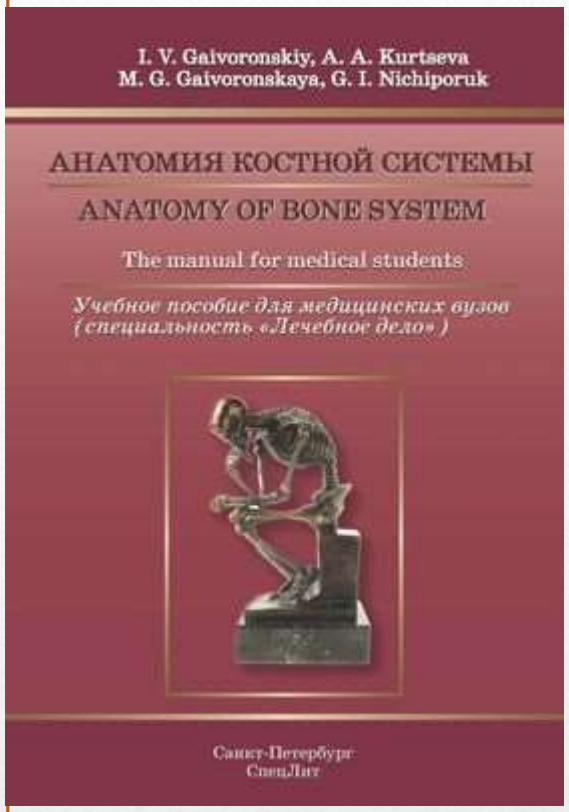

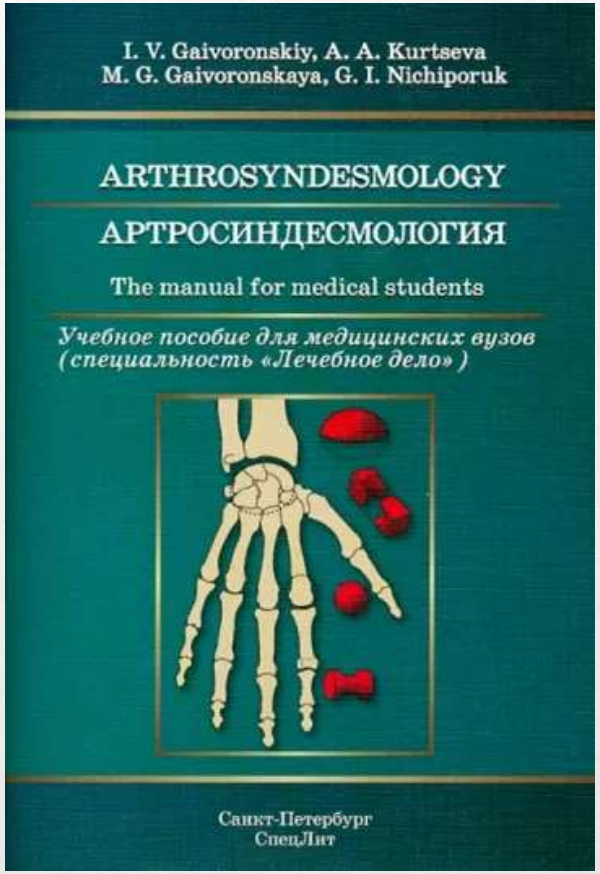



ANATOMY
I semester

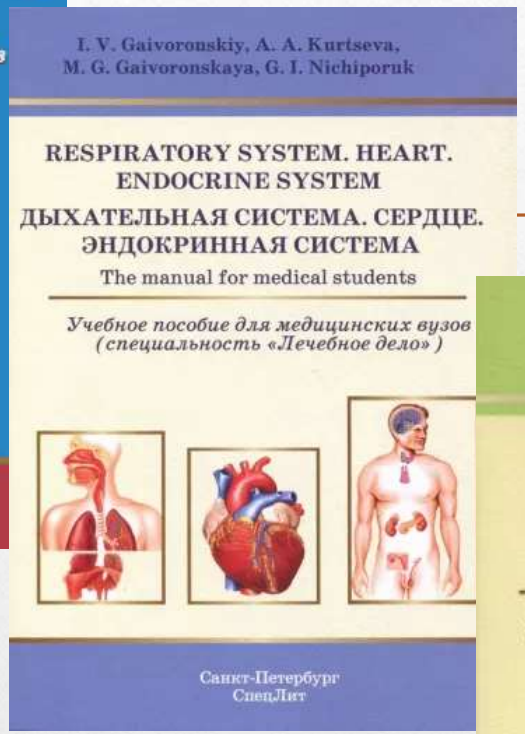

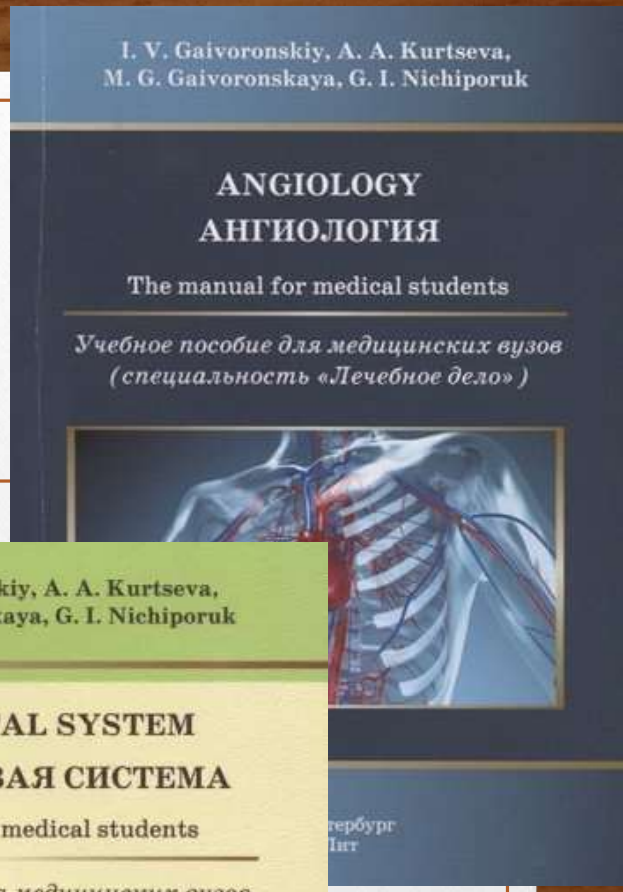

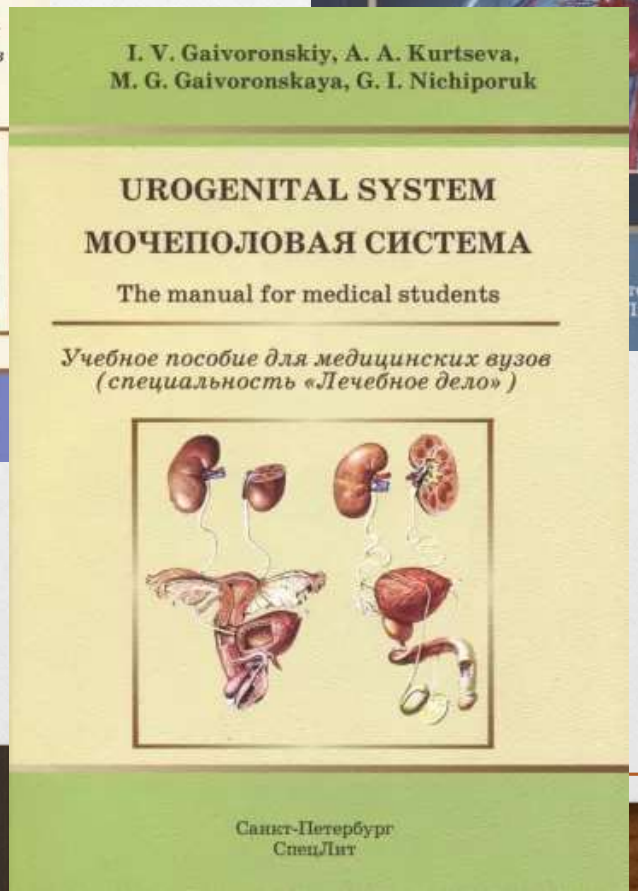

ANATOMY
II semester

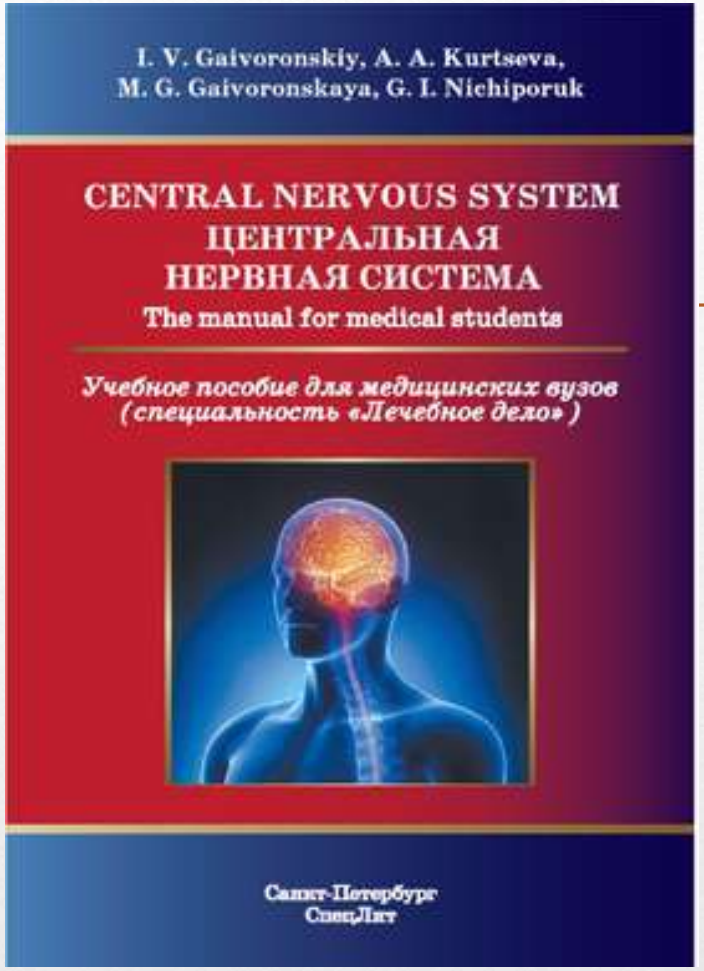

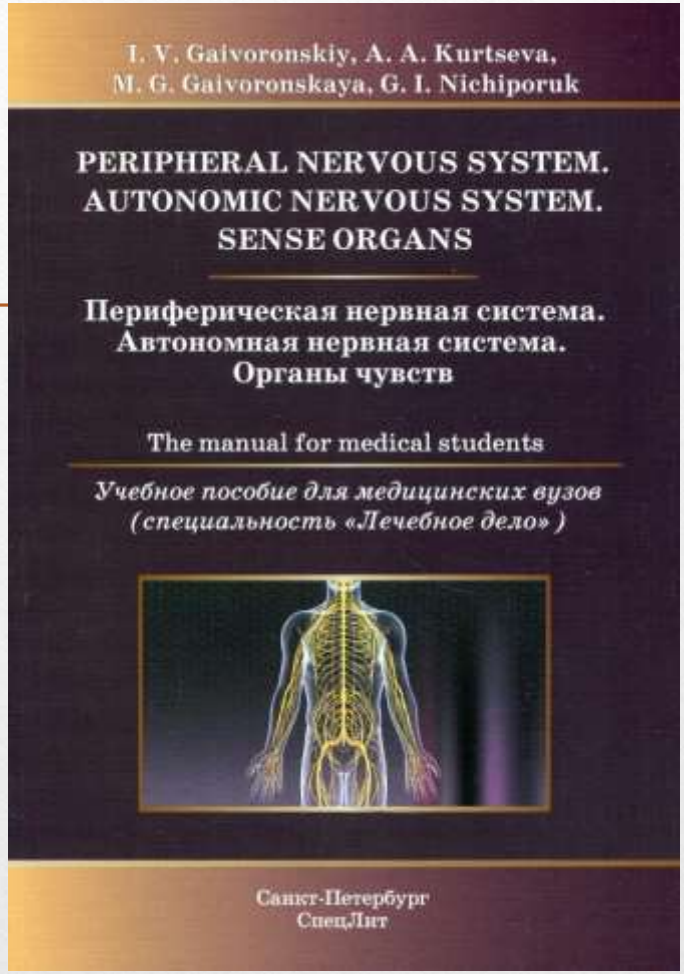

NEUROANATOMY
II course

While working with preparations, medical students should:

- Wear white coat;
- Wear gloves (both hands);
- Gather your hair (if they are long)

Rating system

#	Topic	Points
	Semester 1	
1	Classes (average from all classes)	0-5
2	Control 1 - Osteology	0-9
3	Writtten control (Joints)	0-4
4	Control 2 - Myology	0-9
	Semester 2	
5	Classes (average from all classes)	0-5
6	Control 3 - Splanchnology	0-9
7	Control 4 – Cardiovascular system	0-9
	Total for both semesters	0-50
	Exam (end of the second semester)	**28-50**
	Total for the Anatomy	**56-100**

- **Minimal points for exam – 28!**
- **Minimal points for the whole subject – 56!**

- **86-100 – excellent**
- **71-85 – good**
- **56-70- satisfied**
- **Less than 56 – unsatisfied**

During semester Controls and unsatisfactory grades are not retaken.

Controls can be taken only ONCE during the semester.

Before every control – card with 10 anatomic preparations **in Latin**

1. corpus vertebrae
2. cingulum membri superioris
3. incisura ulnaris
4. ala ossis ilii
5. caput fibulae
6. facies externa squamae frontalis
7. canalis nervi hypoglossi
8. fossula petrosa
9. corpus maxillae
10. collum mandibulae

Kazan Federal UNIVERSITY

www.kpfu.ru

Department of Morphology and General Pathology