Age-Dependent Differential Staining of Fibrin in Blood Clots and Thrombi

Rafael R. Khismatullin, Asia Z. Shakirova, John W. Weisel & Rustem I. Litvinov

BioNanoScience

ISSN 2191-1630
Volume 10
Number 1

BioNanoSci. (2020) 10:370-374
DOI 10.1007/s12668-019-00701-4

BioNanoScience (2020) 10:370–374
https://doi.org/10.1007/s12668-019-00701-4

Age-Dependent Differential Staining of Fibrin in Blood Clots and Thrombi

Rafael R. Khismatullin[1] · Asia Z. Shakirova[1] · John W. Weisel[2] · Rustem I. Litvinov[2,3]

Published online: 4 December 2019

Abstract
It has been known for a long time that histologically fibrin can be visualized as a fibrous structure of variable colors, even when stained with the same histochemical technique. The reason for this phenomenon called metachromasia remains unknown. We hypothesized that metachromasia is related to fibrin structural maturation and age. To establish a link between the color of fibrin in histological preparations and the age of blood clots and thrombi. Using the Picro-Mallory staining technique, we studied changes in fibrin color in histological preparations of in vitro human plasma clots at various time points within 48 h after formation in the absence and presence of platelets. Also, we used the same stain to visualize fibrin in histological sections of ex vivo human cerebral thrombi of different maturity. In histological preparations of plasma clots formed either in the absence or in the presence of platelets, fibrin was distinctively polychromic depending on the time lapse between formation and chemical fixation of the clot. In the 30-min and 6-h clots ("young" clots), fibrin was red; after 6–12 h ("mature" clots), fibrin was purple or violet; at 24 or 48 h ("old" clots), fibrin was blue. In thrombi removed from cerebral arteries of ischemic stroke patients, fibrin also stained differentially. The colors generally corresponded to the time from the onset of stroke to the time of intravital thrombectomy, such that fibrin in the younger thrombi was red or purple, while in the older thrombi, fibrin was blue. The Picro-Mallory stain can be used to assess histologically the maturity of fibrin in blood clots, thrombi, and thrombotic emboli based on the age-dependent differential staining of fibrin. A color-temporal scale is proposed that can help pathologists to estimate the age of a blood clot or thrombus.

Keywords Fibrin · Blood clotting · Thrombosis · Histochemistry · Picro-Mallory

1 Introduction

Fibrin, along with platelets and erythrocytes, comprises a major component of blood clots and thrombi, but it can be also found in tissues as a result of blood extravasation or transudation. As an extracellular structure, fibrin can be visualized histologically using a number of dyes that stain fibrin with different colors. The most common protocols used to reveal fibrin in tissue sections and distinguish it from other fibrous structures, such as collagen, are based on Martius-Scarlet-Blue (MSB), Masson, Picro-Mallory, and Obadiah methods. Importantly, fibrin can become apparent with distinct colors, shades, and intensities, even when it is stained with the same dye or histochemical technique, a phenomenon known as metachromasia. Metachromasia has been attributed to a number of causes, including the quality and duration of sample fixation, fibrin density, and its co-localization with other structures [1, 2]. We hypothesized that one reason for metachromasia is related to the structural maturity of fibrin and that this differential fibrin staining can provide a basis for estimating the age of a blood clot or thrombus. To test our hypothesis, we used in vitro blood clots of different known ages to show that the color does change with age, and also correlated the colors of fibrin in histological preparations with the age of ex vivo thrombi extracted from patients. Based on the results obtained, we have developed a color-temporal scale that can help to

✉ Rafael R. Khismatullin
rafael.khismatullin@gmail.com

[1] Department of General Pathology, Kazan State Medical University, Kazan, Russian Federation

[2] Department of Cell and Developmental Biology, University of Pennsylvania School of Medicine, Philadelphia, PA, USA

[3] Institute of Fundamental Medicine and Biology, Kazan Federal University, Kazan, Russian Federation

establish histopathological criteria for how old is an intravital blood clot or thrombus or thrombotic embolus.

2 Materials and Methods

2.1 Plasma Clots

Venous blood was drawn into 3.8% sodium citrate (9:1, v/v) from 3 healthy aspirin-free donors with written consent. Platelet-rich plasma (PRP) was obtained by centrifugation of citrated blood at 200*g* for 10 min at room temperature. Platelet-poor plasma (PPP) was obtained by centrifugation of PRP at 2000*g* for 10 min at room temperature. Five-milliliter samples of PPP and PRP from an individual donor were supplemented with 0.05% sodium azide to prevent bacterial growth and activated in parallel by addition of 1 U/ml human thrombin and 2 mM $CaCl_2$ (both final concentration). One-milliliter aliquots of each activated plasma sample were quickly transferred to five Eppendorf tubes pre-coated with a thin layer of 4% Triton X-100 in phosphate-buffered saline to prevent attachment of fibrin to the walls during clotting and clot contraction in PRP. The clots were allowed to form and kept at 37 °C for 30 min, 6 h, 12 h, 24 h, or 48 h, after which one PRP clot and one PPP clot at each time point were mixed with the fixative and processed for histochemical analysis.

2.2 Cerebral Thrombi

Thrombi were extracted by aspiration from cerebral arteries of ischemic stroke patients in accordance with permission of the Ethical Committee of the Interregional Clinical Diagnostic Center, Kazan, Russia. The thrombi were immediately rinsed with saline, fixed, and later processed for histochemical examination. Representative thrombi from 3 patients are presented here.

Patient 1 A 80-year-old male with atherothrombotic stroke and focal ischemia in the basal ganglia. At the time of thrombectomy performed 2 h after the onset of stroke, the patient received an antiplatelet medication (aspirin) and a thrombolytic agent (actilyse). NIHSS (National Institutes of Health Stroke Scale used to assess the severity of a stroke) was 21 points both on admission and on the 7th day of disease.

Patient 2 A 69-year-old female with atherothrombotic stroke and focal brain ischemia. At the time of thrombectomy performed 5 h after the onset of stroke, the patient did not receive anticoagulants or antiplatelet drugs, but was treated with actilyse. NIHSS was 7 points on admission and 11 points on the 7th day of disease.

Patient 3 A 73-year-old male with cardioembolic stroke and severe brain ischemia. At the time of thrombectomy performed over 24 h after the onset of stroke, the patient was treated with aspirin and actilyse. NIHSS was 18 points on admission and 43 points on the 7th day of disease, suggesting that the thrombectomy was performed after damage of the brain tissue occurred.

2.3 Histology

All samples analyzed (plasma clots and thrombi) were fixed in 10% neutral buffered formalin, washed in water, cut into pieces, then dehydrated in ascending concentrations of ethanol (50%, 70%, 80%, 100%) and xylene, and embedded in paraffin. Four-micrometer-thick sections were stained with a Picro-Mallory histochemical kit (BioVitrum, Russia) using a standard protocol and analyzed using a microscope, Zeiss AxioImager Z2.

The Picro-Mallory stain (also known as Lendrum's stain) is modification of Mallory trichrome stain that involves the addition of picric acid. Picro-Mallory is usually utilized in histology to reveal components of connective tissue. It uses three dyes (aniline blue, acid fuchsine, and orange G) with staining selectivity and intensity depending on the affinity between the dyes and fibrin. Fibrin may be red due to the interaction of fuchsine with acidic groups in the structure of fibrin; it may become blue because of the basic properties of aniline blue.

3 Results

During careful examination of a series of > 30 histological preparations of human cerebral thrombi stained with the standard Picro-Mallory technique, we realized that fibrin had quite variable colors, most of which were shades of red, purple, or blue. To see if the variability in colors could be due to fibrin aging, we performed model experiments, in which human plasma clots were formed in vitro and allowed to mature for up to 48 h at 37 °C followed by fixation, sectioning, and staining using the Picro-Mallory protocol. To consider possible effects related to the presence of activated platelets, we compared PRP and PPP clots from the same blood samples obtained from independent donors. The results were qualitatively consistent and the characteristic data are presented in Fig. 1.

Both in PPP and PRP clots, fibrin was visualized as a fibrous structure that had a red, purple, or blue color, depending on the time of clot formation. In the clots stained after 30 min and 6 h of maturation ("young" clots), fibrin was red (Fig. 1a, b, f, g). In the clots kept for 6–12 h ("mature" clots), fibrin was stained purple or violet (Fig. 1a, b, c, h, i). In "old" clots incubated for 24 or 48 h, fibrin stained blue (Fig. 1c, d, e, h, i, j). Notably, the color saturation of fibrin in PRP and PPP

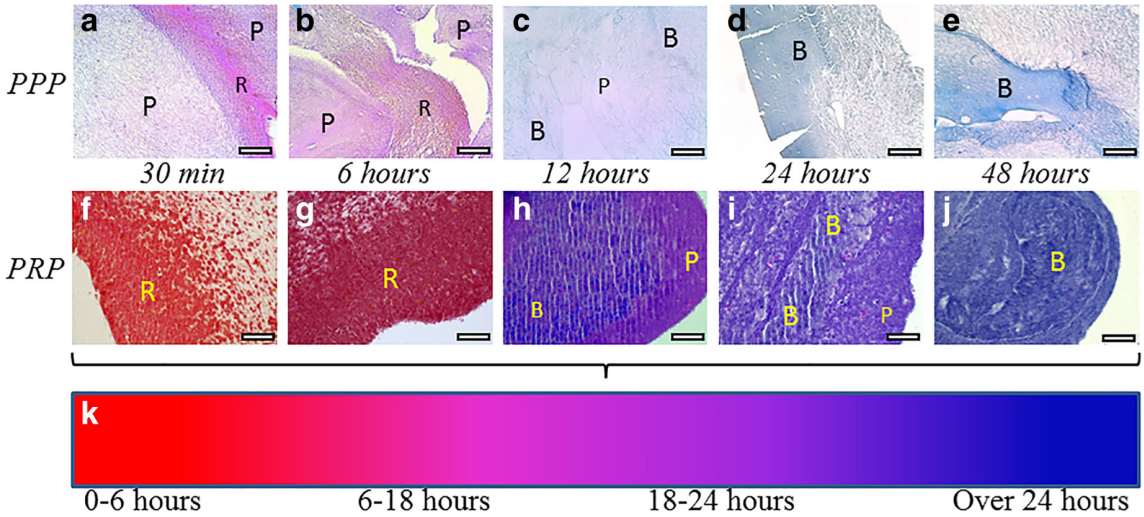

Fig. 1 Metachromasia of fibrin in PPP (**a**–**e**) and PRP (**f**–**j**) clots at different time points after formation up to 48 h. Before 6 h after formation, fibrin stained in *red* (R); in 6–18 h after formation, fibrin stained *purple* (P); over 24 h after formation, fibrin stained *blue* (B). Picro-Mallory stain, × 400, magnification bars = 50 μm

clots was substantially different, such that PRP clots had a much greater intensity, although the colors at the corresponding time points were the same. This difference can most likely be attributed to platelet-induced compaction or contraction of the PRP clots [3]. The results of these model experiments were generalized by creating a color-temporal scale that showed metachromasia of fibrin as a function of clot aging (Fig. 1k). Quantification of fibrin colors stained with Picro-Mallory is hardly feasible due to variability in staining that depends strongly on the quality and source of reagents used as well as on the diversity of protocols applied.

Next, we tested if the correspondence revealed between the color and age of fibrin was applicable to intravital thrombi of various ages. The age of a thrombus was estimated as the time from the onset of clinical symptoms of stroke to the time of thrombus extraction and fixation. Indeed, there was a general correlation between the color of fibrin in histological preparations and the time lapse between formation of the thrombus and thrombectomy. Three representative images are shown in Fig. 1. The red-colored fibrin (Fig. 2a) was found in a thrombus retrieved about 2 h after formation. The purple-colored fibrin (Fig. 2b) was present in a thrombus formed about 5 h before it was removed and fixed. The blue-colored fibrin (Fig. 2c) was present in a thrombus that was residing in a vessel for over 24 h. Importantly, in the latter case, the severity of stroke (NIHSS) increased progressively during the course of disease, consistent with the prolonged thrombotic obstruction of a cerebral artery followed by irreversible damage of the brain.

4 Discussion

Prior studies have suggested that age-dependent structural changes and properties of thrombi can provide insights into etiology and the course of thrombosis; predict possible outcomes, including successful recanalization following both fibrinolysis and mechanical thrombectomy; and assist in the development of new treatment modalities [4–9]. For a long time, histological examination of thrombi was the main source of information about the composition and structure of thrombi, although this information was largely postmortem and retrospective. With development of thrombectomy, especially interventional procedures in coronary and cerebral arteries, pathologists gained access to the morphology of intravital ex vivo thrombi that provided ample new and clinically important data [10, 11]. In addition to histological and histochemical examination, new imaging techniques have emerged with a much higher resolution and degree of information [12]. However, classical light microscopy of blood clots and thrombi still has the potential to provide clinically important information, not accessible with other techniques.

Here, based on histochemical examination of in vitro fibrin clots of various ages, we have created a color scale (Fig. 1) that can be used to evaluate the approximate age of thrombi stained with a standard Picro-Mallory protocol. This scale roughly corresponds to the time-dependent polychromy of fibrin in thrombi (Fig. 2), reflecting the age of a thrombus and its age-related properties, such as mechanical and fibrinolytic stability

The variations of fibrin colors revealed could not be due to changes in fixation or other technical conditions, because in the in vitro model experiments, clots were processed simultaneously using the same reagents and standard conditions. The presence of other fibrous structures, such as collagen, that could potentially mimic fibrin was also excluded, because none was present. Therefore, the observed metachromasia of fibrin can be attributed solely to the time from formation of fibrin to the time of fixation. Based on what is known about

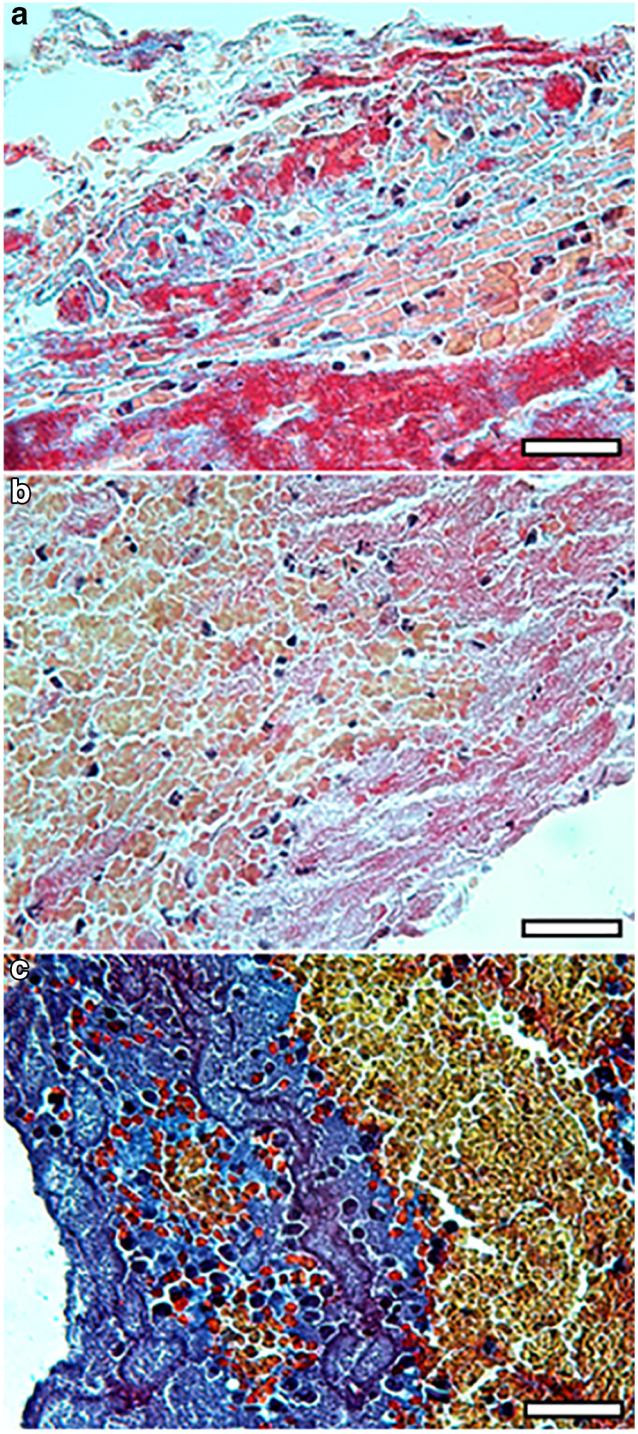

Fig. 2 Fibrin polychromy in histological preparations of ex vivo cerebral thrombi. Fibrin is stained red (**a**), purple (**b**), or blue (**c**) depending on the thrombus age. Picro-Mallory stain, × 400, magnification bar = 50 μm

the structural changes that fibrin undergoes after clot formation and the timing of these alterations, the most likely mechanism underlying the time-dependent differential staining is covalent cross-linking of fibrin induced by the plasma transglutaminase, factor XIIIa, although other unknown changes could be occurring. Following fast dimerization of the γ chains in fibrin, factor XIIIa catalyzes slow cross-linking between the unstructured C-terminal portions of α chains known as the αC regions [13, 14]. This reaction known to proceed in thrombi for hours [15] results in formation of large αC polymers [16] that may impart to fibrin fibers new chemical properties, such as differential staining. Direct correlation between the content of αC polymers and fibrin metachromasia is worth further investigation.

Our finding may have important practical implications, because the traditional H&E staining does not provide any information on thrombus age. Remarkably, even with more sophisticated and specific staining techniques than Picro-Mallory, there are no studies on age-dependent fibrin location/structure within a thrombus, which may be related to clinical outcomes of thrombotic states or planning treatments (recanalization, thrombotic embolism, etc.) [17–21]. It is especially important and useful to know about fibrin age to assess the success of thrombolytic or other therapies [22]. In addition, the results of this study can be useful in pathomorphological and forensic practice to compare the degree of maturity in different parts of the same thrombus (parietal and floating parts), as well as identify the primary thrombus in a case of thromboembolism.

5 Conclusion

Based on the age-dependent differential staining of fibrin with Picro-Mallory stain, a color scale has been developed that can help to assess histologically the age of blood clots, thrombi, and thrombotic emboli.

Funding Information The work was supported by NIH grants HL135254, HL116330 grant RFBR 19-015-00075 and the Program for Competitive Growth at Kazan Federal University.

Compliance with Ethical Standards

Conflict of Interest The authors declare that they have no conflict of interest.

Research Involving Humans and Animals Statement None

Informed Consent None

References

1. Lendrum, A. C., Fraser, D. S., Slidders, W., et al. (1962). Studies on the character and staining of fibrin. *Journal of Clinical Pathology, 15*(5), 401–413.
2. Cattaneo, C., Andreola, S., Marinelli, E., et al. (2010). The detection of microscopic markers of hemorrhaging and wound age on dry bone: a pilot study. *The American Journal of Forensic Medicine and Pathology, 31*(1), 22–26.

3. Tutwiler, V., Wang, H., Litvinov, R. I., et al. (2017). Interplay of platelet contractility and elasticity of fibrin/erythrocytes in blood clot retraction. *Biophysical Journal, 112*(4), 714–723.
4. Mehta, B. P., & Nogueira, R. G. (2012). Should clot composition affect choice of endovascular therapy? *Neurology., 79*(1), 63–67.
5. Liebeskind, D. S., Sanossian, N., Yong, W. H., et al. (2011). CT and MRI early vessel signs reflect clot composition in acute stroke. *Stroke., 42*, 1237–1243.
6. Froehler, M. T., Tateshima, S., Duckwiler, G., et al. (2013). The hyperdense vessel sign on CT predicts successful recanalization with the Merci device in acute ischemic stroke. *Journal of NeuroInterventional Surgery, 5*(4), 289–293.
7. Vidmar, J., Serša, I., Kralj, E., et al. (2015). Unsuccessful percutaneous mechanical thrombectomy in fibrin-rich high-risk pulmonary thromboembolism. *Thrombosis Journal, 13*(1), 30.
8. Silvain, J., Collet, J. P., Nagaswami, C., et al. (2011). Composition of coronary thrombus in acute myocardial infarction. *Journal of the American College of Cardiology, 57*(12), 1359–1367.
9. Silvain, J., Collet, J. P., Guedeney, P., et al. (2017). Thrombus composition in sudden cardiac death from acute myocardial infarction. *Resuscitation., 113*, 108–114.
10. Simons, N., Mitchell, P., Dowling, R., et al. (2014). Thrombus composition in acute ischemic stroke: a histopathological study of thrombus extracted by endovascular retrieval. *Journal of Neuroradiology, 42*(2), 86–92.
11. Maegerlein, C., Friedrich, B., Berndt, M., et al. (2018). Impact of histological thrombus composition on preinterventional thrombus migration in patients with acute occlusions of the middle cerebral artery. *Interventional Neuroradiology, 24*(1), 70–75.
12. Autar, A. S. A., Hund, H. M., Ramlal, S. A., et al. (2018). High-resolution imaging of interaction between thrombus and stent-retriever in patients with acute ischemic stroke. *Journal of the American Heart Association, 7*(13), e008563.
13. Muszbek, L., Bereczky, Z., Bagoly, Z., et al. (2011). Factor XIII: a coagulation factor with multiple plasmatic and cellular functions. *Physiological Reviews, 91*(3), 931–972.
14. Bowley, S. R., & Lord, S. T. (2009). Fibrinogen variant BβD432A has normal polymerization but does not bind knob "B". *Blood., 113*(18), 4425–4430.
15. Muszbek, L., Bereczky, Z., Bagoly, Z., et al. (2010). Factor XIII and atherothrombotic diseases. *Seminars in Thrombosis and Hemostasis, 36*(1), 18–33.
16. Tsurupa, G., Mahid, A., Veklich, Y., et al. (2011). Structure, stability, and interaction of fibrin αC-domain polymers. *Biochemistry., 50*(37), 8028–8037.
17. Boeckh-Behrens, T., Schubert, M., Förschler, A., et al. (2016). The impact of histological clot composition in embolic stroke. *Clinical Neuroradiology, 26*(2), 189–197.
18. Niesten, J. M., van der Schaaf, I. C., van Dam, L., et al. (2014). Histopathologic composition of cerebral thrombi of acute stroke patients is correlated with stroke subtype and thrombus attenuation. *PLoS One, 9*(2), e88882.
19. Singh, P., Doostkam, S., Reinhard, M., et al. (2013). Immunohistochemical analysis of thrombi retrieved during treatment of acute ischemic stroke: does stent-retriever cause intimal damage? *Stroke., 44*(6), 1720–1722.
20. Sallustio, F., Arnò, N., Di Legge, S., et al. (2015). Histological features of intracranial thrombo-emboli predict response to endovascular therapy for acute ischemic stroke. *Journal of Neurological Disorders & Stroke, 3*(3), 1105.
21. Marder, V. J., Chute, D. J., Starkman, S., et al. (2006). Analysis of thrombi retrieved from cerebral arteries of patients with acute ischemic stroke. *Stroke., 37*(8), 2086–2093.
22. Staessens, S., Denorme, F., François, O., et al. (2019). Structural analysis of ischemic stroke thrombi: histological indications for therapy resistance. *Haematologica*. https://doi.org/10.3324/haematol.2019.219881 [Epub ahead of print].