NERVOUS SYSTEM

- The neurvous system senses, interprets, and responds to changes in the environment.
- Two types of cells makes this possible:
  - the **neuron**
  - and the supporting cells **("glial cells**").

Neuron

- **Neurons** are special cells which change state based on electrical currents and past history.

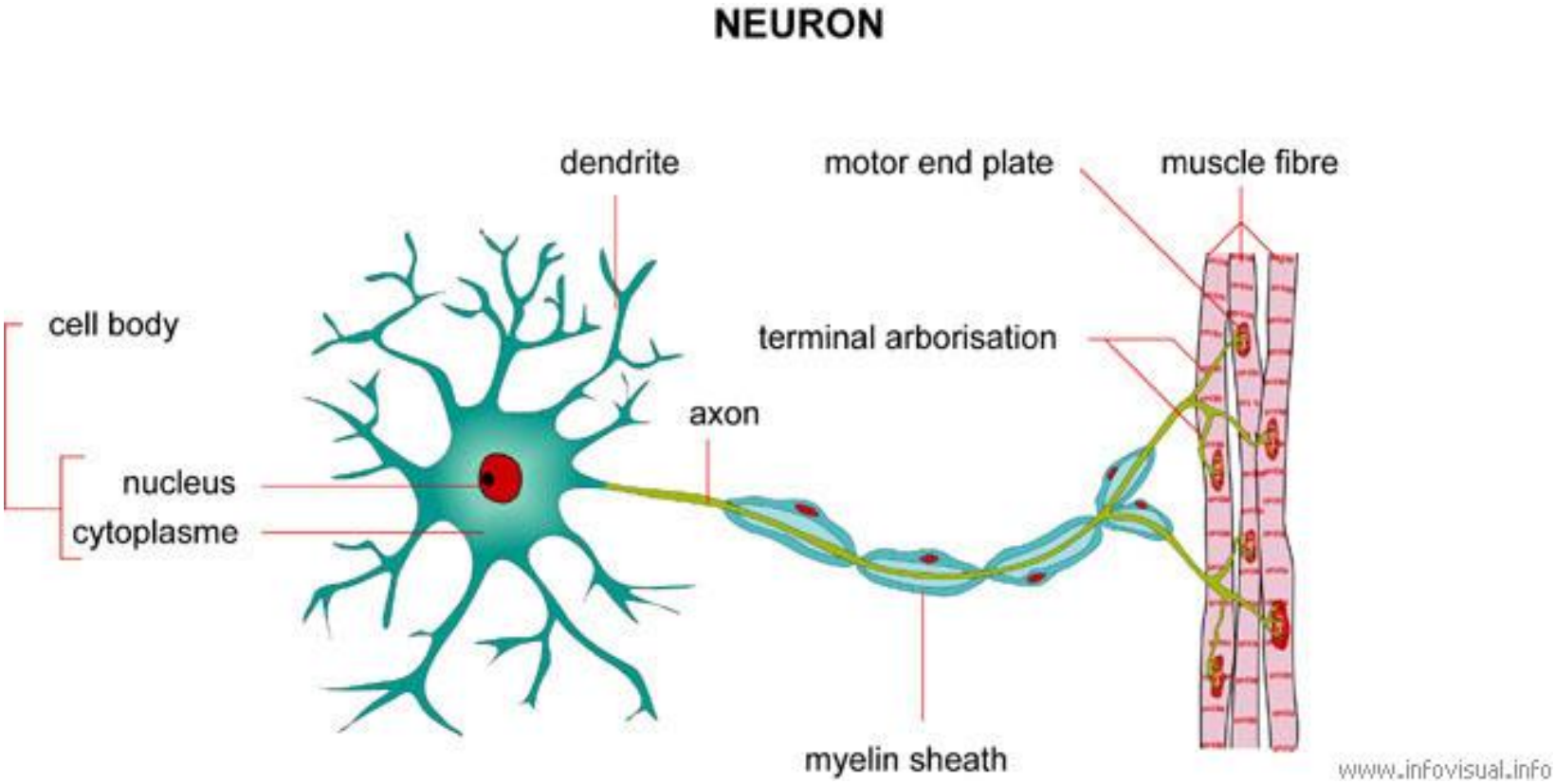

- They are often referred to by their function, shape, or position relative to each other.
  - **Motor neuron,**
  - **Sensory neuron,**
  - **Interneuron**

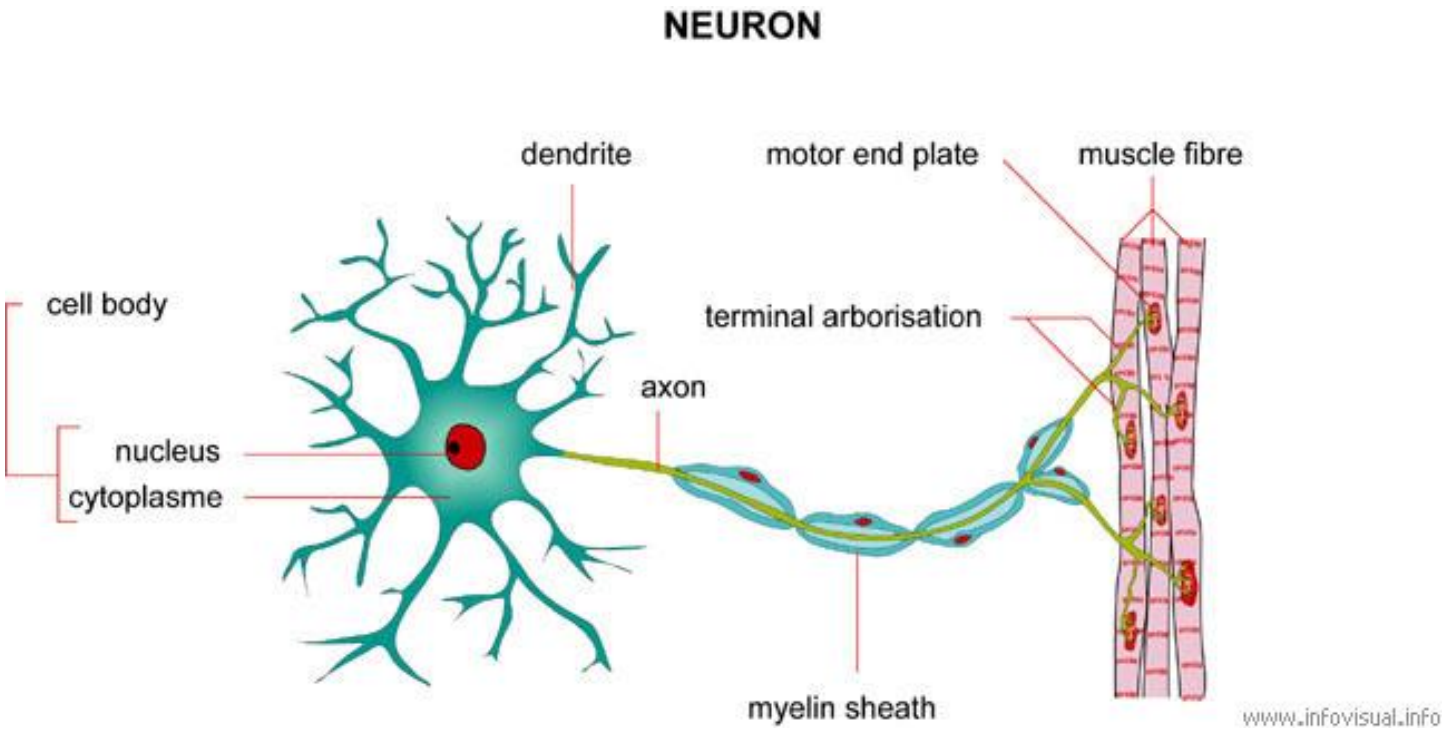

- **Dendrites** and **cell body** receive input from sensory receptors and other neurons. They take the form of *graded potentials*

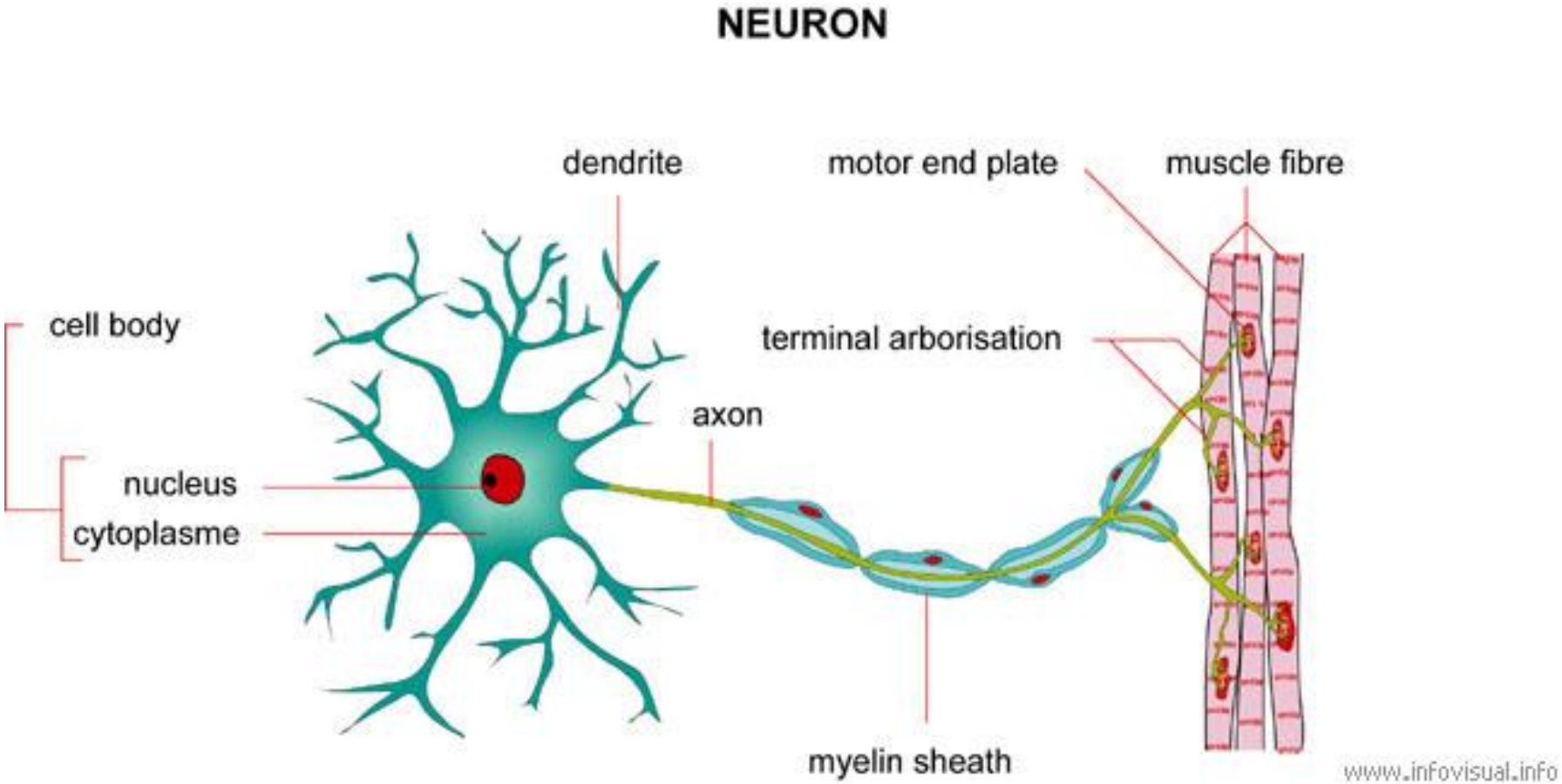

- The **cell body** integrates input which may lead **the axon** to transmit an *action potential*.

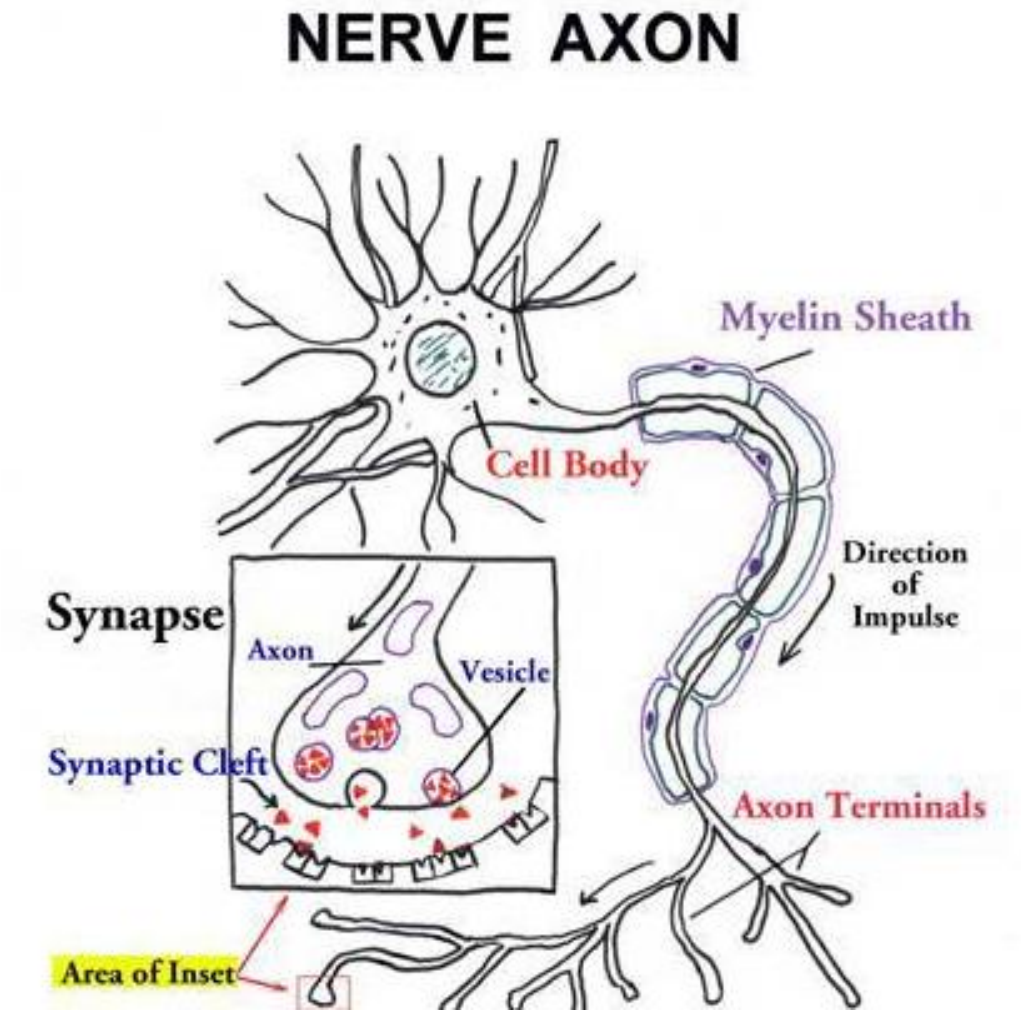

- The **synaptic knobs** release neurotransmitters on other neurons or effector organs (e.g. muscles)

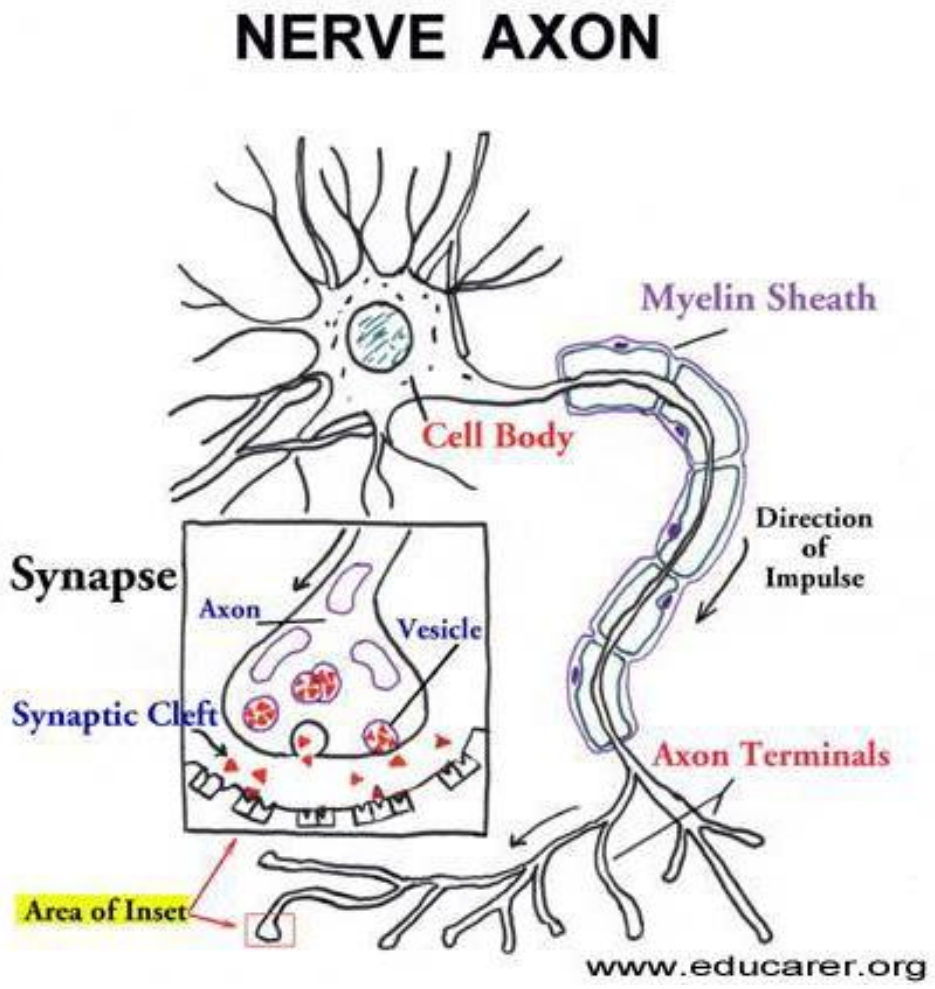

- Since neurons have highly specialized shapes, they rely on helper cells to assist metabolic activities.
- These are the supporting cells, or ***glial cells (glia = "glue")***.

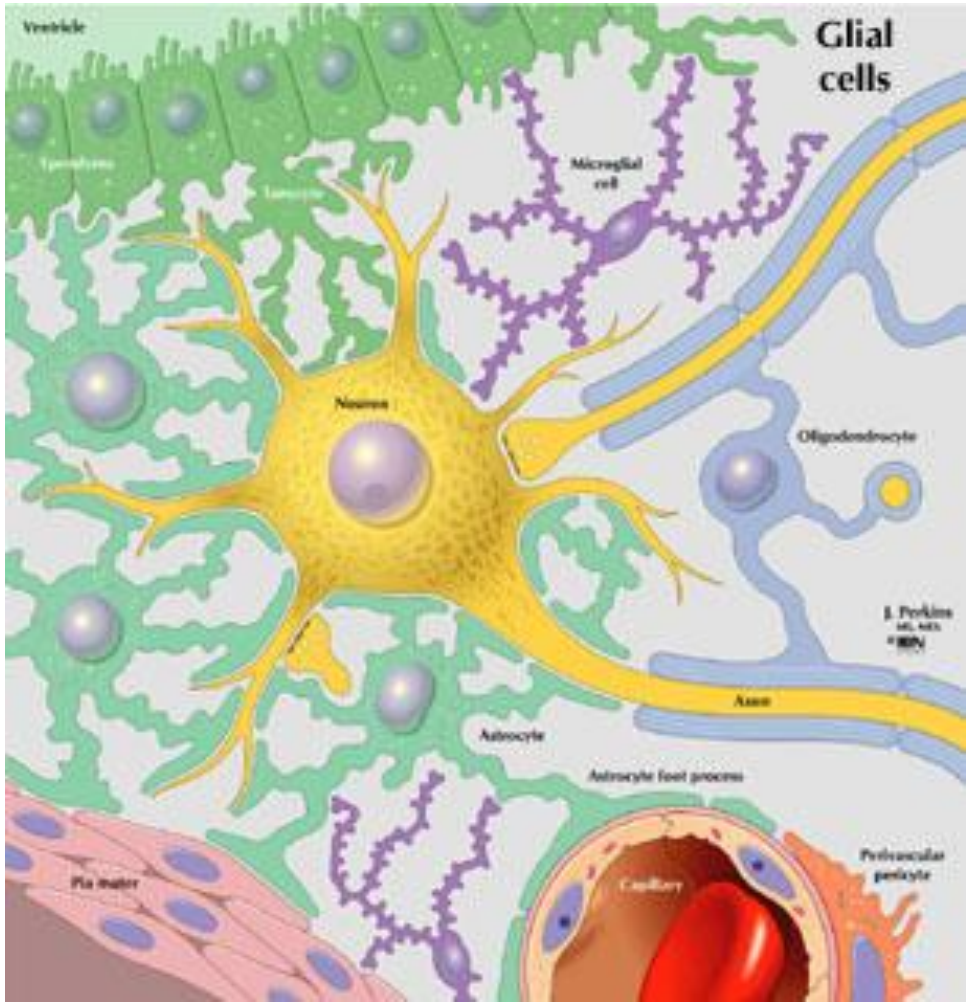

- Axons often make use of ***Schwann Cells*** (glia) to increase transmission speeds.

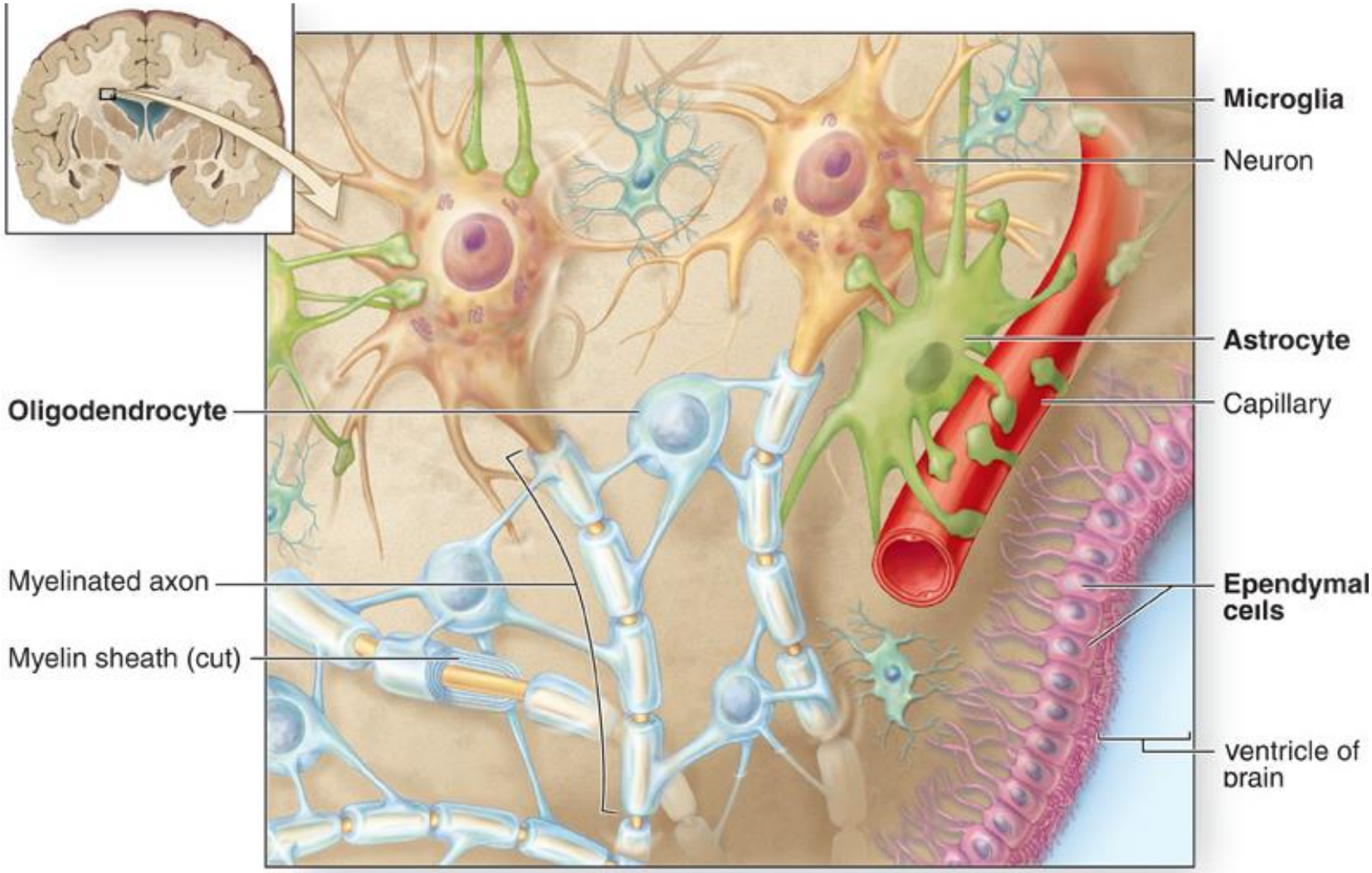

General terminology

- **Central nervous system (CNS) -** consists of brain and spinal cord

- **Peripheral nervous system (PNS) -** nerves that connect CNS to peripheral sense organs and muscles

General terminology

Somatic nervous system - PNS nerves and ganglia that convey input from the sense organs or outputs involved in voluntary activity

- **Autonomic nervous system** - PNS nerves and ganglia that regulate involuntary functions such as blood pressure or heart beat

Nerves - bundles of multiple axons

- **afferent** nerves carry sensory information from sense organs towards CNS
- **efferent** nerves carry information away from CNS to muscles, glands, and sometimes to sense organs
- **mixed** nerves contains both afferent and efferent fibers

- **Ganglion** - an aggregation of cell bodies and neurites surrounded by a connective tissue sheath

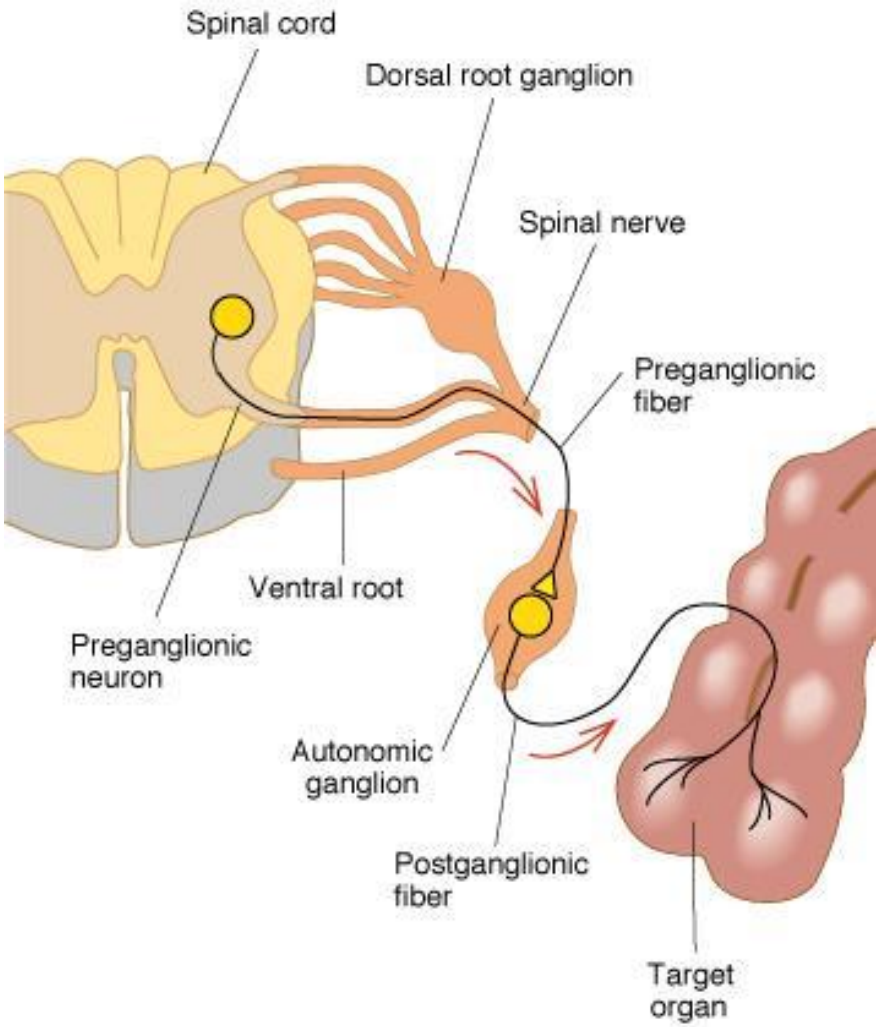

Central nervous system (CNS) - consists of brain and spinal cord

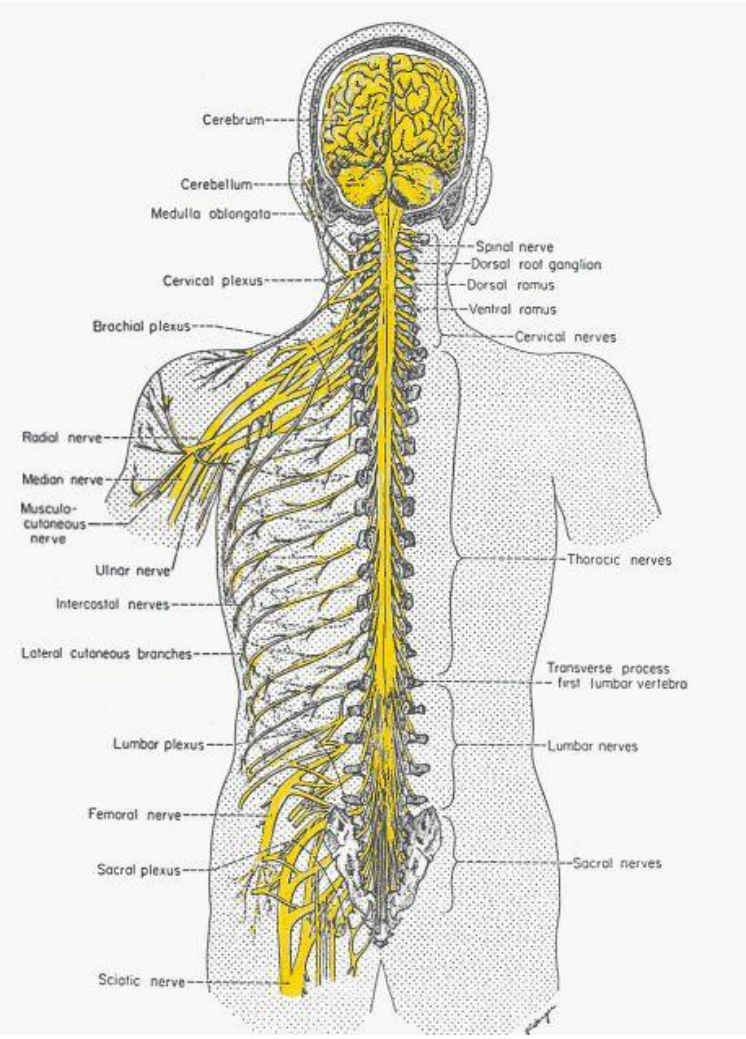

The spinal cord

- Lies in dorsally situated vertebral column from base of brain to pelvis
- The spinal cord extends from the foramen magnum to the second lumbar vertabrae.
- It is covered with ***pia***, ***arachnoid,*** and ***dura mater*** and is bathed in cerebrospinal fluid which is also found in the central spinal canal.

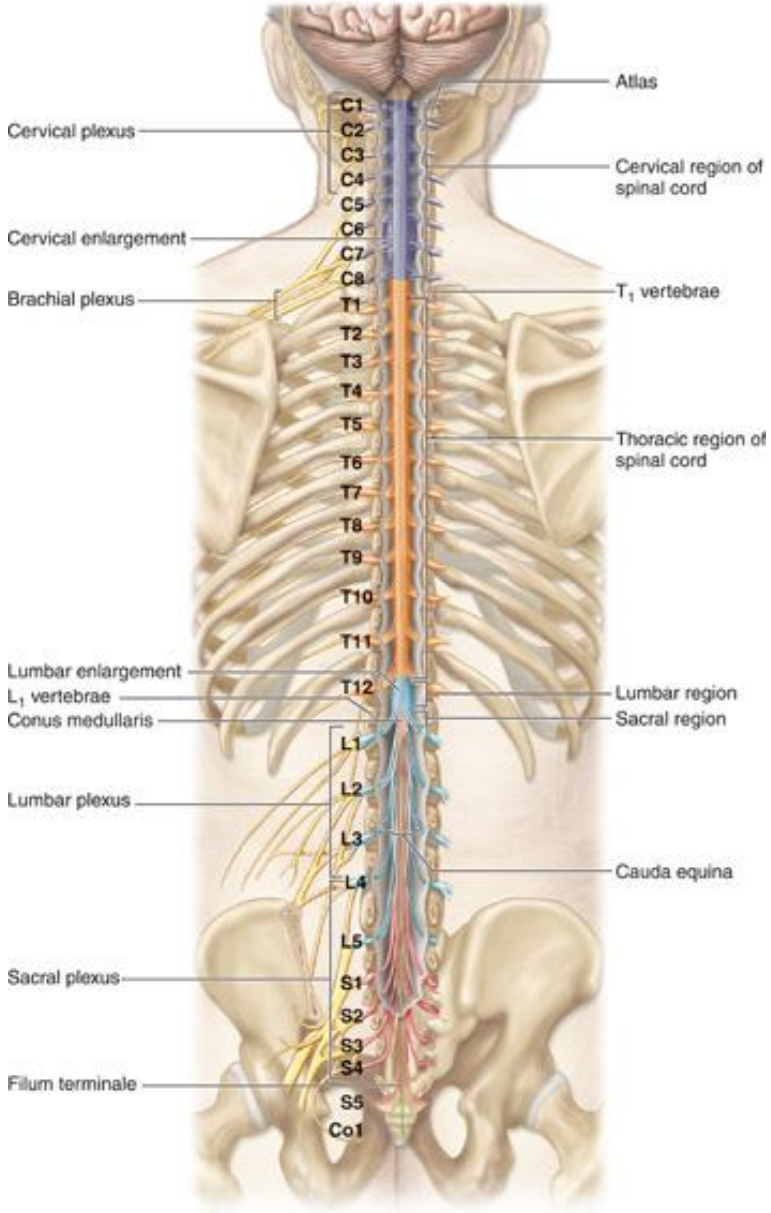

(a) Posterior view

- **White matter** - ***Bundles of myelinated axons, that mostly connect parts of the cord with one another or with the brain***
- Because of myelin, they look white (ergo **"white matter**")

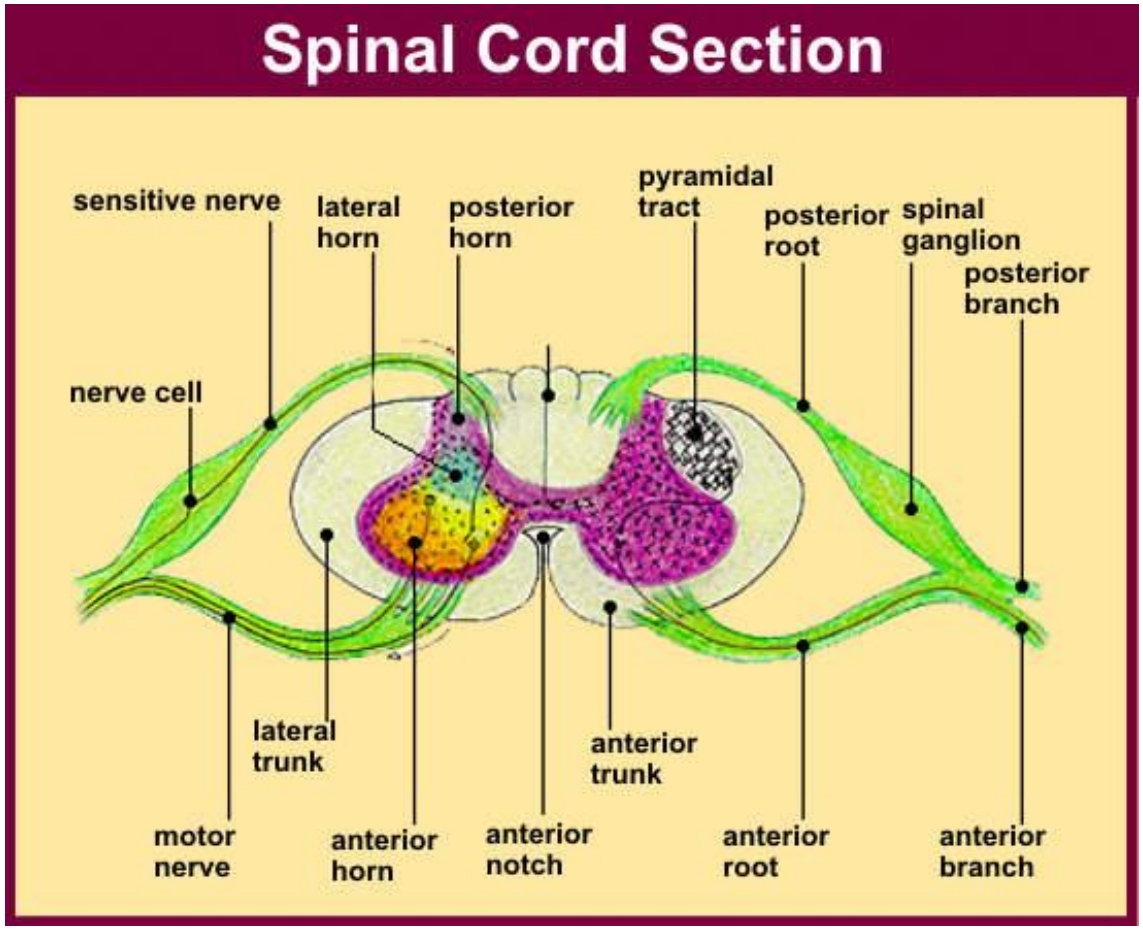

- Axons of different neurons tend to travel together in bunches. These are called **nerves** (PNS) or **tracts** (CNS).
- each tract or column carries specific sensory or motor information
- **dorsally** located columns generally carry **sensory** information up to brain
- **ventrally** located columns generally carry **motor** commands down from brain

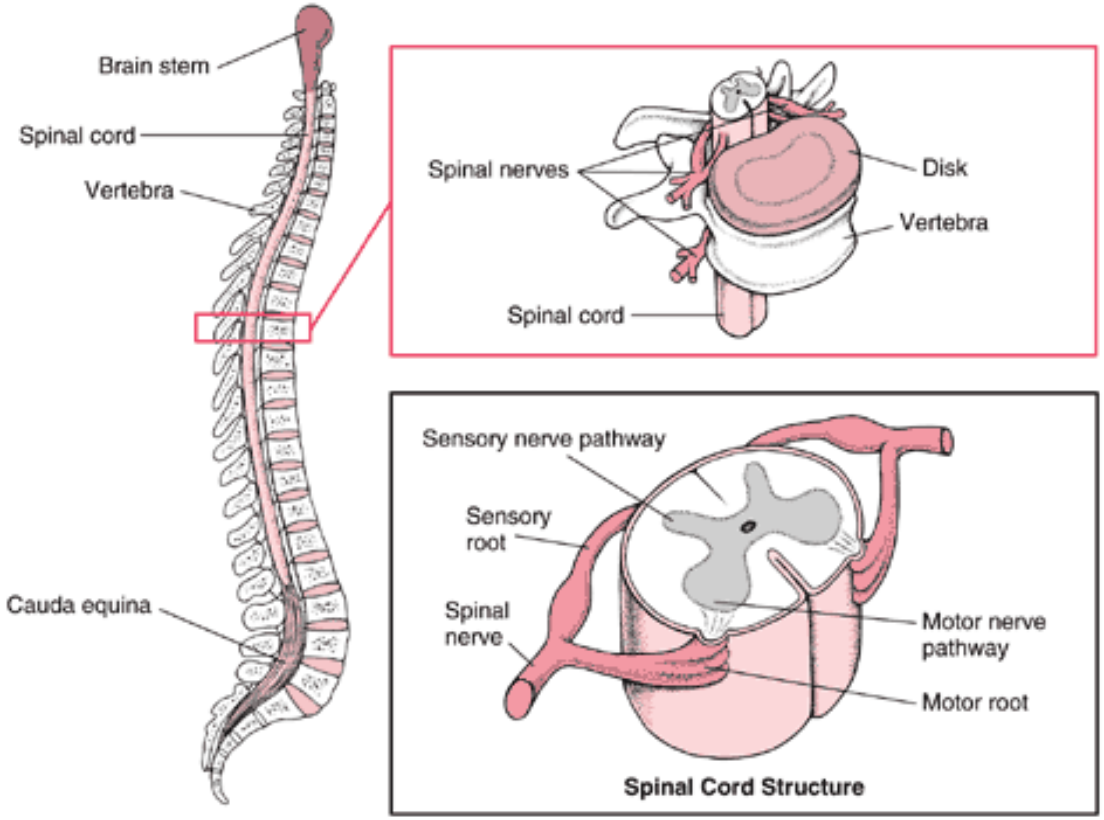
Brain stem
Spinal cord
Vertebra
Cauda equina
Spinal nerves
Disk
Vertebra
Spinal cord
Sensory nerve pathway
Sensory root
Spinal nerve
Motor nerve pathway
Motor root
Spinal Cord Structure

- **Gray matter** - ***Cell bodies, dendrites, and synapses***
- Cell bodies (and dendrites)
- Since they don't have myelin, they tend to look grey ("**grey matter**")

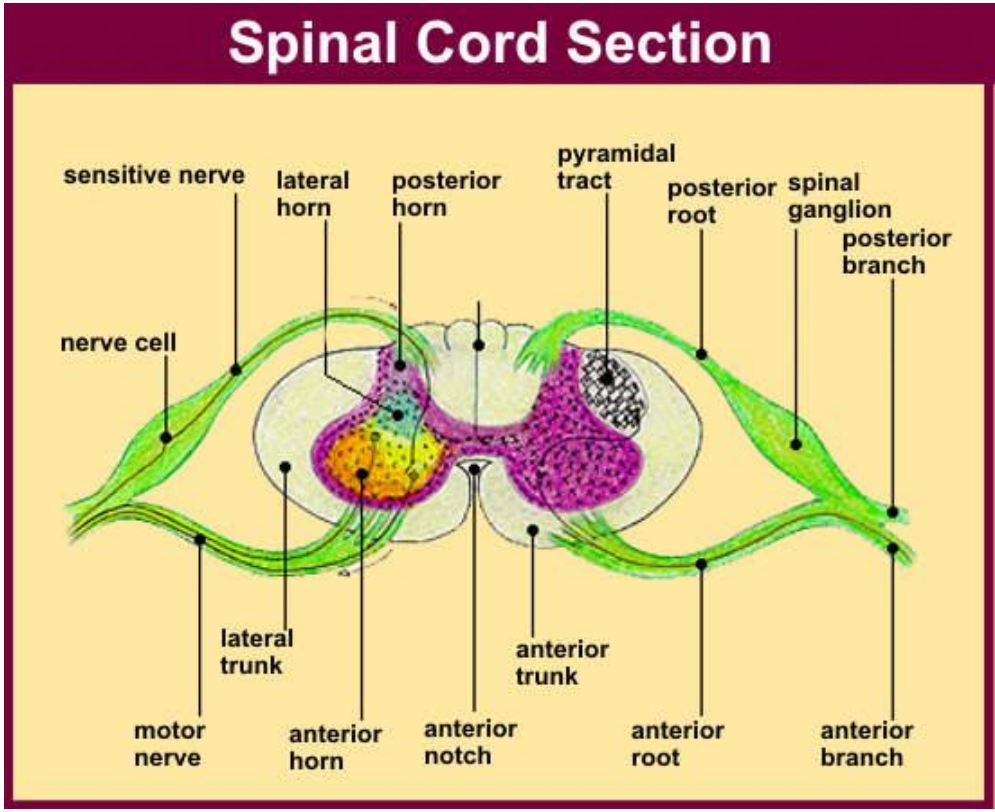

- ventral horns contain motor neuron cell bodies, innervate somatic muscles
- dorsal horn contains neurons that receive sensory input
- cell bodies of sensory neurons located in dorsal root ganglion
- lateral regions of gray matter contain cell bodies of efferent autonomic neurons

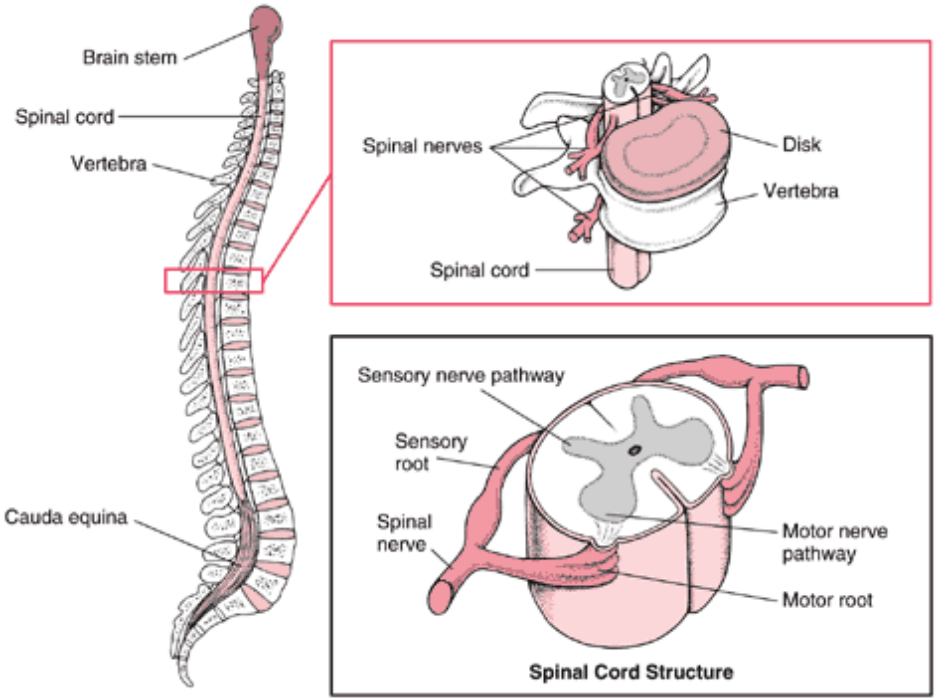

Spinal nerves

- most sensory information enters cord via dorsal roots
- each dorsal root contains swelling, dorsal root ganglion, containing cell bodies of sensory neurons
- motor information leaves the cord via ventral roots
- dorsal and ventral roots fuse close to spinal cord to form spinal nerves, run out between vertebrae of backbone
- spinal nerves are identified and numbered according to the part of the cord they serve and position in that part

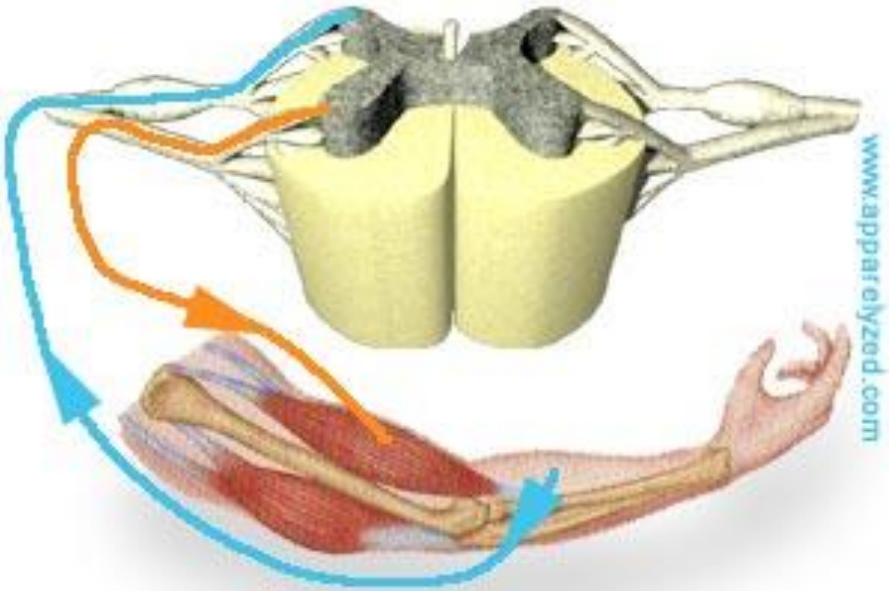

The vertebrate brain

- Gray matter at outer surface of brain-cortex
- Fiber tracts, white matter underneath
- Nuclei distinct collections of cell bodies

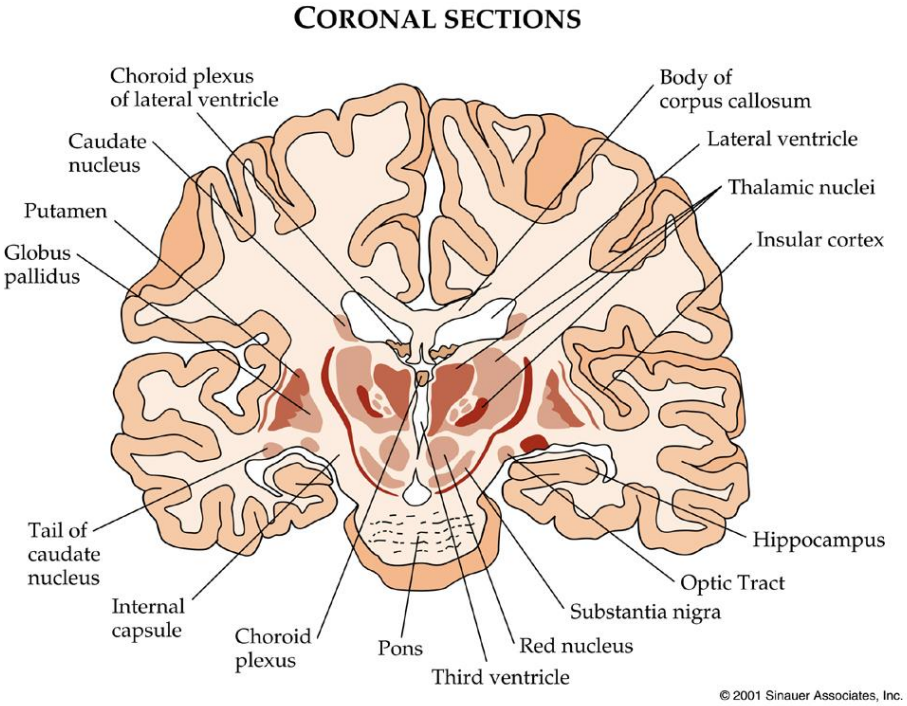

The meninges

- The brain is enclosed by three membranes - **the meninges** - within the skull.
- The tough, outer ***dura mater*** and the thin ***pia mater*** sandwich the ***arachnoid mater***.

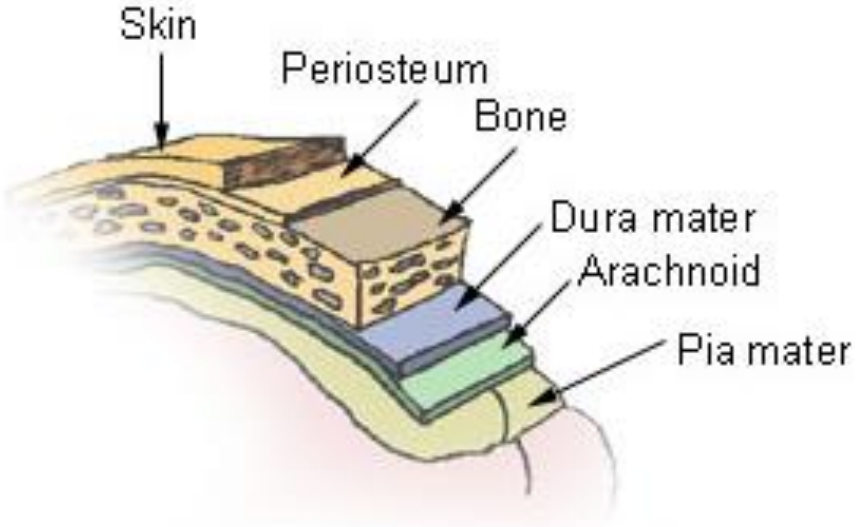

Meninges of the CNS

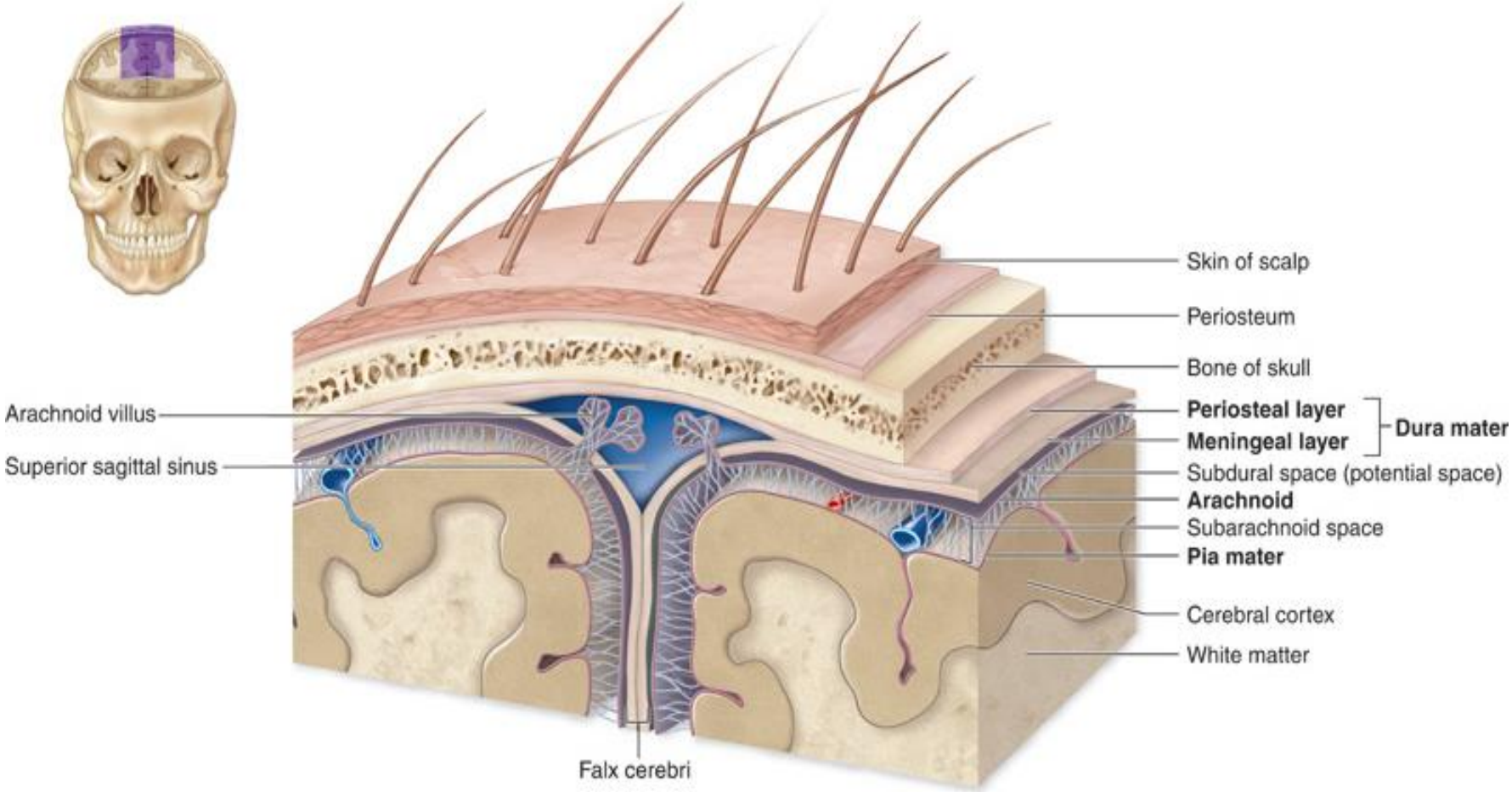
Skin of scalp
Periosteum
Bone of skull
Arachnoid villus
Periosteal layer
Meningeal layer
Dura mater
Superior sagittal sinus
Subdural space (potential space)
Arachnoid
Subarachnoid space
Pia mater
Cerebral cortex
White matter
Falx cerebri

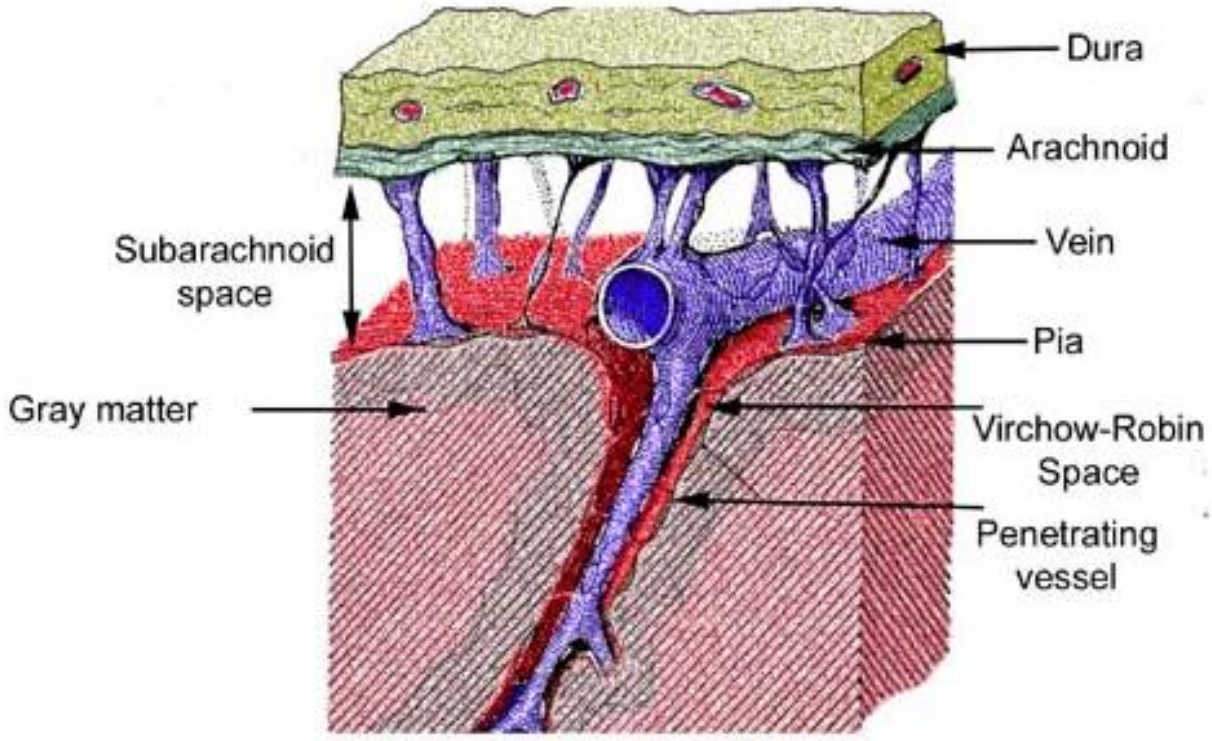

- The arachnoid mater is pierced by many channels and allows the circulation of the cerebro-spinal fluid around the surface and to the ventricles and central canal of the spinal cord.

Brain Development

Neural tube

- Brain and spinal cord originate from neural tube that runs length of embryo

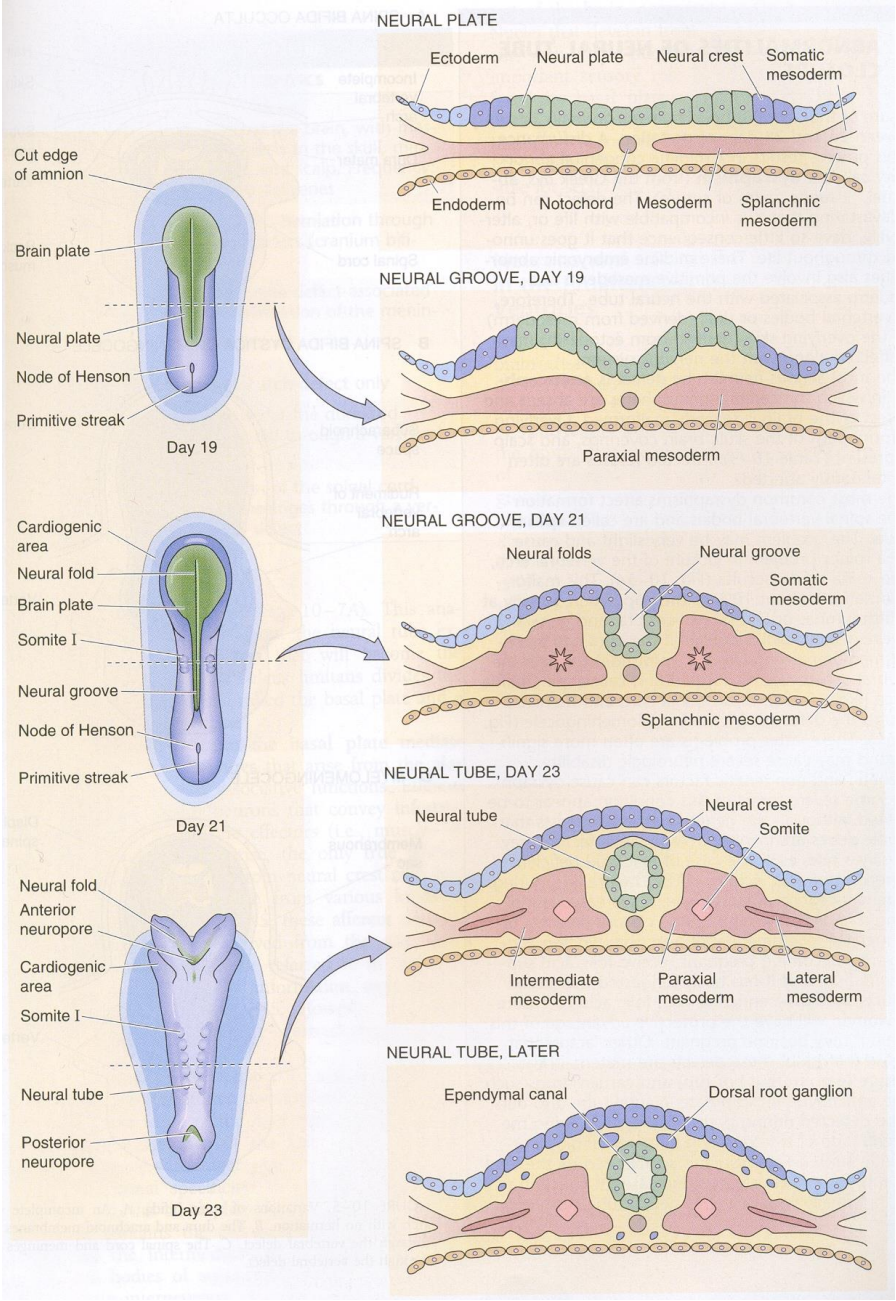

- Anterior end of neural tube develops three distinct lobes-
  - forebrain (prosencephalon),
  - midbrain (mesencephalon)
  - hindbrain (rhombencephalon)

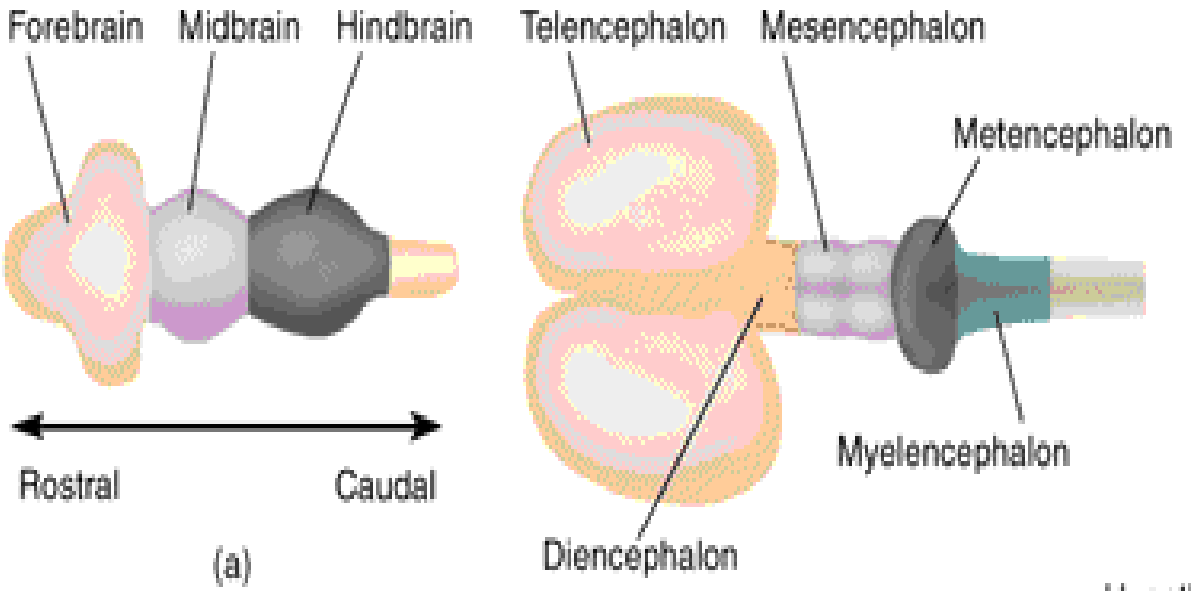

Forebrain becomes telencephalon and diencephalon

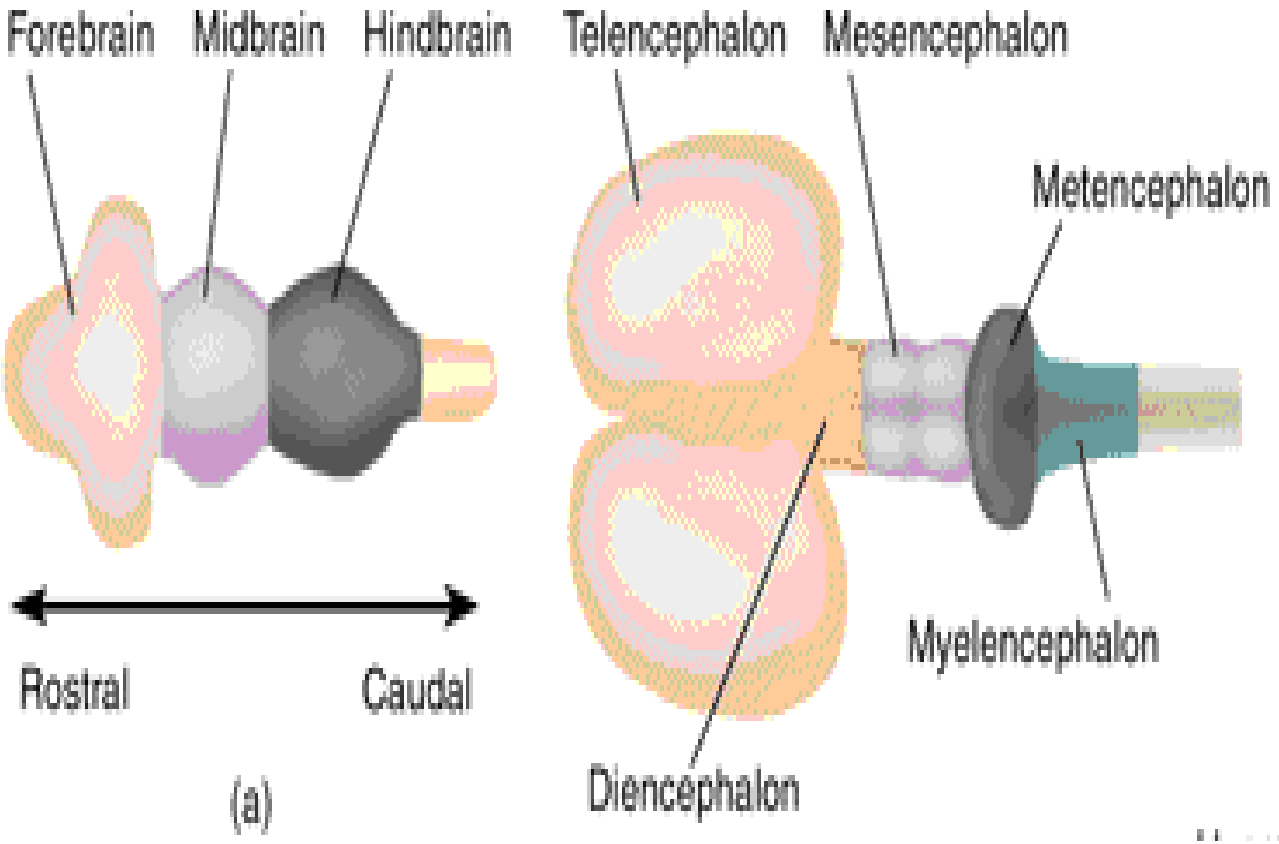

Hindbrain becomes cerebellum, pons, and medulla oblongata

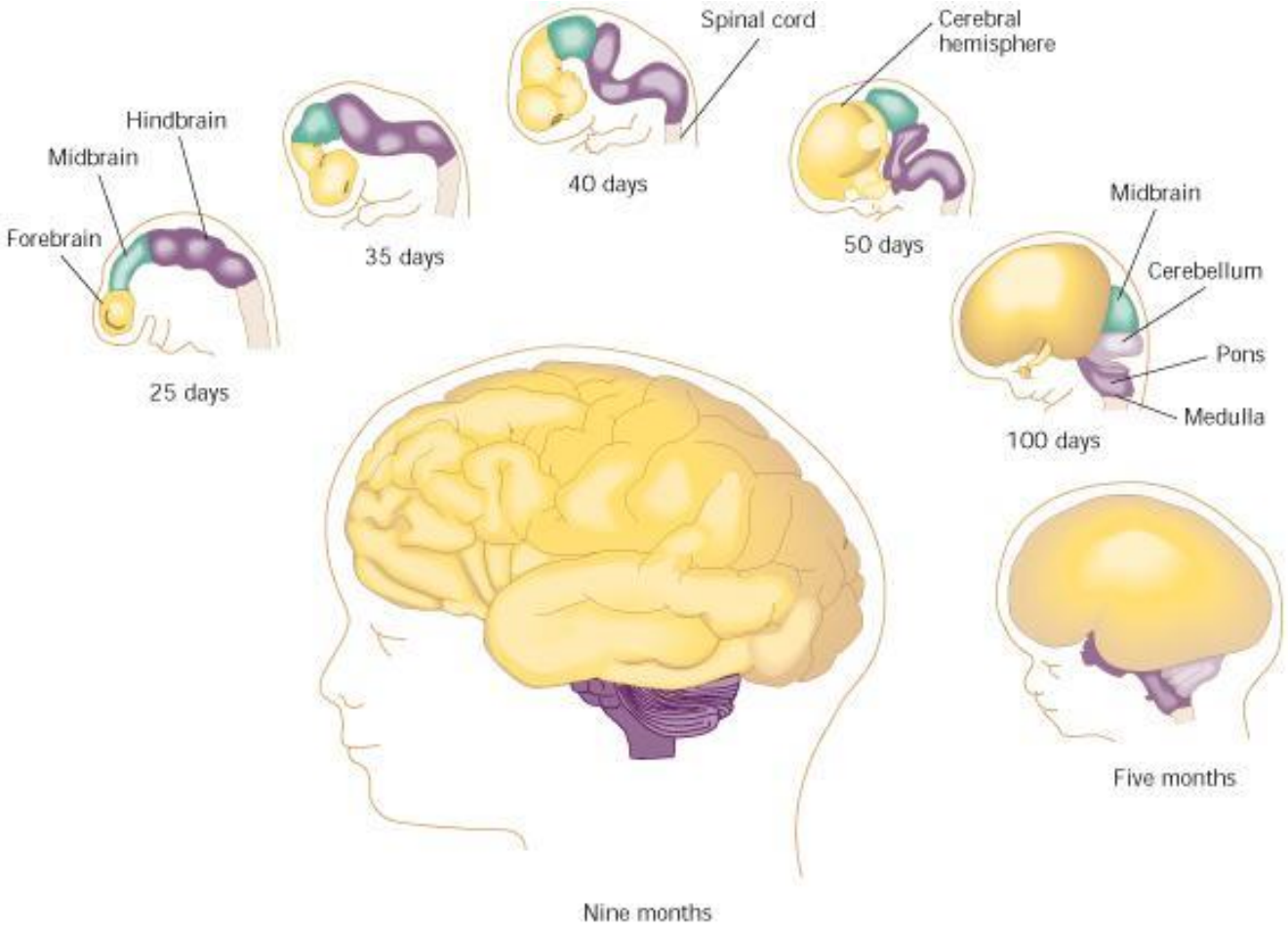

The hindbrain

- Includes medulla, pons, and cerebellum
- **Medulla and pons (brainstem)**

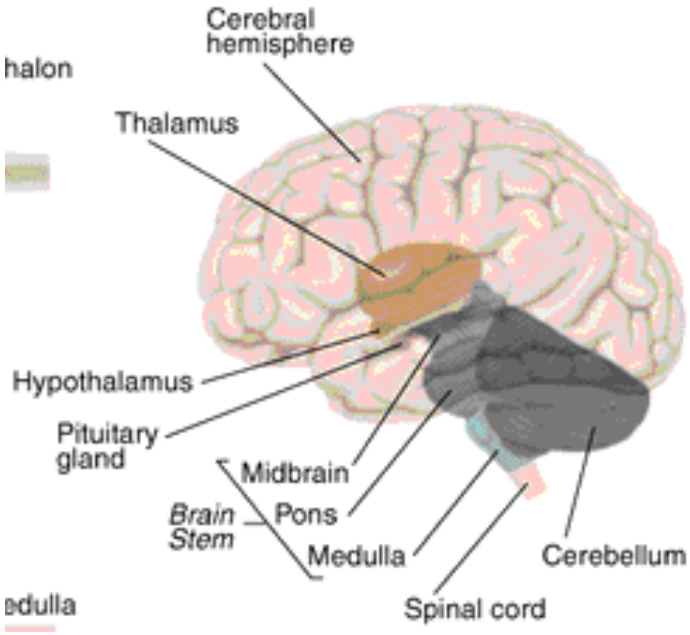

Brain Stem

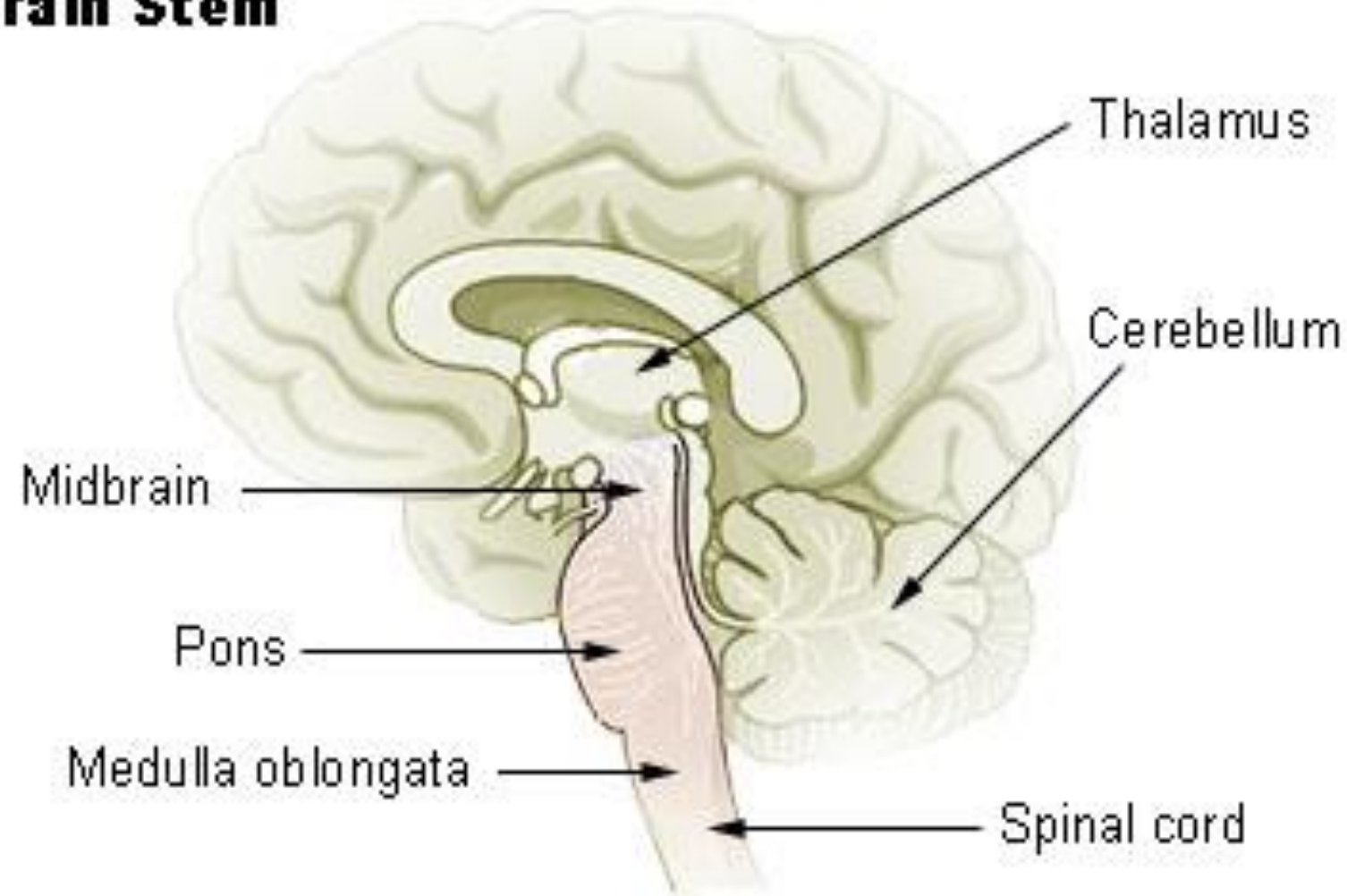
Thalamus
Cerebellum
Midbrain
Pons
Medulla oblongata
Spinal cord

Brainstem nuclei

- Contain nuclei that help to control basic functions such as breathing, heart rate, blood pressure, and initiating reflexive actions- coughing, gagging, vomiting
- Medullary and pontine nuclei associated with cranial nerves, contain cell bodies of motor neurons whose axons leave brain via some of the cranial nerves

The Cerebellum

- coordinating motor action
- learning and memory of motor tasks
- participates in certain types of cognitive tasks that require mental manipulation of spatial relationships

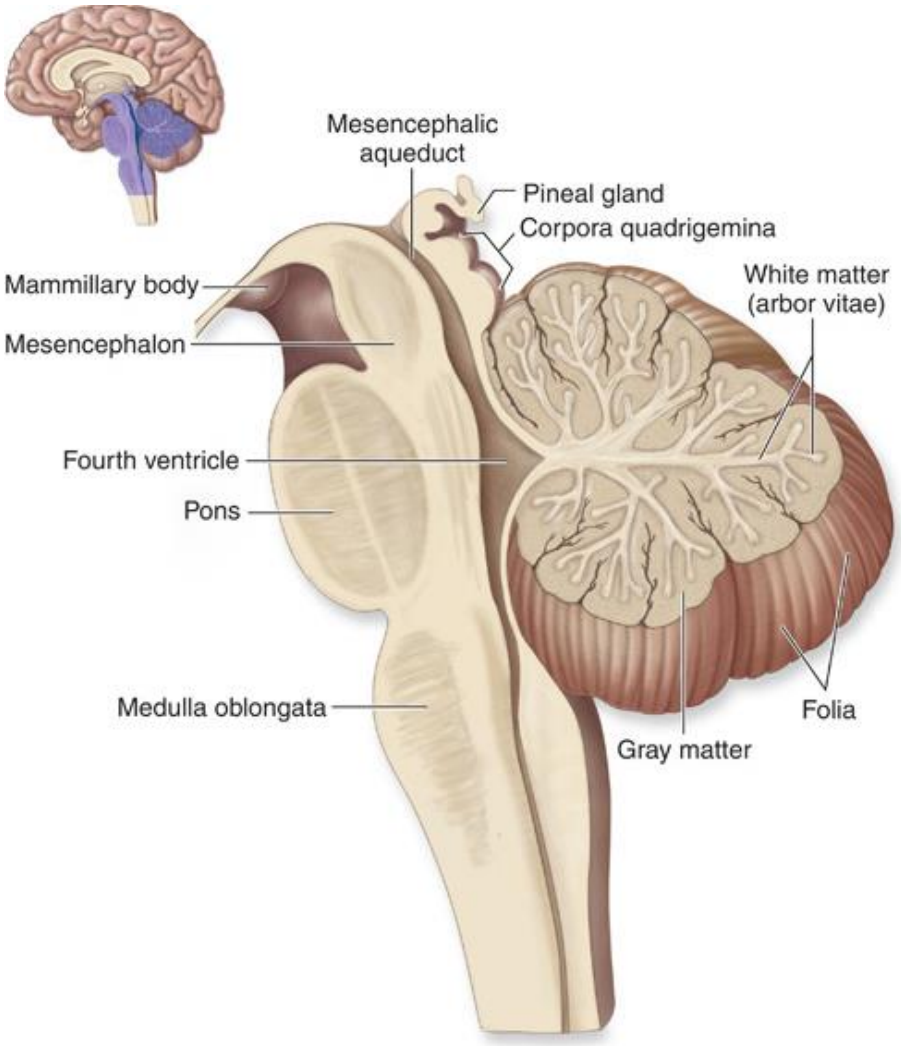

The midbrain

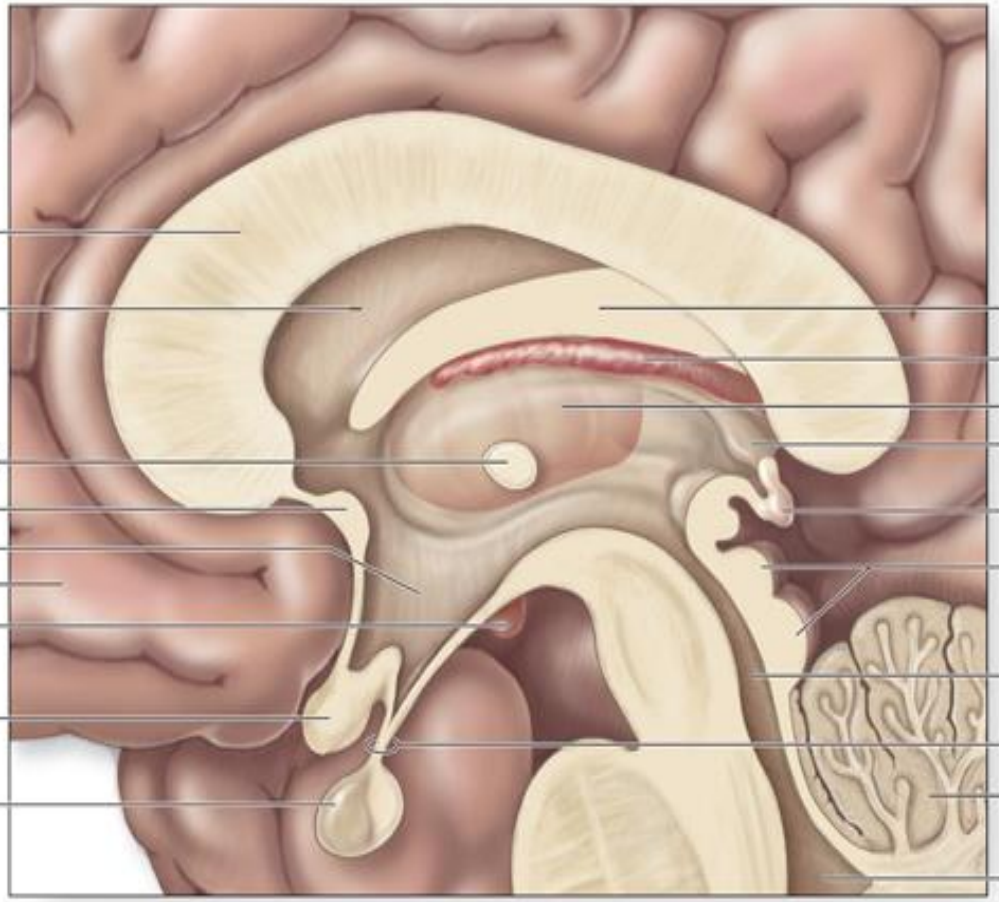

Midsagittal section

The midbrain

- **superior colliculus-** major visual center detecting and selecting targets for orienting movements of body, eyes
- **inferior colliculus**- located on dorsal midbrain posterior to superior colliculus, auditory processing structure

The midbrain

Tegmentum portion of midbrain that lies under cerebral aqueduct contains red nucleus and substantia nigra

important in orientation reflexes, and voluntary movements, substantia nigra damaged in Parkinson's disease, a motor disorder

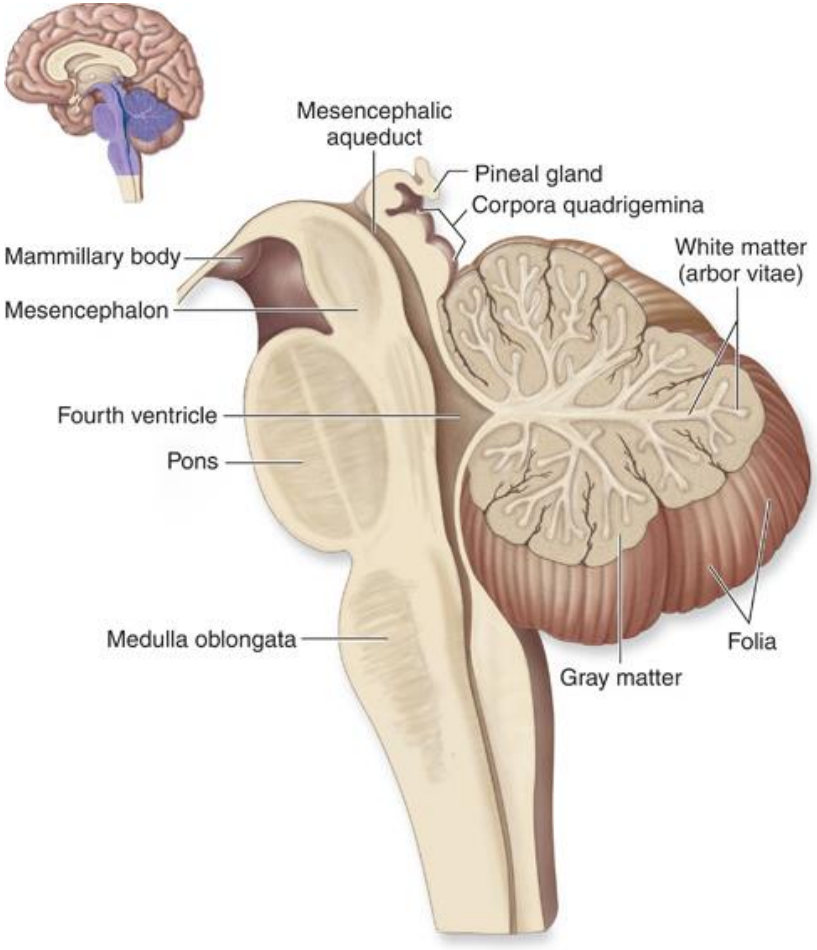

(a) Midsagittal section

Forebrain

- **The diencephalon**
- **The telencephalon**

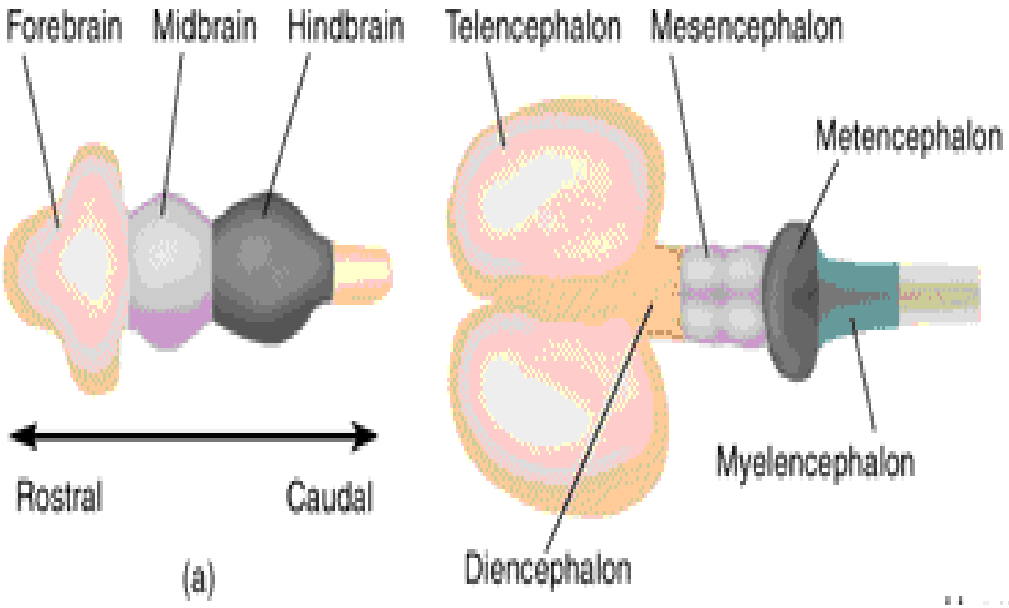

The diencephalon

- consists mainly of thalamus and hypothalamus

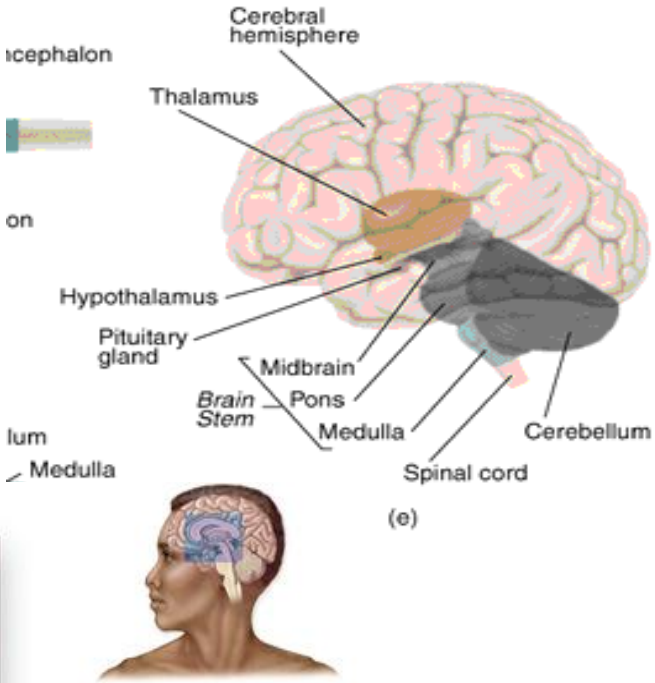

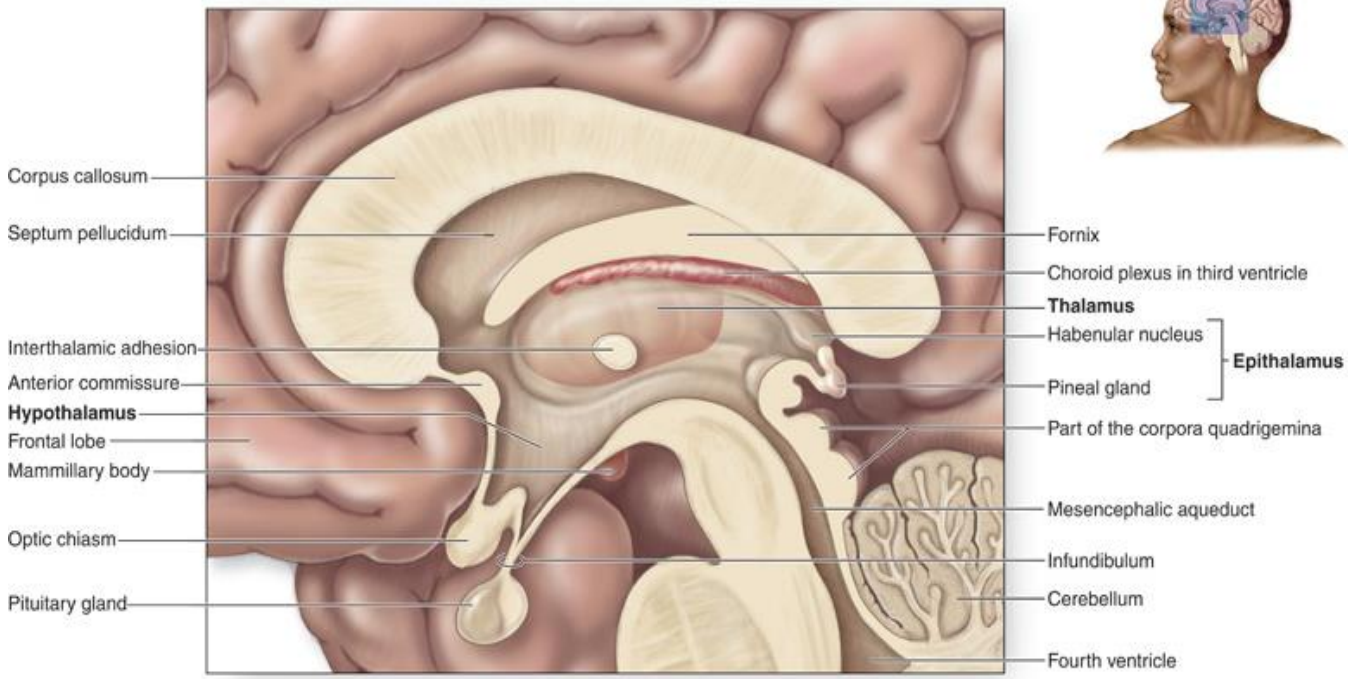

Midsagittal section

Thalamus

- important relay station for sensory information

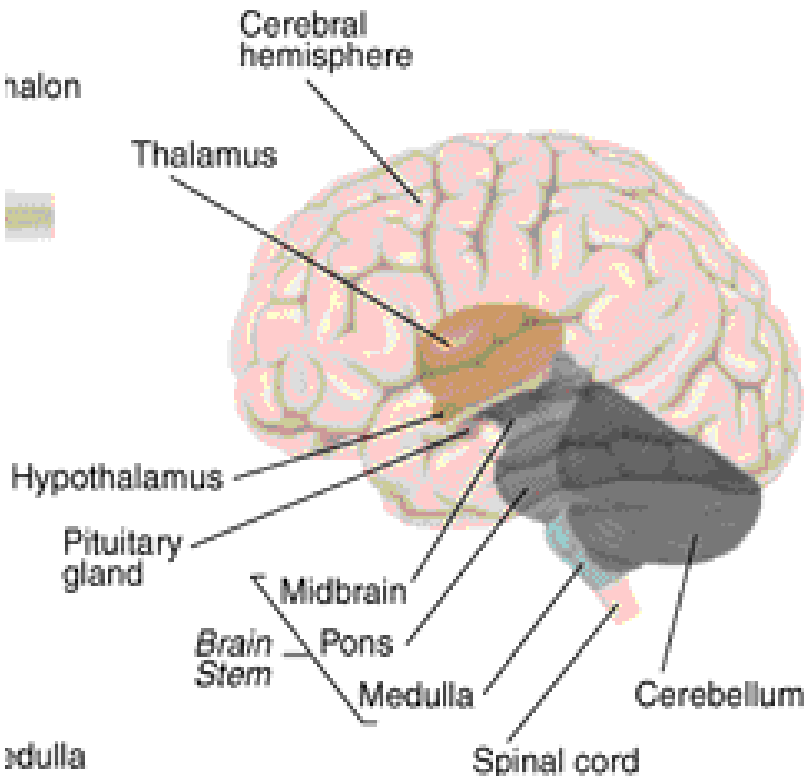

Hypothalamus

- **Hypothalamus involved in homeostasis in three ways:**
- initiate or supress behaviors such as eating or drinking that affect internal body conditions
- regulates pituitary gland, exerts control over endocrine system, which in turn adjusts many internal conditions such as salt and water balance in blood
- regulates many homeostatic conditions by control of autonomic system, which influences factors such as blood pressure and body temperature

Hypothalamus

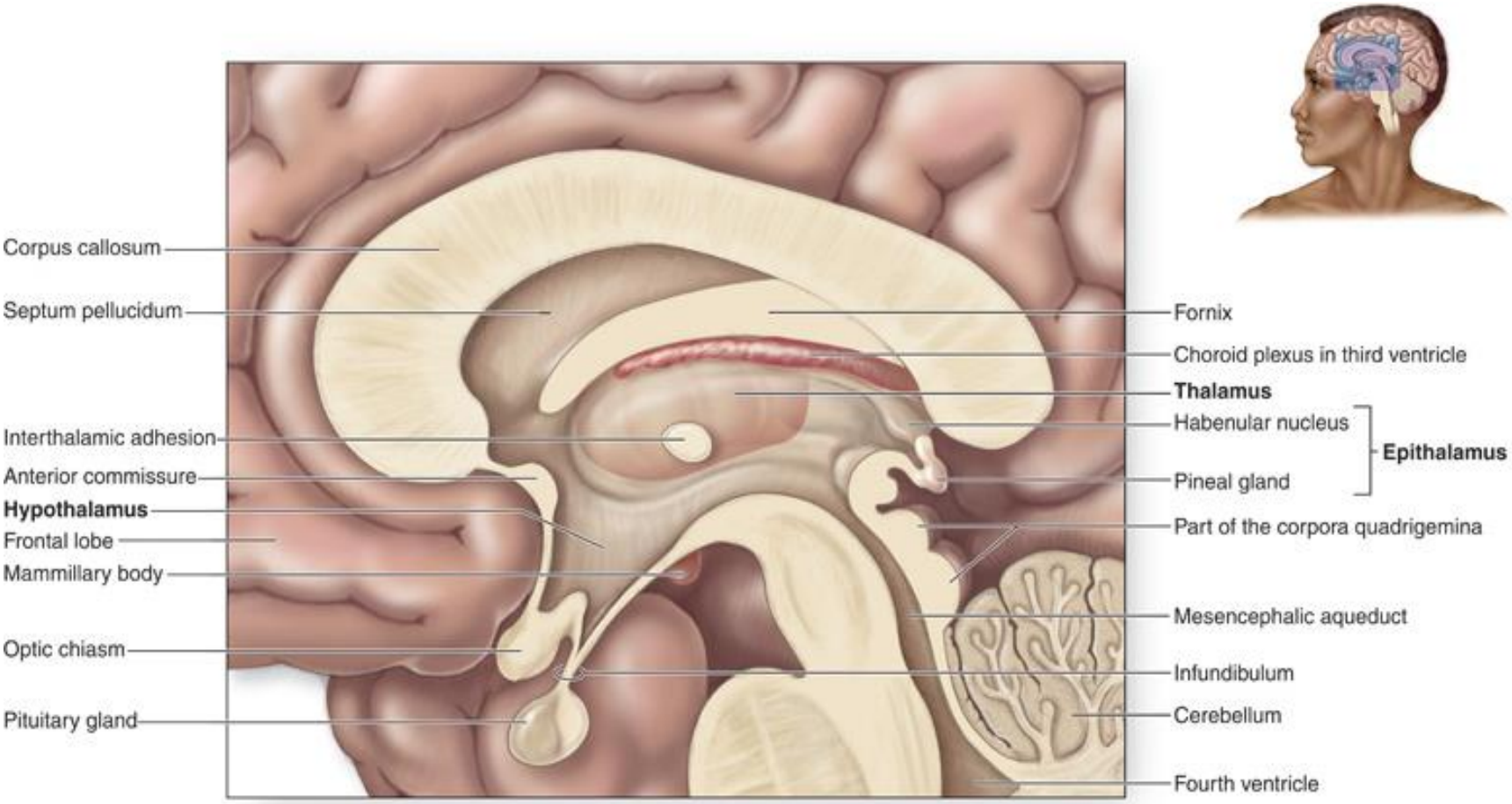

Midsagittal section

The telencephalon

Consists of cerebral hemispheres plus a number of functionally related and important nuclei that serve functions such as motor control and emotional reactions

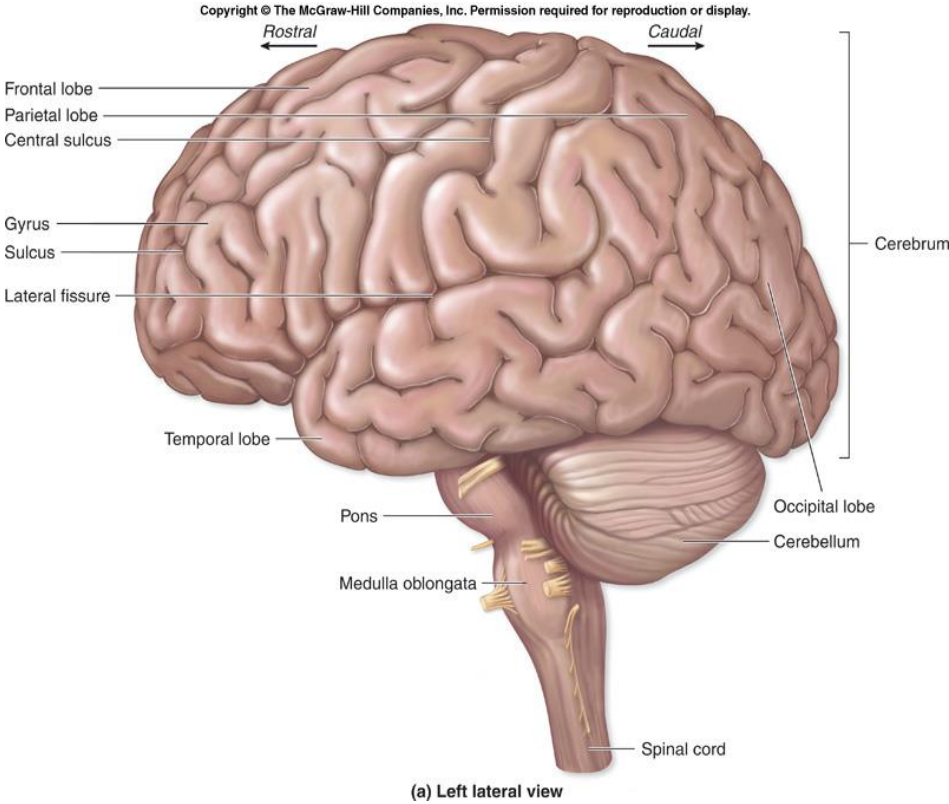

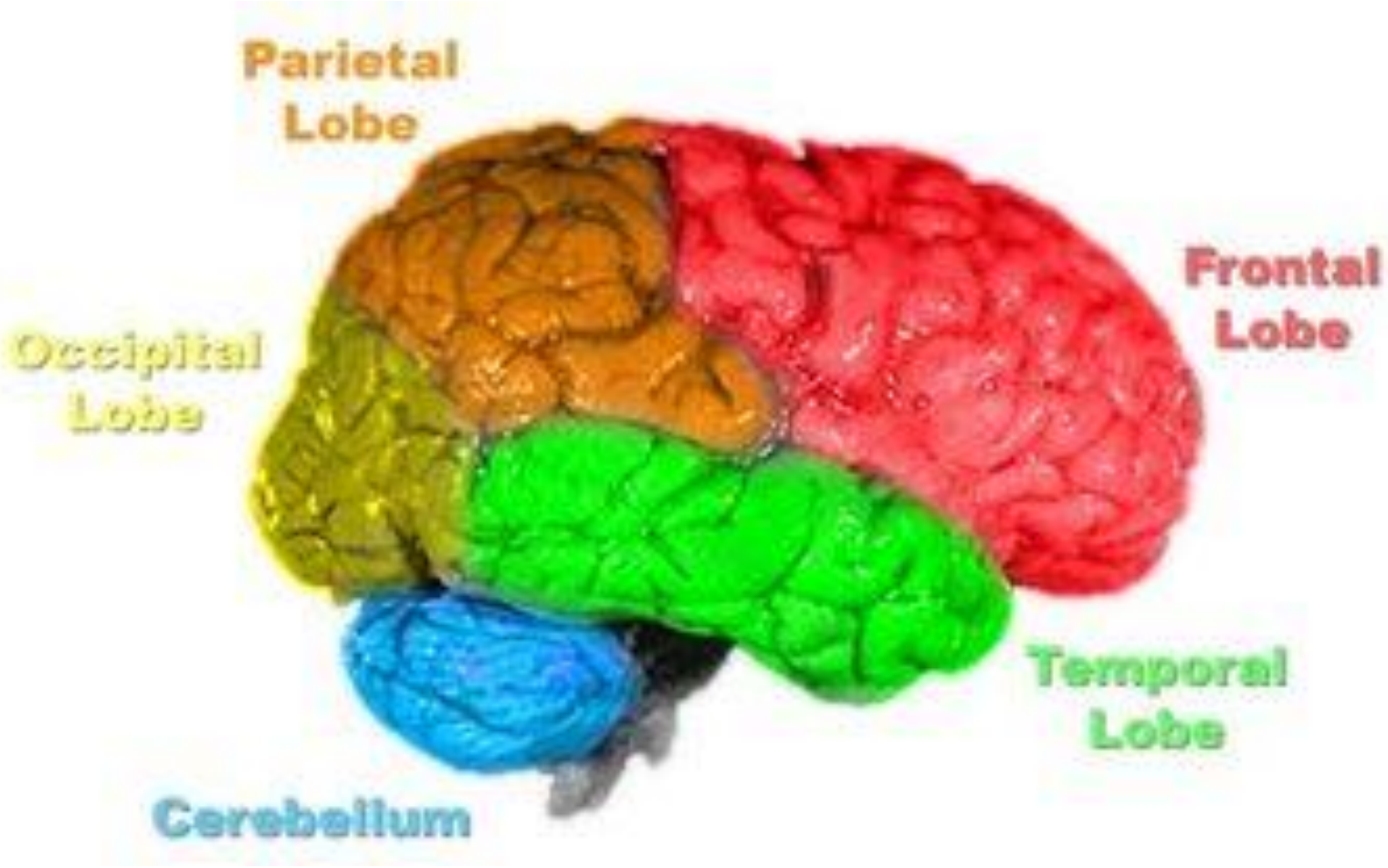
Parietal Lobe
Frontal Lobe
Occipital Lobe
Temporal Lobe
Cerebellum

The cerebral hemispheres

- cerebral hemispheres linked by corpus callosum
- central sulcus divides each cerebral hemisphere into anterior and posterior halves

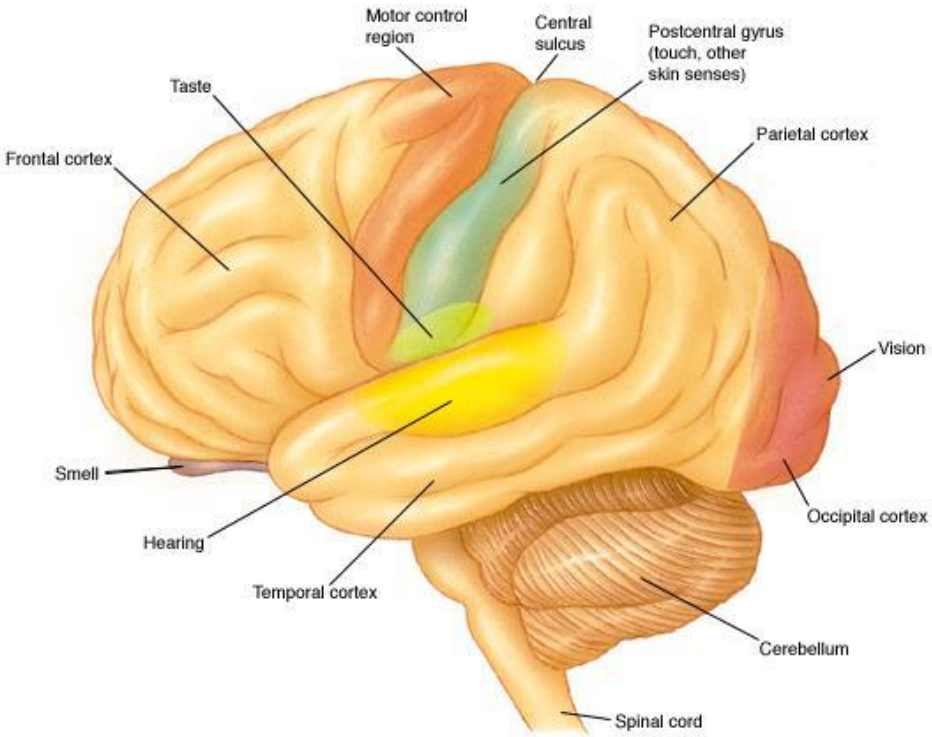

- **Four Lobes of the Cerebral Cortex, the Primary Sensory and Motor Cortex, and the Associative Cortex. (a) View from Base of Brain. (b) Midsagittal View, with Cerebellum and Brain Stem Removed. (c) Lateral View**

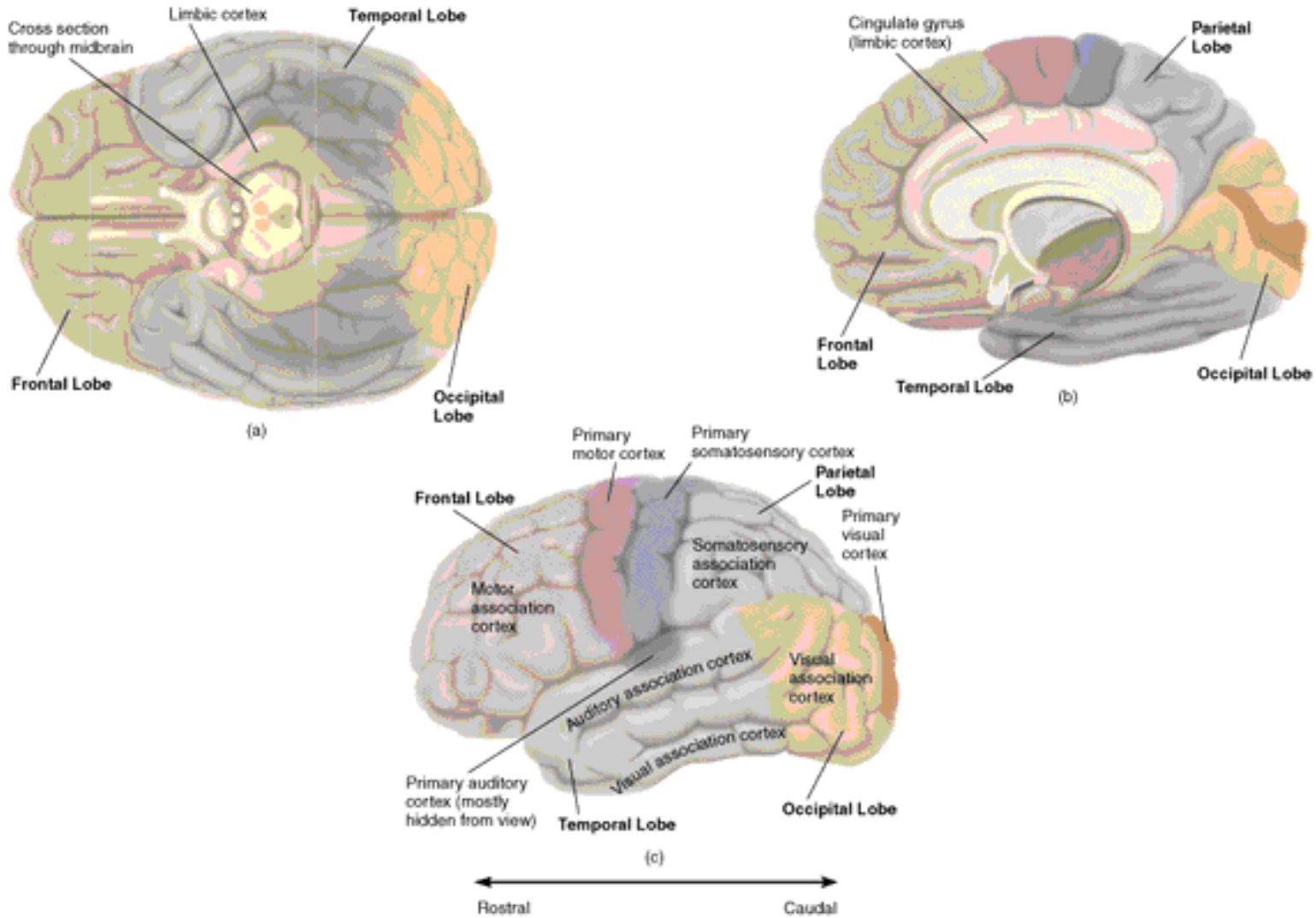

- motor cortex lies just ahead of central sulcus
- postcentral gyrus process information from muscles and body surface somatosensory (touch)
- information from eyes processed in occipital lobe
- information from ears processed in a portion of temporal lobe
- information from nose processed in olfactory bulb

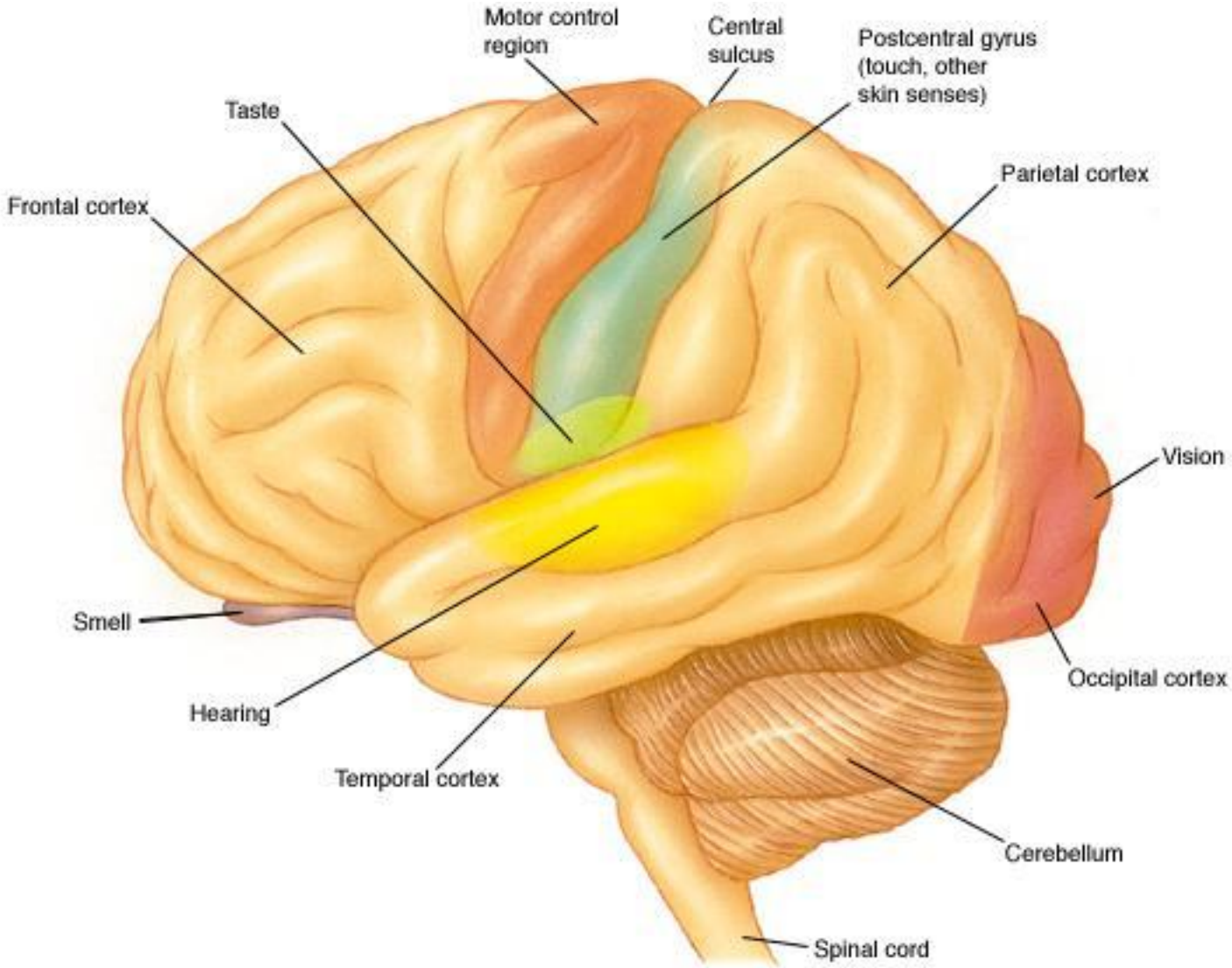
Motor control region
Central sulcus
Postcentral gyrus (touch, other skin senses)
Taste
Parietal cortex
Frontal cortex
Vision
Smell
Occipital cortex
Hearing
Temporal cortex
Cerebellum
Spinal cord

LOCALIZATION OF MOTOR AND SENSORY FUNCTIONS

LATERAL VIEW

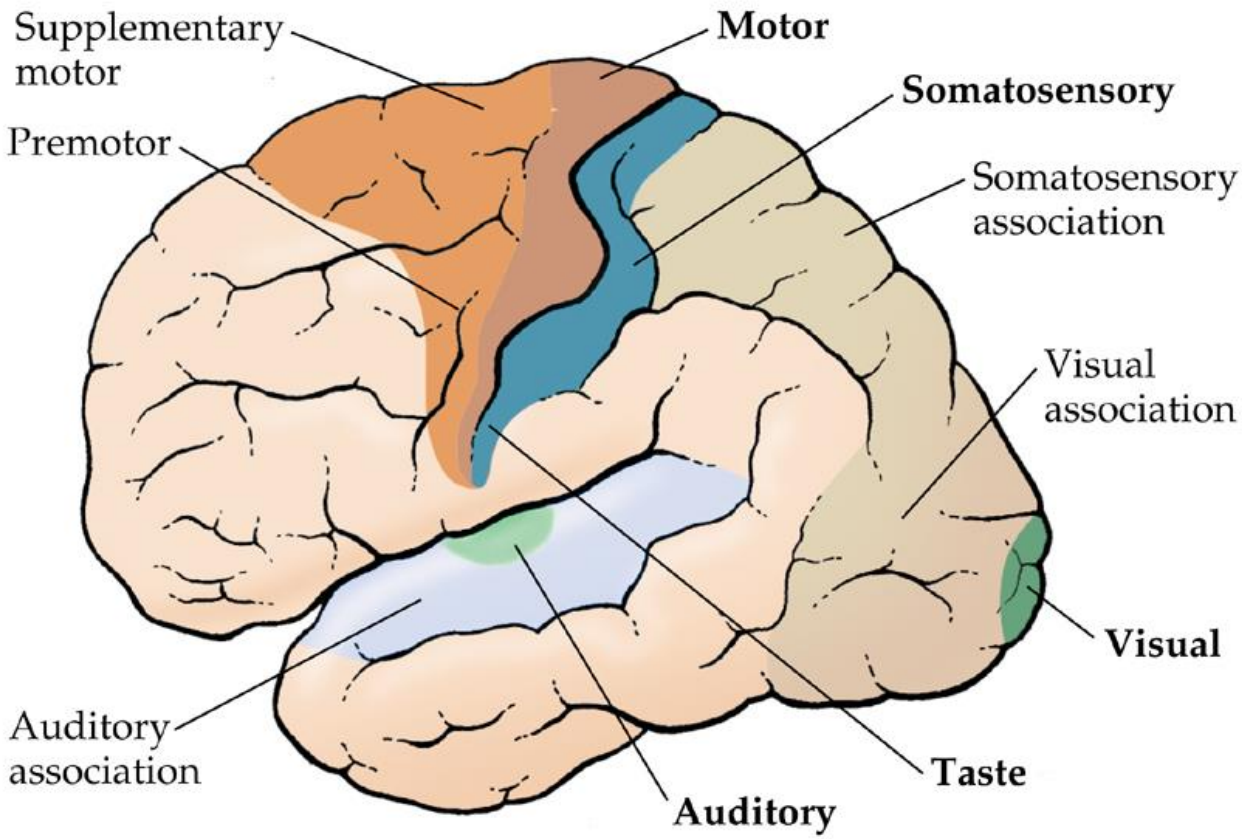

SAGITTAL VIEW

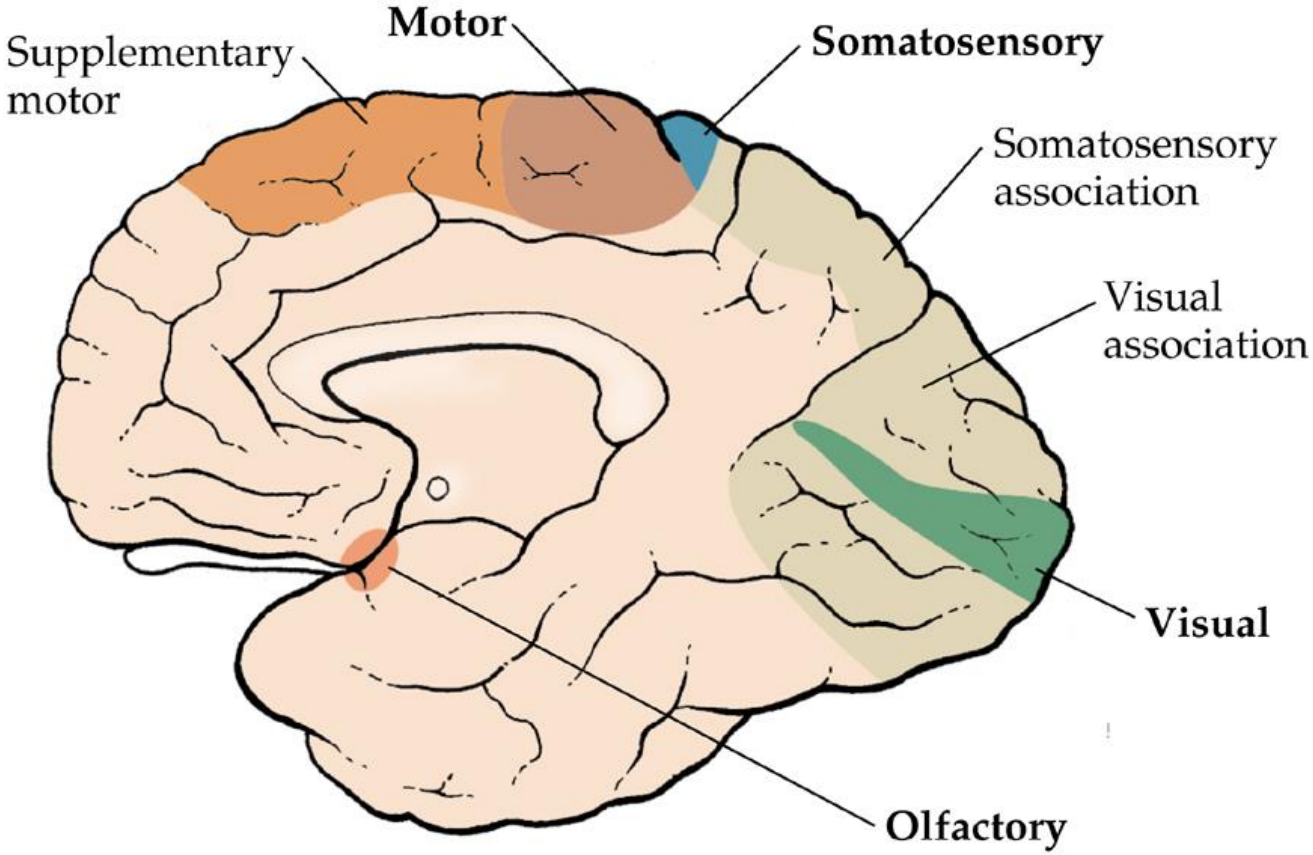

The basal ganglia

- Group of nuclei clustered around thalamus (putamen, globus pallidus, caudate nucleus)

- Important in motor planning and control.

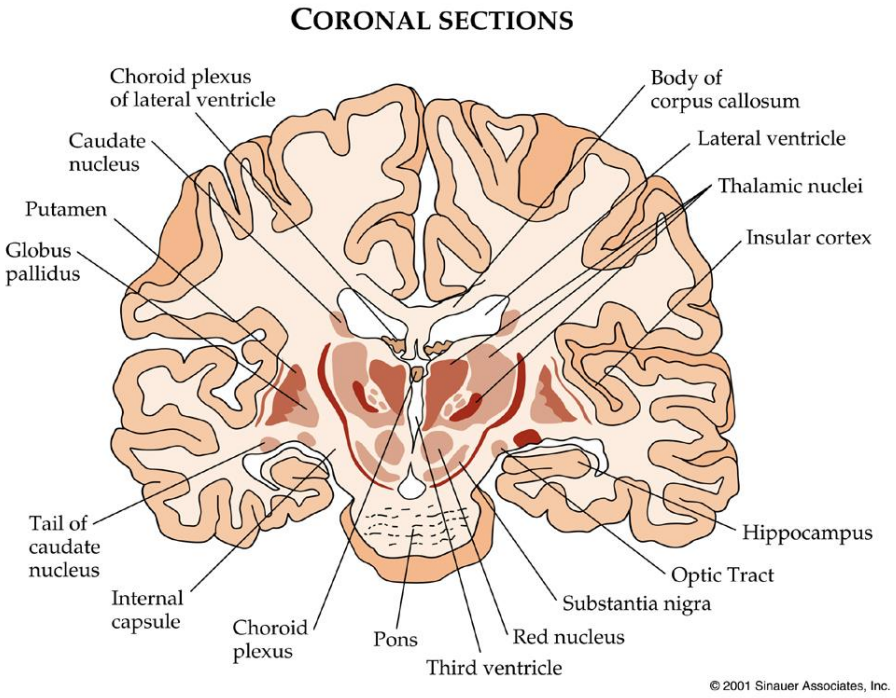

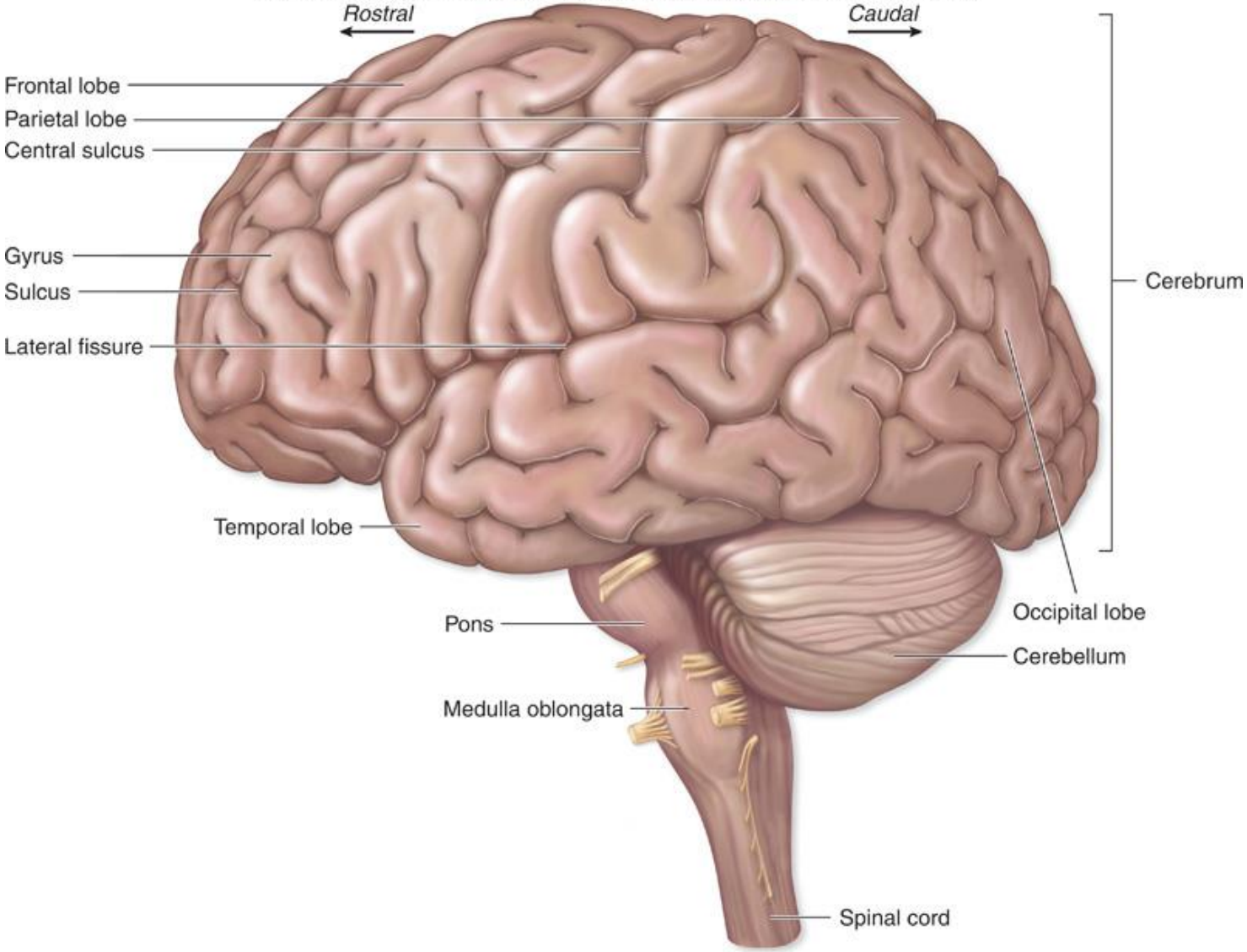

(a) Left lateral view

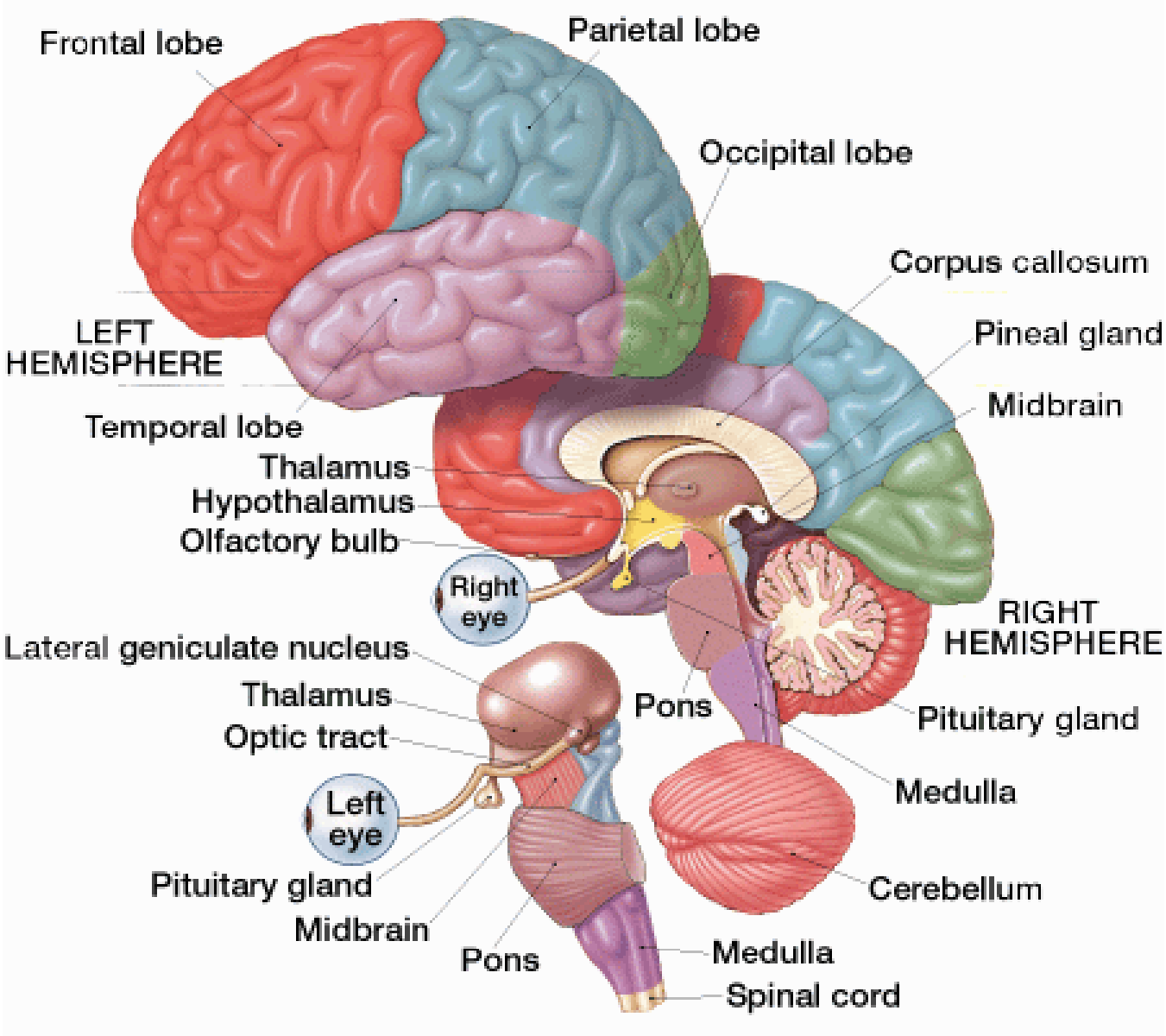
Frontal lobe
Parietal lobe
Occipital lobe
Corpus callosum
Pineal gland
Midbrain
LEFT
HEMISPHERE
Temporal lobe
Thalamus
Hypothalamus
Olfactory bulb
Right
eye
RIGHT
HEMISPHERE
Lateral geniculate nucleus
Thalamus
Optic tract
Pons
Pituitary gland
Medulla
Left
eye
Pituitary gland
Cerebellum
Midbrain
Pons
Medulla
Spinal cord