Organization of the nervous system

1. **Central Nervous System** (**CNS**)
   - a. Brain
   - b. Spinal cord
- 2. **Peripheral Nervous System (PNS)**
   - a. Peripheral nerves
   - b. Ganglia

The **peripheral nervous system** is subdivided into the

- **sensory-somatic nervous system** and the
- **autonomic nervous system**

The Sensory-Somatic Nervous System

- 12 pairs of **cranial nerves** and
- 31 pairs of **spinal nerves**.

The Autonomic Nervous System (ANS) Controls the Body's Internal Environment in a Coordinated Manner

- **In the ANS there are 2 nerves** between the central nervous system (CNS) and the organ. **The nerve cell bodies for the second nerve are organized into ganglia:**

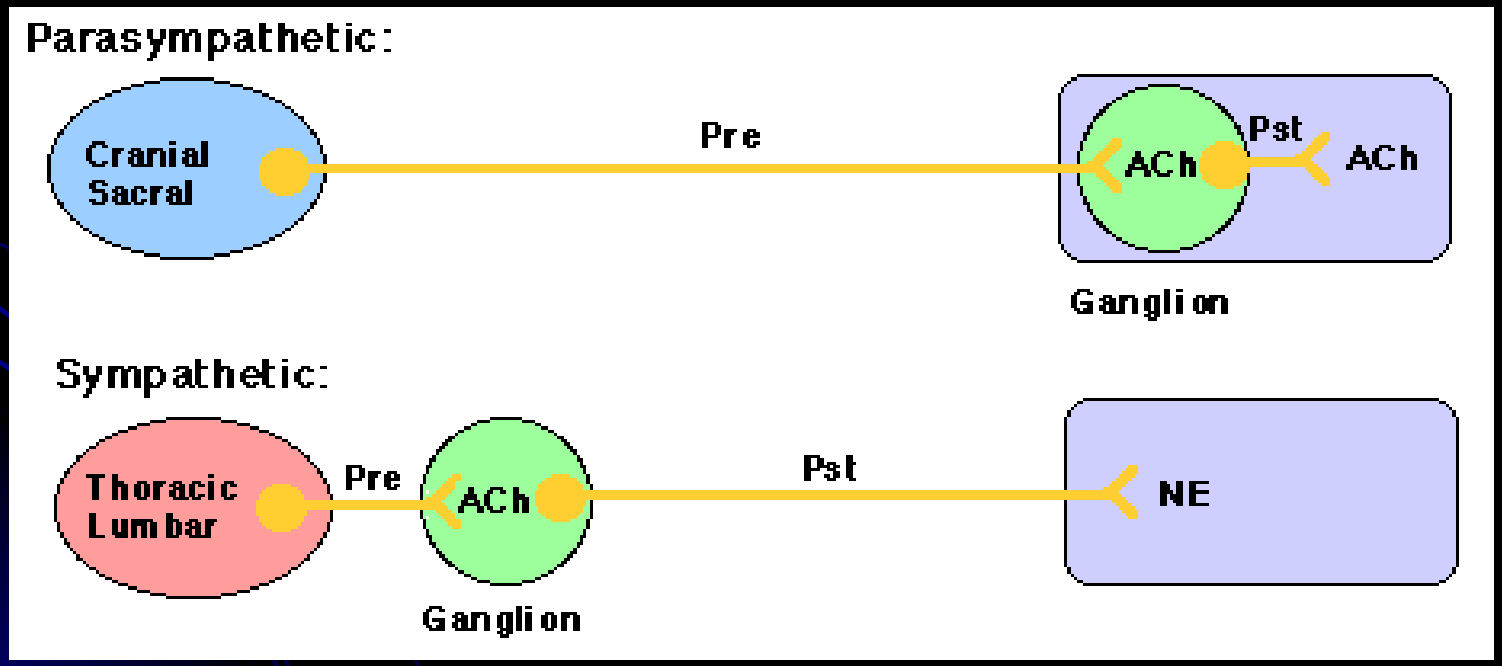

The ANS has 2 Divisions, Sympathetic and Parasympathetic, Which Differ in Anatomy and Function

The Sympathetic is the "Fight or Flight" Branch of the ANS

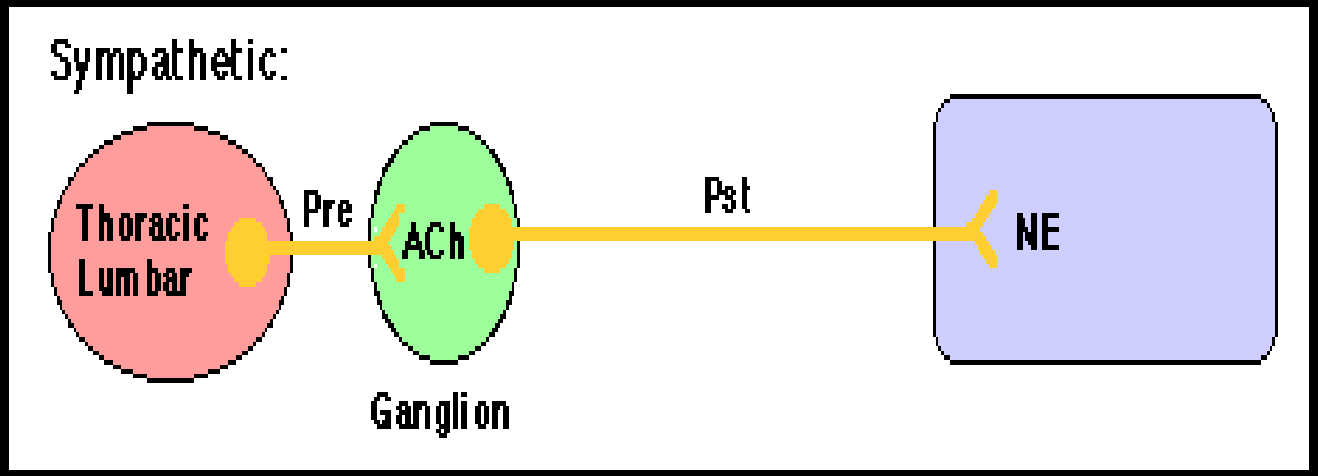

- **The sympathetic nerves *come from the thoracic and lumbar regions of the spinal cord.***
- The preganglionic nerves are short and synapse in paired ganglia adjacent to the spinal cord

The Parasympathetic is the "Rest and Digest" Branch of the ANS

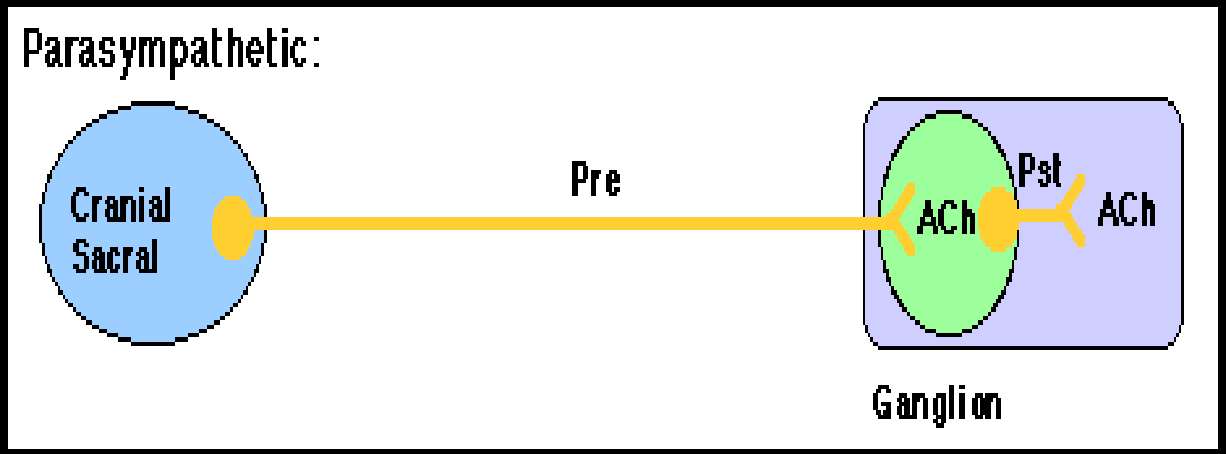

- **Parasympathetic nerves *come from the cranial and sacral regions of the CNS.***
- They have long preganglionic nerves which synapse at ganglia near or on the organ innervated

Cranial Nerves

There Are 12 Pairs of Cranial Nerves

- The 12 pairs of cranial nerves emerge mainly from the ventral surface of the brain
- Most attach to the medulla, pons or midbrain
- They leave the brain through various fissures and foramina of the skull

Cranial Nerves Contain Sensory, Motor and Parasympathetic Fibers

Cranial Nerves Mediate 5 Special Senses: *Smell, Vision, Hearing, Taste, Equilibrium*

- Smell: nerve ***I (Olfactory)***
- Vision: nerve ***II (Optic)***
- Hearing: nerve ***VIII (Auditory)***
- Equilibrium: nerve ***VIII (Auditory)***
- Taste: nerves ***VII, IX, X (minor) (Facial, Glossopharyngeal, Vagus)***

Most of the Nerves Carry Somatic (Skin & Muscle) Sense

- ***The trigeminal (V)*** is the sensory nerve for the face
- The nerves which are primarily motor also have fibers for muscle sense (proprioception): III, IV, VI, VII, XI, XII

Three Nerves Are Concerned With Eyeball Movements

- ***Oculomotor (III):*** superior rectus, medial rectus, inferior rectus, inferior oblique
- ***Trochlear (IV)***: superior oblique
- ***Abducens (VI)***: lateral rectus

Several of the Nerves Innervate Other Skeletal Muscles

- ***The Facial nerve (VII)*** controls the muscles of facial expression
- ***The Spinal accessory (XI)*** stimulates the trapezius and sternocleidomastoid
- Chewing muscles (masseter, temporalis) are innervated by the ***Trigeminal (V)***
- Speech muscles (larynx) are under control of the ***Vagus (X)***
- ***The Hypoglossal (XII***) moves the tongue

Four of the Nerves Carry Parasympathetic Fibers

- ***Oculomotor (III):*** innervates iris constrictor (causes pupil constriction); also controls ciliary muscle (focuses the lens)
- ***Facial (VII)*** and ***Glossopharyngeal (IX):*** stimulate salivary glands to secrete
- ***Vagus (X):*** the major nerve of the parasympathetic system: goes to most visceral organs (heart, lungs, kidneys, liver, stomach, intestines)

Damage to Cranial Nerves Causes Many Medical Problems

- ***Anosmia*** (loss of smell): sometimes caused by fractures which damage the cribiform plate. This damages the Olfactory nerve as it passes through the plate.
- ***Bell's Palsy***: paralysis of the muscles of facial expression on one side. Caused by inflammation of the Facial nerve.
- ***Tic douloureux***: severe facial pain caused by inflammation of the trigeminal nerve.
- ***Blindness:*** caused by damage to optic nerve. Degree of blindness depends upon the location of the damage.

Memory Devices for Learning the Names of the 12 Cranial Nerves

- ***O***n ***O***ld ***O***lympus's ***T***owering ***T***ops ***A*** ***F***inn ***A***nd ***G***erman ***V***iewed ***S***ome ***H***ops

- ***O***h, ***O***h, ***O***h, ***T***o ***T***ouch ***A***nd ***F***eel ***V***ery ***G***ood ***V***elvet, ***AH***!

- The first letters (bold) match up with the first letters of the cranial nerves (for the second phrase use Vestibulocochlear instead of Auditory and plain Accessory instead of Spinal Accessory)

Cranial Nerve I - Olfactory Nerve

- The **cell bodies** of the olfactory nerve are in the **nasal mucosa**.
- Their **axons form the olfactory nerves** which ascend through the cribriform plate synapse in the olfactory bulb of the brain
- The **olfactory bulb, which contains the cell bodies of the secondary sensory neurons**, is an enlargement of the rostral end of the olfactory tract.
- **The olfactory tract consists of the axons of these secondary sensory neurons**.
- The axons of the olfactory tract project to the olfactory areas of the cortex.

Areas of the rhinencephalon

- **Lateral (primary) olfactory area** - consists of the cortex of the **uncus and the anterior part of the hippocampal gyrus** (entorhinal area). Most of the axons of the olfactory tract project here.
- **Intermediate olfactory area** - located **beneath the olfactory trigone.**
- **Medial olfactory area** - located in the septal region of the **medial surface of the frontal lobe.** Via its connections with the limbic system, this area is thought to mediate the emotional response to odors.

Cranial Nerve II - Optic Nerve

- ***Overview***

  The optic nerve has only a special sensory component

  Special sensory conveys visual information from the retina (special afferent).

  Visual information enters the eye in the form of photons of light which are converted to electrical signals in the retina. These signals are carried via the optic nerves, chiasm, and tract to the lateral geniculate nucleus of each thalamus and then to the visual centers of the brain for interpretation

Sensory Transduction

- Light passing through the cornea and aqueous humor and entering the pupil travels through the lens and vitreous body to reach the retina at the back of the eye.

  The process of converting photons of light into electrical signals occurs in a deep layer of the retina which contains the **photoreceptor cells - the rods and cones**.

  Rods and cones are specialized cells which have stacks of plasma membrane associated with visual pigments making them sensitive to light

Central Course

- The **optic nerve** travels posteromedially from the eye to exit the orbit via the optic canal in the lesser wing of the sphenoid bone.

  Upon exiting the optic canal the optic nerve enters the middle cranial fossa where it joins the other optic nerve to form the **optic chiasm:**

  At the optic chiasm approximately 1/2 of the fibers from each optic nerve cross the midline and exit the chiasm in the opposite **optic tract**.

Central Course

- The fibers of the optic tracts continue posteriorly around the cerebral peduncles of the midbrain with most synapsing in the **lateral geniculate nucleus** of their respective thalamus. A small portion of the fibers enter the pretectal region of the midbrain and participate in the pupillary light reflex.

  Cells of the lateral geniculate nuclei are tertiary sensory neurons which project to the primary visual cortex in the occipital lobe via the **optic radiation** (geniculocalcarine tract). Note that the axons of the optic radiation fan out to pass above and lateral to the inferior horn of the lateral ventricles enroute to the visual cortex. The fibers that course anteriorly toward the pole of the temporal lobe before turning posteriorly are referred to as **Meyer's loop**.

Cranial Nerve III - Oculomotor Nerve

- Consists of two components with distinct functions:

  The somatic motor component of CN III plays a major role in controlling the muscles responsible for the precise movement of the eyes for visual tracking or fixation on an object.

  The visceral motor component is involved in the pupillary light and accomodation reflexes.

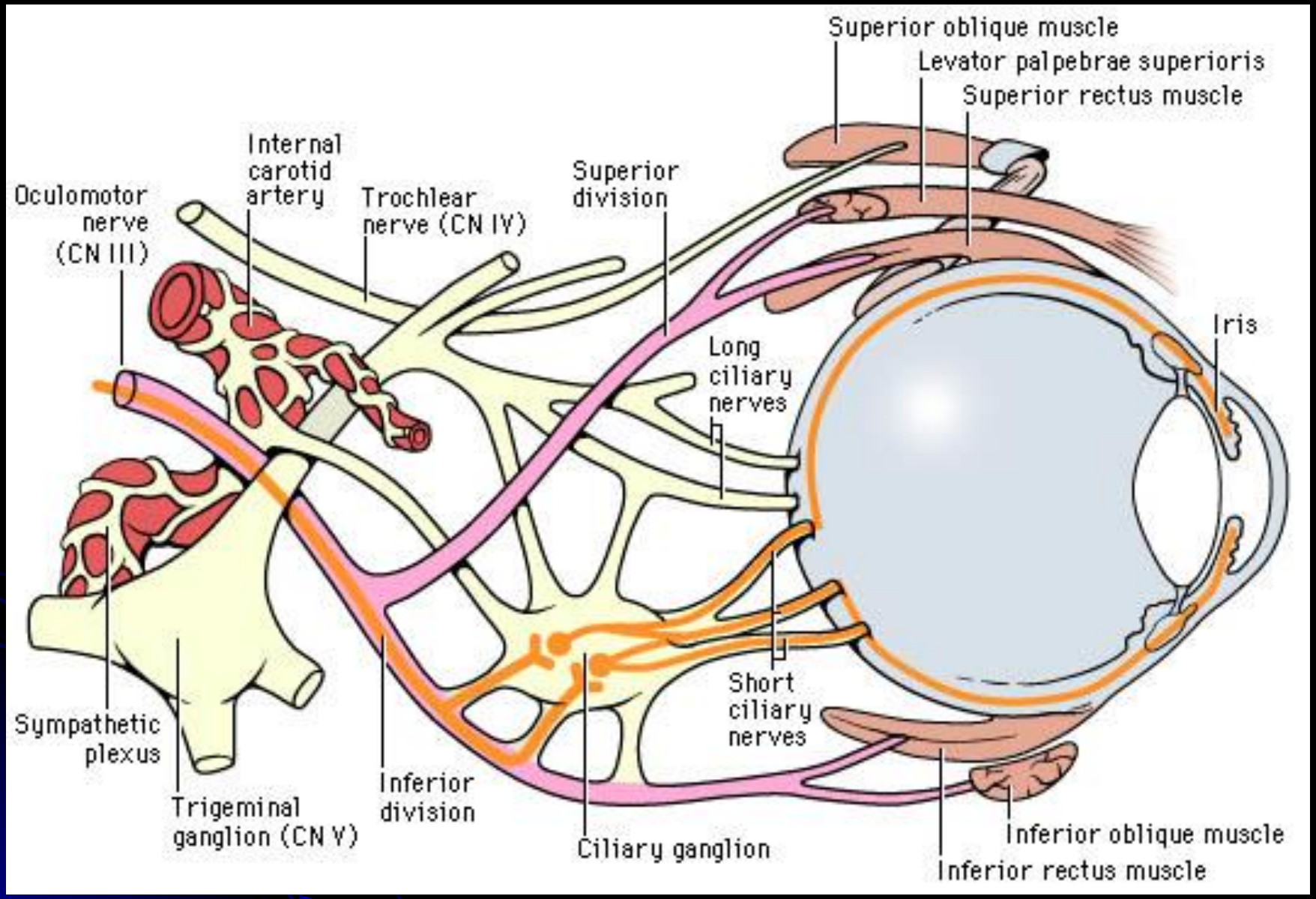
Superior oblique muscle
Levator palpebrae superioris
Superior rectus muscle
Internal carotid artery
Oculomotor nerve (CN III)
Trochlear nerve (CN IV)
Superior division
Iris
Long ciliary nerves
Short ciliary nerves
Sympathetic plexus
Trigeminal ganglion (CN V)
Inferior division
Ciliary ganglion
Inferior oblique muscle
Inferior rectus muscle

Overview of the Somatic Motor Component

- There are six extraocular muscles in each orbit.
- The somatic motor component of CN III innervates the following four extraocular muscles of the eyes:

  inferior rectus muscle

  inferior oblique muscle

  medial rectus muscle

  superior rectus muscle

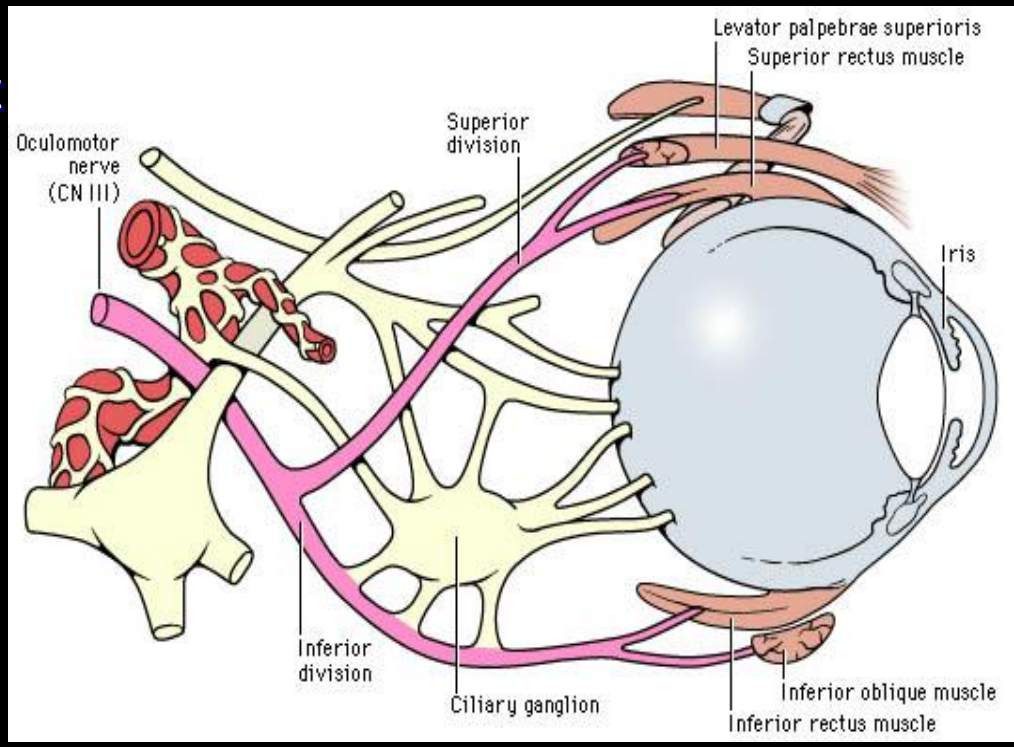

- The remaining extraocular muscles, the superior oblique and lateral rectus muscles, are innervated by the trochlear nerve (CN IV) and abducens nerve (CN VI), respectively.

  The somatic motor component of CN III also innervates the levator palpebrae superioris muscles bilaterally. These muscles elevate the upper eyelids.

Somatic motor component - origin and central course

- The somatic motor component of CN III originates from the oculomotor nucleus located in the rostral midbrain at the level of the superior colliculus.
- Fibers leaving the occulomotor nucleus travel ventrally in the tegmentum of the midbrain passing through the red nucleus and medial portion of the cerebral peduncle to emerge in the interpeduncular fossa at the junction of the midbrain and pons.

Somatic motor component - intracranial course

- Upon emerging from the brainstem the oculomotor nerve passes between the posterior cerebral and superior cerebellar arteries and pierces the dura mater to enter the cavernous sinus.

- The nerve runs along the lateral wall of the cavernous sinus just superior to the trochlear nerve and enters the orbit via the superior orbital fissure.

Somatic motor component, final innervation

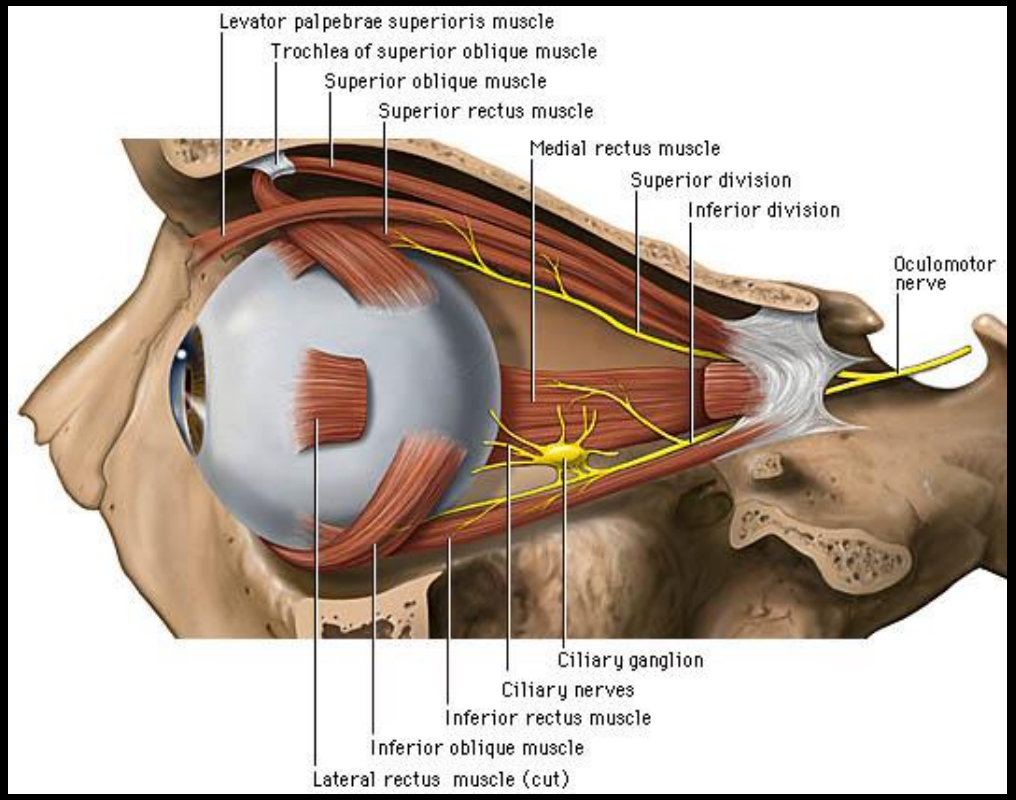

- Within the orbit CN III fibers pass through the tendinous ring of the extraocular muscles and divide into superior and inferior divisions.

  The superior division ascends lateral to the optic nerve to innervate the superior rectus and and levator palpebrae superioris muscles on their deep surfaces.

- The inferior division of CN III splits into three branches to innervate the medial rectus and inferior rectus muscles on their ocular surfaces and the inferior oblique muscle on its posterior surface.

Overview of the visceral motor component

- Provides parasympathetic innervation of the constrictor pupillae and ciliary muscles of the eye.

  The visceral motor component of CN III is involved in the pupillary light and accommodation reflexes.

Visceral motor component, origin and course

- The visceral motor component originates from the Edinger-Westphal nucleus located in the rostral midbrain at the level of the superior colliculus.

  Preganglionic parasympathetic fibers course ventrally through the midbrain, with the somatic motor fibers of CN III.

Visceral motor component, final innervation

- Once within the orbit the preganglionic parasympathetic fibers leave the nerve to the inferior oblique muscle to synapse in the ciliary ganglion which lies deep to the superior rectus muscle near the tendinous ring of the extraocular muscles.

  Postganglionic fibers exit the ciliary ganglion in the short ciliary nerves which enter the posterior aspect of the eye near the point of exit of the optic nerve.

  Within the eye these fibers travel forward between the choroid and sclera to innervate the ciliary muscles (which control the shape and therefore the refractive power of the lens) and the constrictor pupillae muscle of the iris (which constricts the pupil).

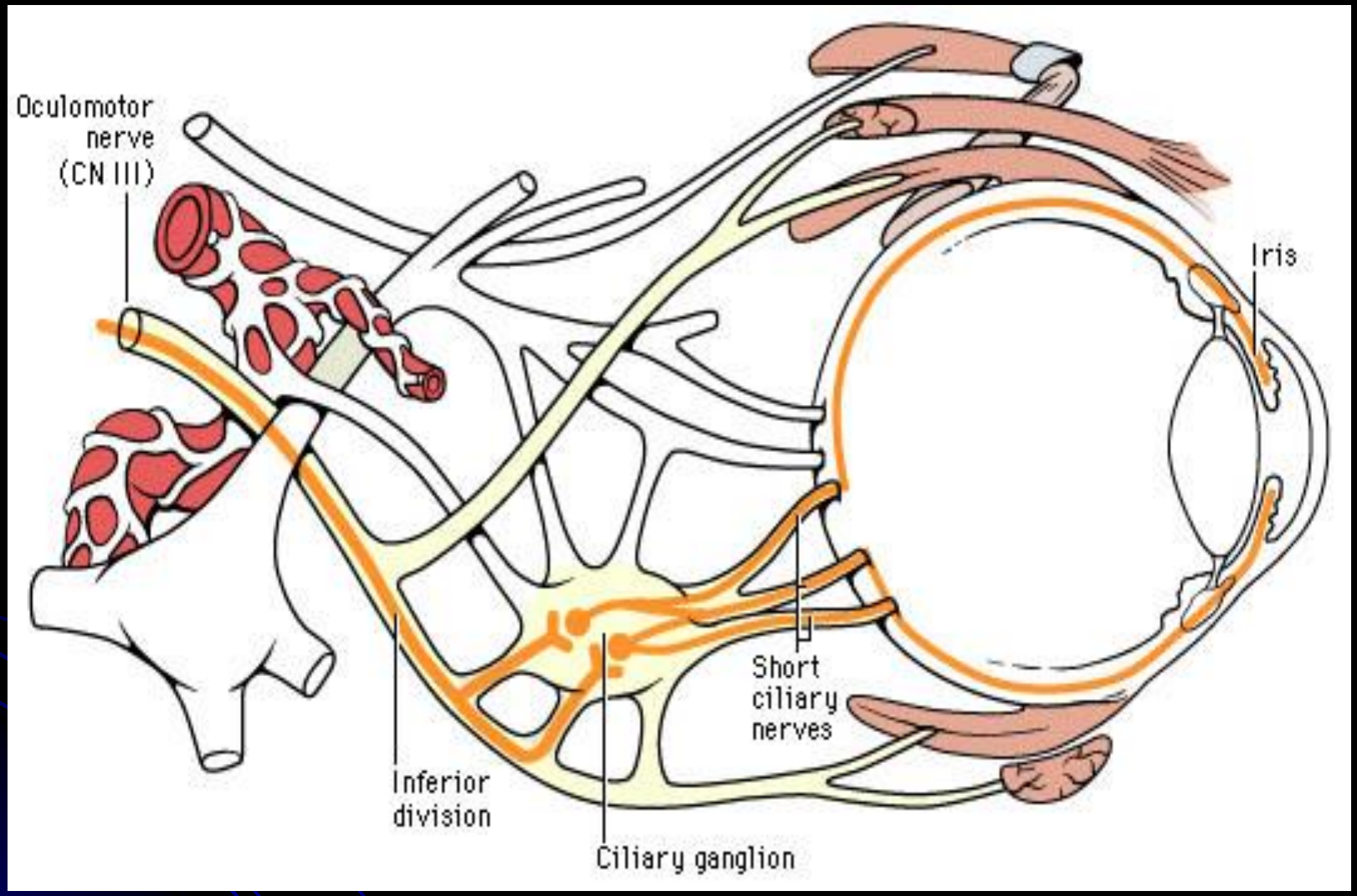
Oculomotor
nerve
(CN III)
Iris
Short
ciliary
nerves
Inferior
division
Ciliary ganglion

Cranial Nerve IV - Trochlear Nerve

- The trochlear nerve has only a somatic motor component:
- The superior oblique muscle is one of the six extraocular muscles responsible for the precise movement of the eye for visual tracking or fixation on an object.

Origin and central course

- The fibers of the trochlear nerve originate from the trochlear nucleus located in the tegmentum of the midbrain at the level of the inferior colliculus.

  All fibers of the two trochlear nerves decussate (i.e. cross) in the superior medullary velum and exit the dorsal surface of the brainstem just below the contralateral inferior colliculus

Intracranial course

- Upon emerging from the dorsal surface of the brainstem the trochlear nerve curves around the brainstem in the subarachnoid space and emerges between the posterior cerebral and superior cerebellar arteries (along with CN III fibers).

  The trochlear nerve then enters and runs along the lateral wall of the cavernous sinus with CNS III, V, and VI.

Intracranial course and final innervation

- From the cavernous sinus the trochlear nerve enters the orbit through the superior orbital fissure.

  CN IV does not pass through the tendinous ring of the extraocular muscles, rather it passes above the ring.

  The trochlear nerve then crosses medially along the roof of the orbit above the levator palpebrae and superior rectus muscles to innervate the superior oblique muscle along its proximal one-third:

Clinical Correlation

- The superior oblique muscle normally depresses, intorts, and abducts the eye. Damage to the trochlear nerve will present as:
- Extorsion (outward rotation) of the affected eye due to the unopposed action of the inferior oblique muscle.
- Vertical diplopia (double vision) due to the extorted eye

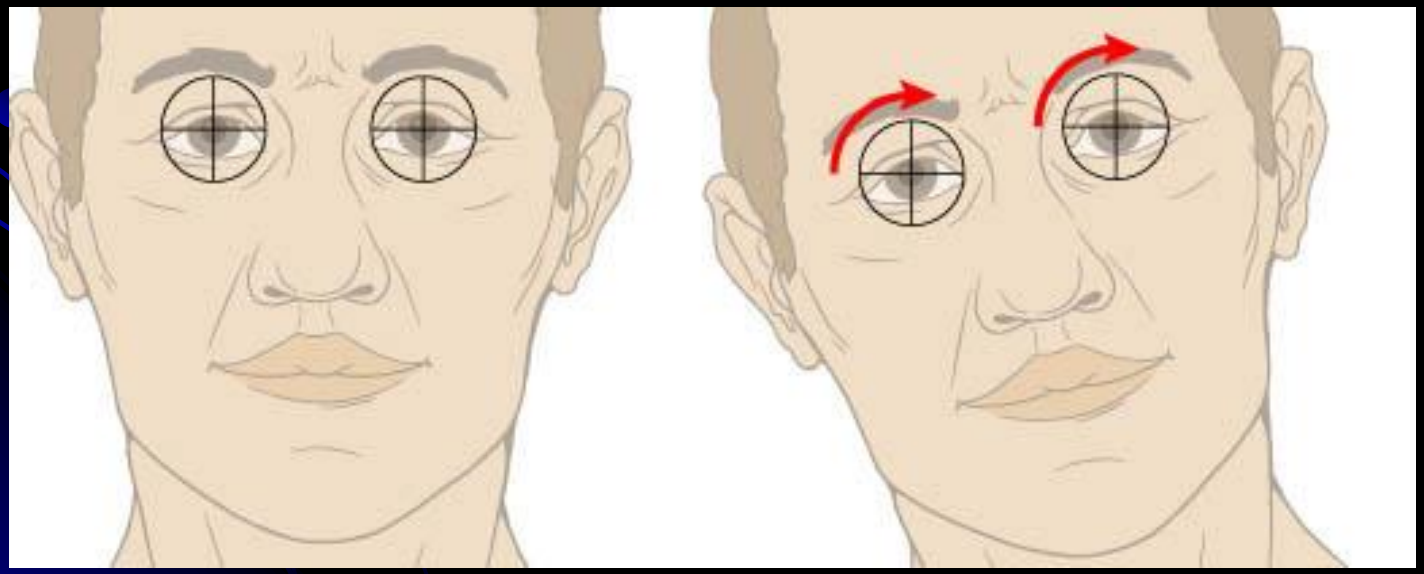

Clinical Correlation

- Weakness of downward gaze most noticeable on medially-directed eye. This is often reported as difficulty in descending stairs.
- Extortion (outward rotation) of the affected eye due to the unopposed action of the inferior oblique muscle .
- Vertical diplopia (double vision) due to the extorted eye. Weakness of downward gaze most noticeable on medially directed eye. This is often reported as difficulty in descending stairs.
- Head tilt: patient will often tilt his head opposite the side of the affected eye in an attempt to compensate for the outwardly rotated eye.
- Due to its long peripheral course around the midbrain CN IV is particularly susceptible to head trauma

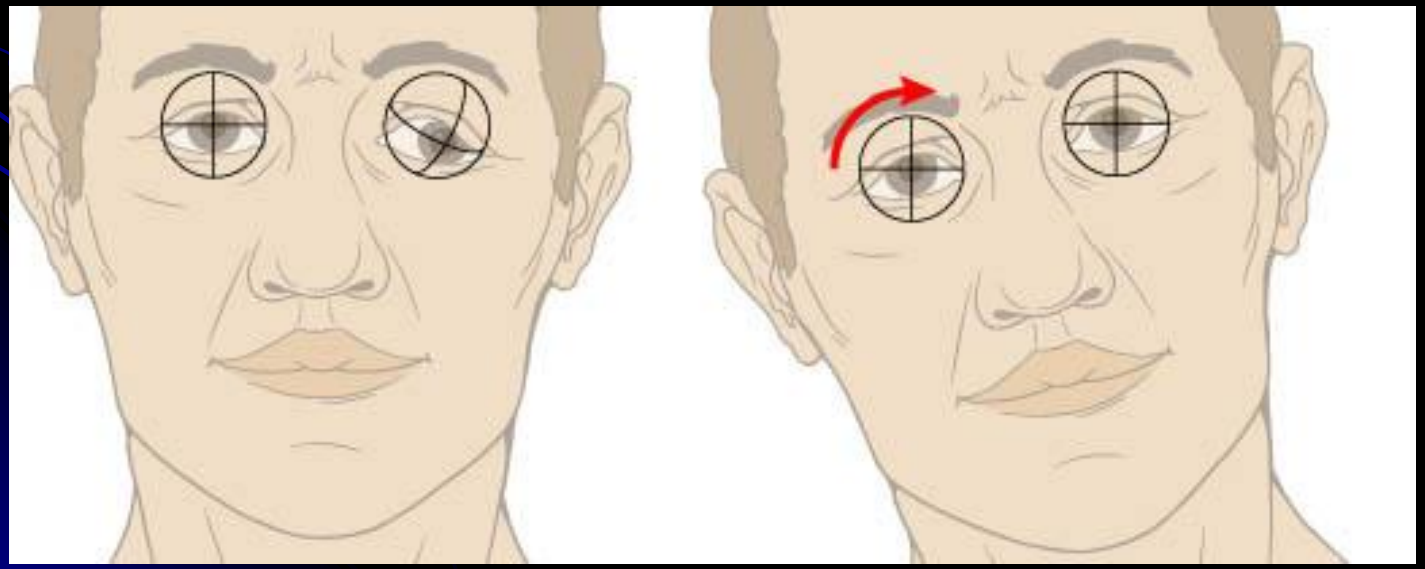

Cranial Nerve VI - Abducens Nerve

- Has only a somatic motor (general somatic efferent) component.

  Somatic motor: innervates the lateral rectus muscle of the ipsilateral orbit.

  The lateral rectus muscle is one of the six extraocular muscles responsible for the precise movement of the eye for visual tracking or fixation on an object.

- The abducens nerve innervates the lateral rectus muscle of the ipsilateral orbit.

  The lateral rectus muscle is responsible for lateral gaze (its contraction causes the eye to be abducted):

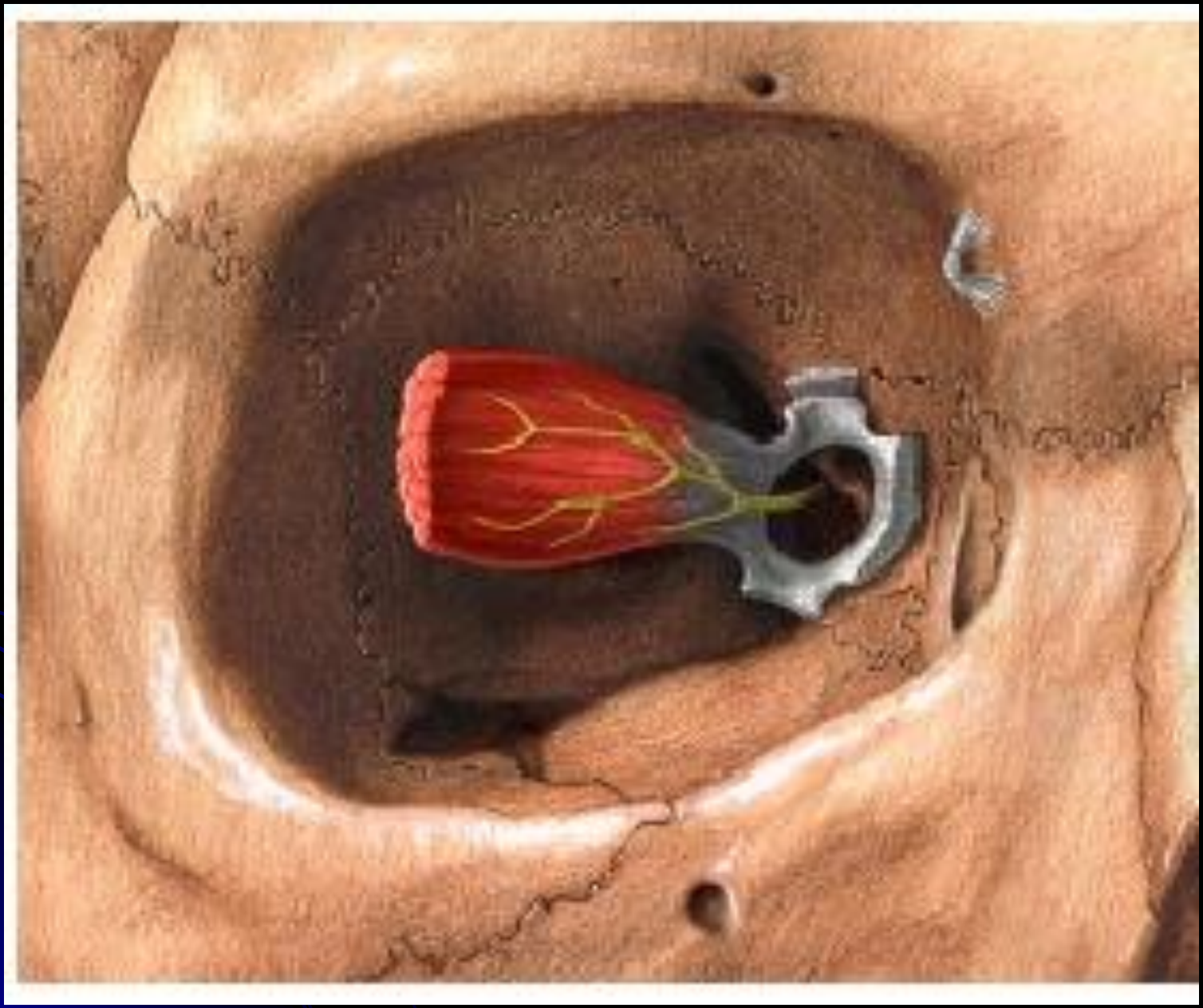

Actions of the lateral rectus muscle.

Origin and central course

- The fibers of the abducens nerve originate from the abducens nucleus located in the caudal pons at the level of the facial colliculus.

  Fibers leaving the abducens nucleus travel ventrally to exit the brainstem at the border of the pons and medullary pyramids.

Intracranial course

- Upon exiting the brainstem the abducens nerve climbs superiorly along the ventral surface of the pons. On reaching the apex of the petrous portion of the temporal bone the nerve makes a sharp turn anteriorly to enter the cavernous sinus.

- The abducens nerve travels along the lateral wall of the cavernous sinus with CNS III, IV, and V.

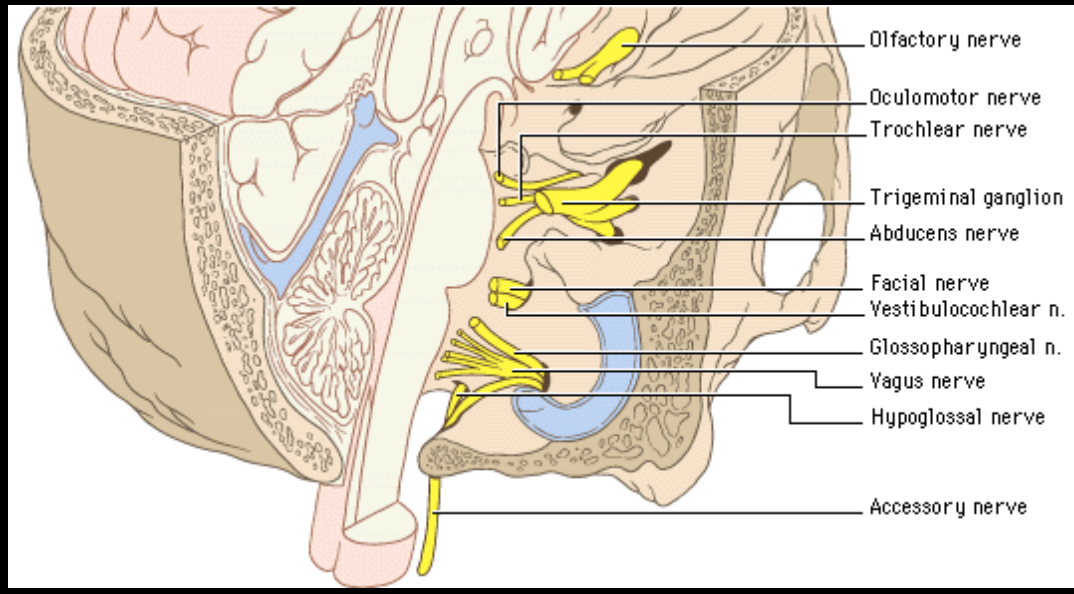

Intracranial course and final innervation

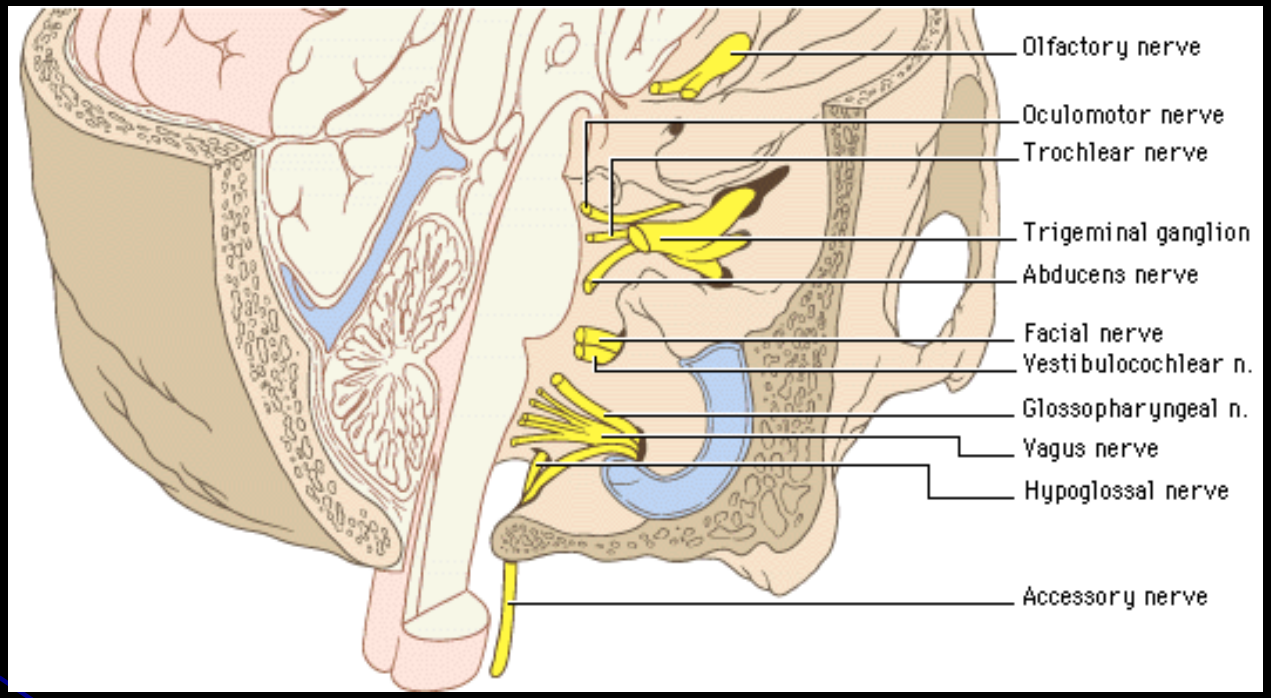

- From the cavernous sinus the abducens nerve enters the orbit through the superior orbital fissure.

  CN VI passes through the tendinous ring of the extraocular muscles and innervates the lateral rectus muscle on its deep surface:
- ***Clinical correlation - lower motor neuron (LMN) lesion***

  Damage to the abducens nucleus or its axons results in weakness or paralysis of the ipsilateral lateral rectus muscle.